

## End cap missing the proximal end of the tibial interlocking nail to migrate posteriorly into the medullary canal: A complication that may be avoided

Ashok Goel<sup>1</sup>, Mridul Maheshwari<sup>2</sup>, Mohammed Saif Niyazi<sup>3\*</sup>, Alok Gupta<sup>4</sup>

<sup>1,4</sup>Consultant, <sup>2,3</sup>Senior Resident, <sup>3,4</sup>Dept. of Orthopaedics, <sup>1</sup>Ysbyty Gwynedd Hospital, Bangor, United Kingdom, <sup>2,3</sup>Dr. RML Hospital, New Delhi, India, <sup>4</sup>Bhagwan Mahavir Hospital, Delhi, India

**\*Corresponding Author: Mohammed Saif Niyazi**

Email: [niyazi.saif@gmail.com](mailto:niyazi.saif@gmail.com)

### Abstract

An End cap for an Intra- medullary nail is normally used to prevent bone overgrowth into the proximal end of the nail and to facilitate nail removal at a later date. End cap migration into the proximal redundant space in the medullary canal behind the nail is rare but an avoidable complication. Maintenance of a fixed position of knee flexion during reaming and nail insertion and the use of Cannulated End Cap systems with Image control and may reduce the incidence of this complication.

For the retrieval of the end cap from the canal a haemostatic forceps may be used.

**Keywords:** Tibial interlocking, End cap, Migration.

### Introduction

The diaphyseal tibial fracture has an annual incidence of 1 in 2000, making it the most common long bone fracture.<sup>1,2</sup> These fractures are common in young males<sup>3</sup>. Nailing for diaphyseal tibial fractures is a commonly performed surgery.<sup>4,5</sup> Interlocking nail provides rotational control and maintains alignment and length of the bone. Moreover it has the advantages of a load sharing device, which permits early weight bearing and facilitates early union by providing micromotion at the fracture site.<sup>5,6</sup> Closed intra-medullary nailing preserves the fracture hematoma and surrounding soft tissue.

However intramedullary nailing is not without peri-operative medical and surgical complications.<sup>7</sup> These include:

1. Struggle to negotiate the guide wire.
2. Reamer getting jammed in the canal
3. Systemic complications like Hypotension and fat embolism.
4. Thermal necrosis of bone and soft tissues
5. Nail being stuck in the canal during insertion.
6. Iatrogenic fractures
7. Neurovascular compromise
8. Compartment Syndrome

An end cap is normally used to cap the proximal end of the nail at the end of the procedure. This is done to prevent bone re-growth into the proximal end of the nail, to facilitate easy nail removal at a later date. Apart from this, different length end caps may be used to add length to the nail. Newer cannulated systems have made end cap insertion a lot easier.

Various complications of end cap insertion have also been reported like incomplete insertion of End cap due to impingement with the proximal locking screw, bending of the proximal screw due to forced insertion.<sup>8</sup>

We hereby present a case report of an intraoperative complication at the far end of the procedure while

performing Interlocking nailing for a case of diaphyseal tibial fracture non union.

### Clinical Case

A 36 year old male sustained right tibial shaft fracture 6 months back and according to previous history and records, the fracture was reduced and attempted to be managed conservatively in cast. But over a span of 6 months it had not united and it was then that the patient came to our centre. It was planned for open reduction and internal fixation with tibial interlocking nail and autologous bone grafting after ruling out all the possibilities of infected non union. The nailing was done in a usual fashion followed by interlocking screw insertion. At the last step while inserting the end cap over a guide wire, the nail head was felt and the end cap insertion was confirmed on the anteroposterior radiographic view. Despite having observed these precautions, unfortunately it was realized that on the lateral radiograph the end cap had missed the nail head to lie about 5 cm deep in the medullary canal posterior to the nail. The cap was eventually retrieved with a haemostatic forceps.

### Discussion

As a standard, during tibial interlocking nailing procedure, the canal is normally over reamed by 1 to 2 mm to facilitate the insertion of the nail and achieve better union rates.<sup>9</sup> In the case being reported, the canal had been reamed up to size 11mm and a 10 mm diameter tibial interlocking nail had been inserted.

Thus theoretically, in spite of the practice of over reaming, there should exist only a minimal amount of space around the nail because of the relative tight fit nail of the nail into the canal.

The various reasons for there being intra-osseous redundant space proximally behind the nail could be:

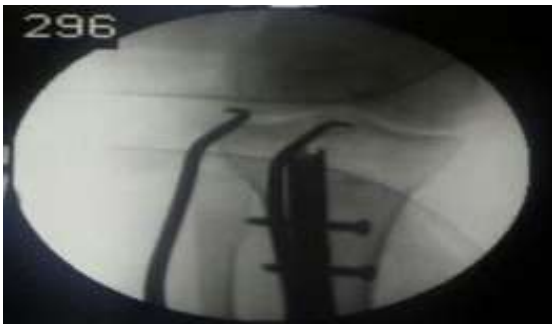1. Non uniform diameter of the tibial medullary canal at various levels.

2. The cancellous bone of the metaphysis being squashed or deformed during the process of reaming and nail insertion.
3. Varying position of knee flexion during the process of reaming and nail insertion leading to the formation of an oval entry point in the antero-posterior plane.
4. Localized disuse osteoporosis in long standing cases like non-unions.

In the above mentioned case; the Nail, Guide wire and the End cap were all well aligned on the antero-posterior view but on insertion, the end cap missed the nail to sink in the medullary canal posterior to the nail (Fig. 1).

For the retrieval of the end cap from the canal a haemostatic forceps was used. (Fig. 2).

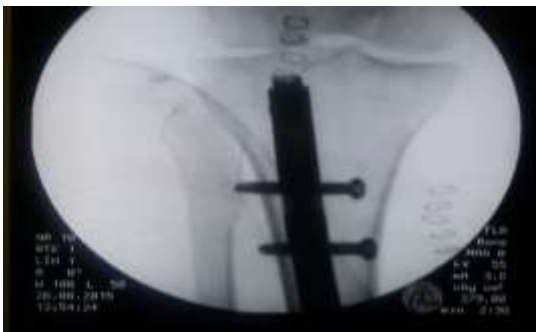
A “fish hook technique” using a bent k-wire, may also be used for misplaced end cap extraction.<sup>10</sup>



**Fig. 1: Anteroposterior view showing the end cap having missed the nail head**



**Fig. 2: Use of a curved hemostatic forceps inserted through the nail entry point for the retrieval of End cap from the posterior medullary canal**



**Fig. 3: The final view after proper placement of the end cap at the completion of the procedure**

## Conclusion

End cap sinking posteriorly into the proximal intra-osseous redundant space behind the nail is a potential complication, which may be avoided by using a fixed position of knee flexion during reaming and nail insertion. Though cannulated end cap systems self-facilitate insertion, it would still be prudent that the position of the guide wire be confirmed on both the antero-posterior and the lateral radiographs of the proximal tibia before end cap insertion.

**Conflict of Interest:** None.

## References

1. Court-Brown CM, Rimmer S, Prakash U, McQueen MM. The epidemiology of open long bone fractures. *Inj* 1998;29:529–534.
2. Bengner U, Ekblom T, Johnell O, Nilsson BE. Incidence of femoral and tibial shaft fractures. Epidemiology 1950–1983 in Malmo, Sweden. *Acta Orthop Scand* 1990;61:251–254.
3. Al-Hadithy N, Panagiotidou A. The management of open tibial shaft fractures. *Br Med J* 2012;345:e6348
4. Bong MR, Koval KJ, Egol KA. The history of intramedullary nailing. *Bull NYU Hosp Jt Dis* 2006;64(3-4):94-97.
5. Hooper GJ, Keddell RG, Penny ID. Conservative management or closed nailing for tibial shaft fractures. A randomised prospective trial. *J Bone Joint Surg Br* 1991;73(1):83-85.
6. Rokkanen P, Slätis P, Vanka E. Closed or open intramedullary nailing of femoral shaft fractures? A comparison with conservatively treated cases. *J Bone Joint Surg Br* 1969;51(2):313-323.
7. Koval KJ, Clapper MF, Brumback RJ. Complications of reamed intramedullary nailing of the tibia. *J Orthop Trauma* 1991;5(2):184-189.
8. P. Ralte, S. Robinson. Complications associated with the Meta-Nail Tibial Nail End Cap. *Inj Ext* 2013;44(10-12):83-86
9. Wu CC. Exchange nailing for aseptic nonunion of femoral shaft: a retrospective cohort study for effect of reaming size. *J Trauma* 2007;63(4):859-865.
10. Yun SH, Yang JH. Extraction of Misplaced Endcap during Tibia Intramedullary Nailing by 'Fish-Hook' Technique: Technical Note *J Korean Fract Soc* 2015;28(3):194-197.

**How to cite this article:** Goel A, Maheshwari M, Niyazi MS, Gupta A. End cap missing the proximal end of the tibial interlocking nail to migrate posteriorly into the medullary canal: A complication that may be avoided. *Indian J Orthop Surg* 2019;5(1):99-100.