

Utilizing autologous growth factors enriched bone graft matrix (sticky bone) and Platelet rich fibrin (PRF) membrane to enable dental implant placement: A case report

Romesh Soni^{1,*}, Aditi Priya², Himanshi Yadav³, Vikram Kumar⁴

¹Professor, ²⁻⁴Post Graduate Student, ¹⁻⁴Dept. of Prosthodontics, ¹⁻⁴Institute of Medical Sciences, Banaras Hindu University, Varanasi, Uttar Pradesh, India

***Corresponding Author: Romesh Soni**

Email: bhuprosthodonty2019@gmail.com

Abstract

Introduction: Dental implants are the most innovative and superior treatment in dentistry, and are widely used. However, the intended implant site may be inappropriate due to the poor bone quality or insufficient bone volume. When extensive loss of alveolar bone is encountered it presents a complex challenge for reconstruction. Numerous augmentation techniques are used for alveolar reconstruction and to create sufficient bone volume for placement of endosseous implants. In order to accelerate healing of bone graft over the bony defect, numerous techniques utilizing platelet and fibrinogen concentrations have been introduced in the literature. Sticky bone provides stabilization of bone graft in the defect, and therefore, accelerates tissue healing and minimizes bone loss during healing period. Due to formation of homogenous mass of bone graft particles, handling and adaptation of bone graft becomes easy. The use of sticky bone also avoids complex ridge augmentation procedures.

Aim: The aim of this case report is to demonstrate the use of sticky bone and autologous PRF membrane in hard tissue regeneration and maintenance of volume of alveolar ridge to enable dental implant placement.

Material and Methods: Ridge augmentation was done in defect using sticky bone formed by cera bone granules of particle size 0.5-1.0 mm and PRF membranes.

Results: Sufficient bone volume was achieved through GBR as shown by comparing presurgical and post 3 months CT and clinically it can be seen at second stage surgery done after 3 months.

Conclusion: The result suggested that GBR with autologous PRF membranes is sufficient for augmentation of localized alveolar ridge defects with conjunction with sticky bone. Sticky bone provides stabilization of bone graft in defect and improves handling properties and PRF membranes act as barrier membrane as well as source of accelerated growth factor release.

Keywords: Dental implant, Sticky bone, and Platelet rich fibrin (PRF) membrane.

Introduction

Dental implants are the most innovative and superior treatment in dentistry, and are widely used. However, in different clinical situation, the intended implant site is inappropriate due to the poor bone quality or insufficient volume of bone. In order to overcome such difficulties, autogenous bone grafts procured from patient have been used earlier for alveolar reconstruction, specifically owing to their osteoconductive, osteoinductive, and lack of immunogenic properties. However, the adverse events and complications, such as infection, pain, sensory loss, and hematoma formation at the donor site, occur frequently upon autogenous bone graft treatment. In addition, a donor site with a sufficient quantity of bone is not always available. In order to meet demands of ideal substitutes, dental research has focused on the use of bioactive molecules to induce local bone formation. Various researches has been carried out over the past few decades, dictating the role of utilizing growth factors for bone regeneration.¹⁻¹⁰

Over past few decades platelet concentrates have been utilized for various medical and dental procedures due to its autogenous source and better handling and tissue regenerative capacities.^{3,8,10-12} In the field of dentistry it is used as a regenerative tool in induction of tissue regeneration in various surgical procedures by releasing an array growth factors responsible for hard and soft healing and regeneration.^{8,10-12} However, healing of the tissues is

always difficult to control but the development of new techniques and materials has made it hastens the tissue healing. The use of platelet concentrates is an interesting and efficient approach. Several techniques for platelet concentrates are used till now for control of hemorrhage and acceleration of tissue regeneration. I-PRF is an autologous blood product obtained in liquid state and is highly concentrated in platelets and fibrin. I-PRF mixed with particulate bone grafts together forms sticky bone. This sticky bone doesn't get separated, has its own body and can be shaped according to the need due to strongly interlinked fibrin network. Due to this property of the sticky bone the bone loss is minimized on the defect areas during healing period. Sticky bone together with PRF membranes improves the healing and regeneration. This PRF membrane contains autologous growth factors and it slowly releases growth factors to the surrounding environment during healing and repair process.¹⁰⁻¹⁵

The aim of this case report is to demonstrate the use of sticky bone along with PRF membranes to enable dental implant placement in defect area.

Case Report

Case Presentation

A 22 year old female in good general health, non smoker and with adequate oral hygiene was referred to Out Patient Department of Prosthodontics and Crown and Bridge, Faculty of Dental Sciences, BHU for rehabilitation

of lost teeth.^{12,13} Patient had history of extraction of right impacted canine two months back. Initial radiographic evaluation by orthopantomograph (OPG) revealed a large defect area on the site of previously impacted canine and also the presence of impacted canines in both jaw, one in maxilla and two in mandible.

Case Management

The axial sections of dental scan showed defect area (Fig. 1). Measurements were done for available bone height to decide implant sizes. Sticky bone technique with PRF membranes was planned along with implant placement with ridge split approach. No systemic abnormalities were found in routine laboratory investigations. After diagnostic workout, informed consent has been taken prior to the surgical procedure and initial periodontal therapy was done.

Surgical area was scrubbed by betadine scrub and patient was draped. The surgical site was anesthetized by infraorbital and nasopalatine nerve blocks with local infiltration of 2% lignocaine with 1:80,000 adrenaline. After adequate anesthesia was achieved, crestal incision along with releasing incision from 14 to 11 was given and full thickness mucoperiosteal flap was raised. A through and through defect was seen after flap reflection and implant of size 3x13 (single piece, ADIN; Touareg closefit™ NP) wrt 12 and 3.5 x13 (double piece, ADIN; Touareg™-S) wrt 13 were placed by using ridge split procedure (Fig. 2). Implants threads were exposed in the defect area which was planned to cover by application of sticky bone and PRF membrane. In between the surgical procedure chairside procedure for fabrication of A-PRF and I-PRF was being carried out.

2 silica coated red cap tube of 10 ml without anticoagulant was used for PRF membrane formation and 2 yellow cap tube of 10 ml was used for obtaining I-PRF. Patient's blood was withdrawn directly into tubes by vacutainers and tubes were transferred to centrifugation machine (DUO^R Quattro Centrifuge) for obtaining I-PRF and A-PRF one by one. For obtaining I-PRF, centrifugation was done at 700 revolution per minute (rpm) for 3 minutes, the yellow upper part was obtained by syringe and mixed with particulate bone graft, particle size 0.5-1.0 mm) to form a stable fibrin bone graft (Sticky bone) for improved handling to improve graft stability.¹⁶ For obtaining A-PRF centrifugation was done at 1300 rpm for 8 minutes. Three layers appeared into the tube: a red blood cell base at the bottom, acellular plasma as a supernatant (platelet-poor plasma), and the PRF clot in between these two.¹⁰⁻¹⁵ The clot was retrieved from the tubes, placed in PRF box and transformed into a membrane.

Sticky bone and PRF membranes were placed in the defect area and interrupted sutures were performed by 3-0 silk suture. Post-operative instructions were given and the patient was prescribed antibiotics, analgesics, anti-inflammatory and chlorhexidine mouth rinses for 5 days. Patient was recalled after 7 days for evaluation and suture removal.

After 3 months of healing a good vestibular volume was seen. CT scan was done to evaluate bone formation after 3 months (Fig. 3). Then second stage surgery was done and healing cap was screwed to implant with respect to 13. A good bone formation was seen at second stage surgery in the previous defect area (Fig. 4). After second stage surgery when healing was obtained, abutments were prepared and final prosthesis (porcelain fused metal crown) was delivered (Fig. 5) and post operative OPG was done.

Case Outcome

This procedure allowed better correction of defect area, maintenance of adequate horizontal ridge defect and esthetic improvement (Fig. 6).

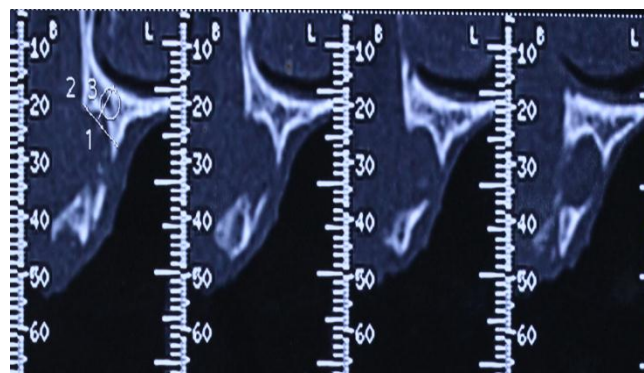


Fig. 1: CT scan showing defect in axial sections

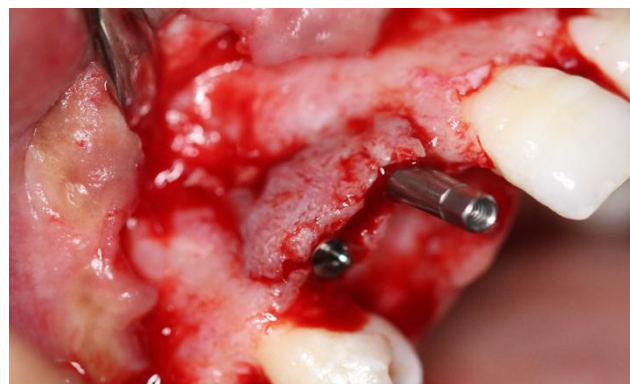


Fig. 2: Photograph showing implant placement after ridge split

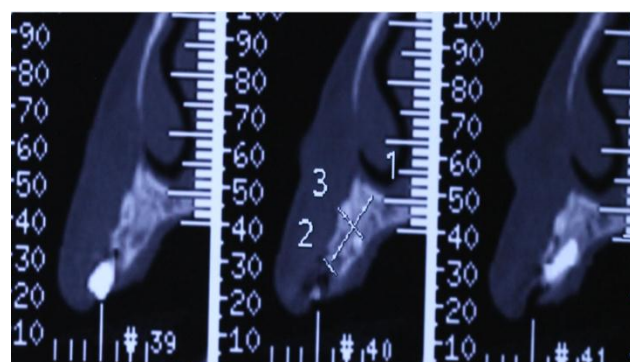


Fig. 3: CT sections after 3 months post-operative

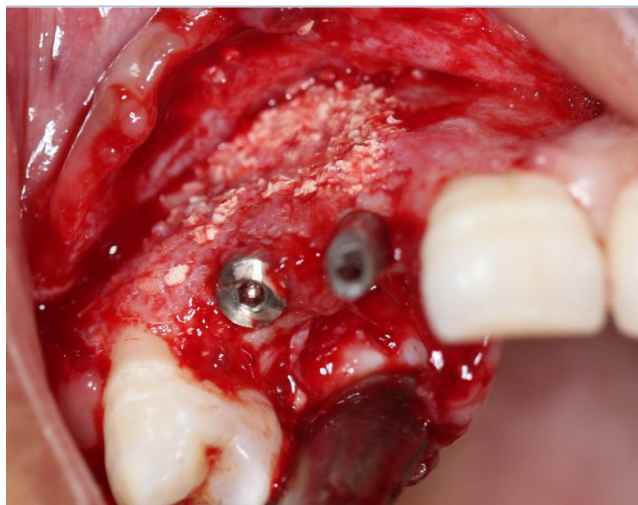


Fig. 4: Photograph showing bone formation at second stage surgery after 3 months

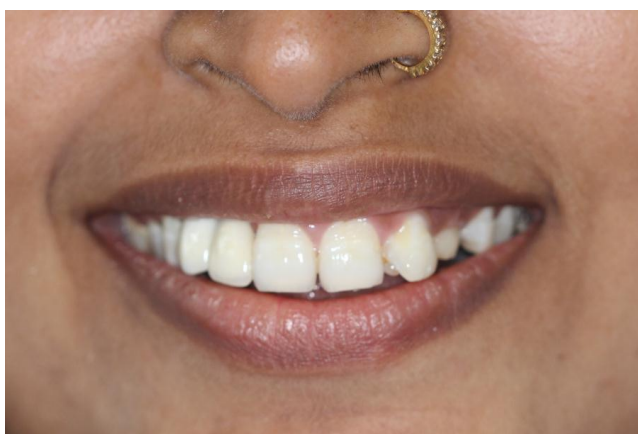

Fig. 5: Smiling photograph after prosthetic rehabilitation

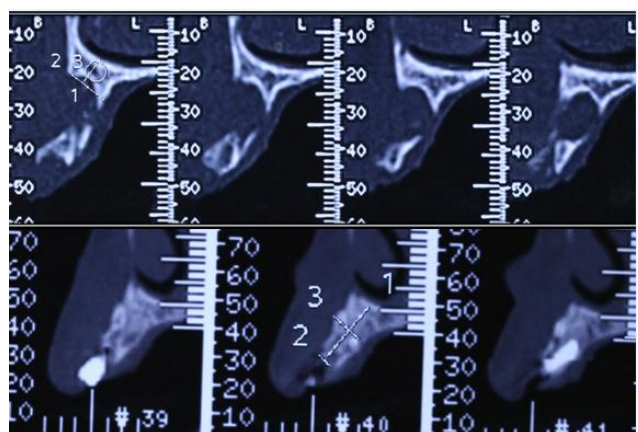


Fig. 6: Pre and Post CT comparing the bone formation

Discussion

Thin and deficient alveolar ridge and existing bone defect is limitation in the field of implant dentistry. Structural loss of alveolar ridge can occur as a result of congenital defects or acquired defects due to periodontal

diseases, tooth extraction or surgical procedures. Sufficient bone volume, width and length of alveolar ridge is an prerequisite for long term success of implants. But many a times the criterion is not met so regeneration process is necessary to obtain adequate hard tissue structure. One of the methods is to apply sticky bone and autologous PRF membranes in the defect area with simultaneous placement of implants. Other treatment modalities such as autologous bone graft harvested from other than primary site cause adverse events and complications, such as infection, pain, sensory loss, and hematoma formation at the donor site as well as extra waiting period is required. This case report aims at simultaneous placement of implants and sticky bone and PRF membranes avoiding secondary surgical site and reducing overall healing and treatment time. Treatment procedures with accelerated healing and functional recovery with reduced morbidity is treatment of choice for everyone. Introduction of platelet-rich therapies and development of newer generations of platelet concentrates have revolutionized the field of tissue regeneration due to growth factor repair capacities and proteins secreted by platelets.¹⁰⁻¹⁵ Their easy preparation protocols, versatility and biosafety (autologous preparation), cost effectiveness, enhanced repair and regenerative capacities, and prolonged holding and sustained release of growth factors and proteins has made them material of choice in large number of cases. PRF membranes act as barrier membrane having additional above mentioned advantages.⁹⁻¹² The use of platelet concentrates as an adjunct to surgical procedures and its efficacy in regenerative procedures is still controversial but large number of studies shows that platelet concentrates especially PRF has an positive effect in bone regeneration in intrabony defects.

Conclusion

Sticky bone and PRF membranes used in the present case resulted in successful Guided bone regeneration (GBR) and thus augmenting the alveolar ridge defect. With increasing esthetic functional demands and expectations of patients, GBR with autologous PRF membrane has become a common technique for implant placement and survival and is a promising option for implant supported prosthetic rehabilitation in the esthetic zone.

Acknowledgements

No funding was received for this case report.

Conflict of Interest: None.

References

1. Anitua E, Sanchez M, Nurden AT, Nurden P, Orive G, Andia I. New insights into and novel applications for platelet-rich fibrin therapies. *Trends Biotechnol* 2006;24:227–234. doi:10.1016/j.tibtech.2006.02.010
2. Kammerer P W, Scholz M, Baudisch M, Liese J, Wegner K, Frerich B et al. Guided bone regeneration using collagen scaffolds, growth factors, and periodontal ligament stem cells for treatment of peri-implant bone defects *In-vivo*. *Stem cell international* 2017;2017.https://doi.org/10.1155/2017/3548435

3. Liddo R D , Bertalot T, Borean A , Pirola I, Argentoni A, Schrenk S et al. Leucocyte and platelet-rich fibrin: a carrier of autologous multipotent cells for regenerative medicine. *J cell Mol Med* 2018. Doi:10.1111/jcmm.13468
4. Aoki N, Kanayama T, Maeda M. "Sinus Augmentation by Platelet-Rich Fibrin Alone: A Report of Two Cases with Histological examination,". *Case Rep Dent* 2016;2016:Article ID 2654645. Doi:10.1155/2016/2654645
5. Peck Thabit M, Marnewick J, Stephen L. "Alveolar Ridge Preservation Using Leukocyte and Platelet Rich Fibrin: A Report of a case,". *Case Rep Dent* 2011;2011:Article ID 345048. Doi:10.1155/2011/345048.
6. Toffler M. Guided Bone Regeneration (GBR) Using Cortical Bone Pins in Combination with Leukocyte – and Platelet–Rich Fibrin (L-PRF). *COMPENDIUM*. 2014;35:192-198.
7. Zang J, QI X, Luo X , LI D, Wang H , LI T. Clinical and immunohistochemical performance of lyophilized platelet-rich fibrin (Ly-PRF) on tissue regeneration. *Clin Implant Dent Relat Res* 2017;19:466-477.
8. Lourenco E S, Mourao C F A B, Leite P E C, Granjeiro J M, Calasans-Maia M D, Alves G G. The in-vitro release of cytokines and growth factors from fibrin membranes produced through Horizontal centrifugation. *J Biomed Mater Res* Accepted author manuscript. Doi:10.1002/jbm.a.36346
9. Kawase T, Kamiya M, Kobayashi M, Tanaka T, Okuda K, Wolff L F et al. The heat compression technique for the conversion of platelet-rich fibrin preparation to a barrier membrane with a reduced rate of biodegradation. *J Biomed Mater Res Part B* 2014;2014. Doi:10.1002/jbm.b.33262
10. Dohan Ehrenfest DM, Corso MD, Kang BS, Lanata N, Quirynen M, Wang HL et al. The impact of the centrifuge characteristics and centrifugation protocols on the cells, growth factors and fibrin architecture of a Leukocyte- and Platelet-Rich Fibrin (L-PRF) clot and membrane. Part 3: comparison of the growth factors content and slow release between the original L-PRF and the modified A-PRF (Advanced Platelet-Rich Fibrin) membranes. *POSEIDO*. 2014;2:155-166.
11. Toffler M, Toscano N, Holtzclaw D, Corso MD, Ehrenfest DD. Introducing Choukroun's Platelet Rich Fibrin (PRF) to the Reconstructive Surgery Milieu. *JIACD* 2009;1:21-31.
12. Fujioka –Kobayashi, M, Miron RJ, Hernandez M, Kandalam U, Zhang Y, Choukroun J. Optimized Platelet-Rich Fibrin With the Low-Speed Concept: Growth Factor Release, Biocompatibility, and Cellular Response. *J Periodontol* 2017;88:112-121. doi:10.1902/jop.2016.160443
13. Dohan DM, Choukroun J, Diss A, Dohan SL, Dohan JJA, Mouhyi J et al. Platelet-rich fibrin (PRF): A second-generation platelet concentrate. Part III: Leucocyte activation: A new feature for platelet concentrates? *Oral Surg Oral Med Oral Pathol Oral Radiol Endod* 2006;101:E51-55. doi:10.1016/j.tripleo.2005.07.010
14. Dohan DM, Choukroun J, Diss A, Dohan SL, Dohan JJA, Mouhyi J, et al. Platelet-rich fibrin (PRF): A second-generation platelet concentrate. Part IV: Clinical effects on tissue healing. *Oral Surg Oral Med Oral Pathol Oral Radiol Endod* 2006;101:E56-60. doi:10.1016/j.tripleo.2005.07.011
15. Dohan DM, Choukroun J, Diss A, Dohan SL, Dohan JJA, Mouhyi J, et al. Platelet-rich fibrin (PRF): A second-generation platelet concentrate. Part V: Histologic evaluations of PRF effects on bone allograft maturation in sinus lift. *Oral Surg Oral Med Oral Pathol Oral Radiol Endod* 2006;101:299-303. doi:10.1016/j.tripleo.2005.07.012
16. Sohn DS, Huang B, Kim J, Park WE, Park CC. Utilization of Autologous Concentrated Growth Factors (CGF) Enriched Bone Graft Matrix (Sticky Bone) and CGF-Enriched Fibrin Membrane in Implant Dentistry. *J Implant Adv Clin Dent* 2015;10:11-29.

How to cite this article: Soni R, Priya A, Yadav H, Kumar V, Utilizing autologous growth factors enriched bone graft matrix (sticky bone) and Platelet rich fibrin (PRF) membrane to enable dental implant placement: A case report. *Ann Prosthodont Restor Dent* 2019;5(1):16-19