

Anatomic post and core- A novel approach to restore flared root canals: A case report

Anvitha Shetty^{1,*}, Ramya Raghu², Ashish Shetty³, Gautham PM⁴

¹Post Graduate Student, ²Professor and HOD, ^{3,4}Professor, Dept. of Conservative Dentistry and Endodontics, Bangalore Institute of Dental Sciences & Hospital, Bengaluru, Karnataka, India

***Corresponding Author: Anvitha Shetty**

Email: anucshetty@gmail.com

Abstract

Treating a flared root canal always poses a challenge to the clinician. If treated inappropriately, the root is prone to fracture thereby leading to catastrophic failure of the tooth. Reinforcing the canal with the help of anatomic post provides optimal stability and strength to the tooth. This case report focuses on the clinical technique of fabricating an anatomic post and reviews the various options to treat a flared canal.

Keywords: Flared canals, Anatomic post, Pre-fabricated post, Composite resin, Resin luting cement.

Introduction

The restoration of endodontically treated teeth continues to be a challenge to clinicians particularly when there is moderate to extensive tooth loss. In such cases, the final restoration can be well retained only by means of a post and core system.¹

Rehabilitation of weakened roots with thin residual dentinal walls is fraught with a number of problems and often results in a poor long term prognosis. Wide/flared root canals could be due to carious involvement of the pulp chamber, internal resorption, excessive preparation of the root canal or as a result of incomplete physiologic root development.²

The traditional cast post and core systems were considered the gold standard in such situations. They intimately adapt to the canal morphology, offer a good fit and provide high retention. However, various studies have reported that their rigidity and high elastic modulus eventually leads to root fracture.³ A wide and rigid post in a fragile root is a sure recipe for failure in such cases.

Presently the use of pre-fabricated glass fiber posts is increasing in restorative dentistry as they are more esthetic, biocompatible and may be adhesively bonded to the composite core. Since the modulus of elasticity of glass fiber post is closely matched to that of dentin they flex with the tooth structure and provide favourable stress distribution thus reducing the occurrence of catastrophic fractures.

The use of a fiber post in a flared canal results in increased thickness of luting cement. This results in voids leading to a decrease in resistance and eventual debonding of the post. A recent innovation to restore flared root canals with fiber posts is the use of an "anatomic fiber post". Here, composite resin is adapted to the fiber post to mimic the flared anatomy of the root canal. The intimate adaptation to the canal coupled with bonding of the post to the root canal makes the anatomic post a boon for flared canals.³

The present case highlights the clinical steps in the fabrication of an anatomic post and core for successful restoration of an anterior tooth with flared canal.

Case Report

A 23 year old male patient reported to the Department of Conservative Dentistry and Endodontics with the chief complaint of broken and discoloured upper front teeth. The patient gave a history of previous root canal treatment for 11. Radiographic examination revealed inadequate obturation and the presence of a periapical lesion in relation to 11. The root canal also seemed to be excessively flared. After clinical and radiographic examination, a decision was made to re-treat the canal and fabricate an anatomic post as part of the post endodontic restoration. [Fig. 1]

After gaining access to the root canal, the old gutta percha was removed using a GP solvent (Endosolv, Septodont USA) and a size 40 Hedstrom file. The canal was irrigated with 3% sodium hypochlorite and correct working length was then re-established. Cleaning and shaping was done using hand files up to size 80 K file as the canal was flared following which obturation was done using the rolled cone technique. [Fig. 2]

At the subsequent visit, the post space was prepared using Peeso reamers (MANI, Japan). A size 4 glass fiber post was selected but it was poorly fitting in the canal. Hence the decision to fabricate an anatomic post was made. The canal was coated with a separating medium (Glycerine). The selected fiber post was first treated with silane (Ultradent, USA) for 1 minute. Following this, a nano hybrid composite resin (Tetric N Ceram, Ivoclar Vivadent USA) was adapted to the post which was then seated in the canal to reproduce the canal anatomy. This anatomic fiber post was first light cured inside the canal for 20 seconds followed by extra oral curing for an additional 20 seconds. [Fig. 3] Subsequently, the core build up was done using composite resin. [Fig. 4] Finally the fabricated post and core was checked for proper fit. Prior to cementation of the post, the canal was thoroughly rinsed with 5ml of 17% EDTA for 1 minute to remove impurities and to clear the smear layer. For cementation, the canal was first conditioned with 37% phosphoric acid gel (Total etch, Ivoclar Vivadent) for 15 seconds followed by rinsing and drying the canal. The two step etch and rinse adhesive system (Tetric-N-Bond, Ivoclar Vivadent) was coated into canal thoroughly and excess was removed using a paper point. This was then light cured for

20 seconds. The canal and the post surface were then coated with a dual cure resin luting cement (Rely-X U200, 3M ESPE) and the post was firmly seated into the canal. Excess cement was removed followed by light curing on all margins for 20 seconds each. [Fig. 5]

After cementation, the crown preparation was completed, an impression was recorded using addition silicone impression material (Aquasil, Dentsply USA) and an All Ceramic crown. (IPS E-Max System, Ivoclar Vivadent) was fabricated. [Fig. 6]

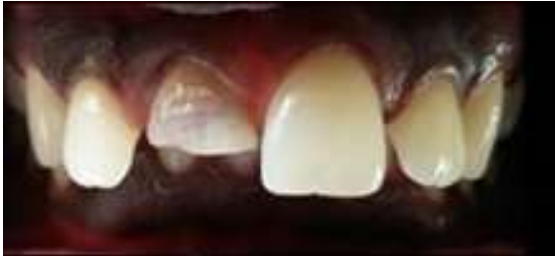

Fig. 1: Pre-operative image

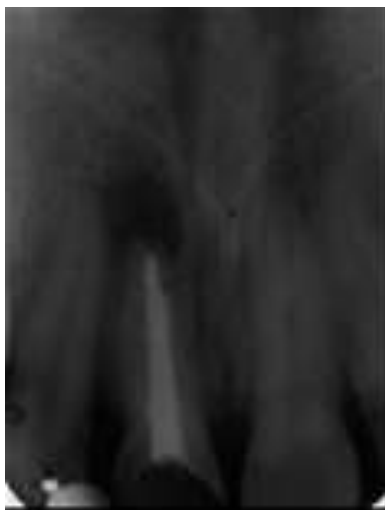

Fig. 2: Obturated radiograph

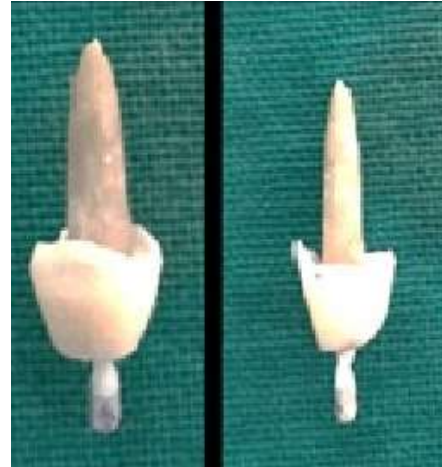


Fig. 4: Core build up

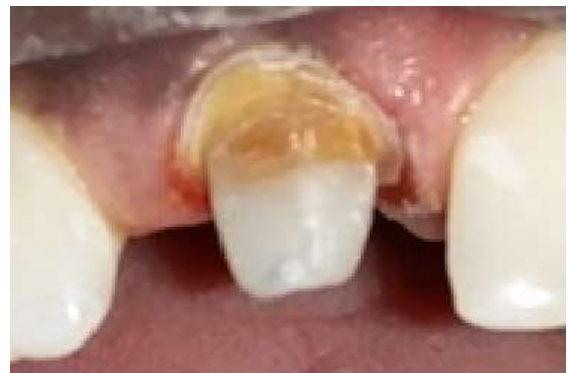

Fig. 5: Cemented post and core

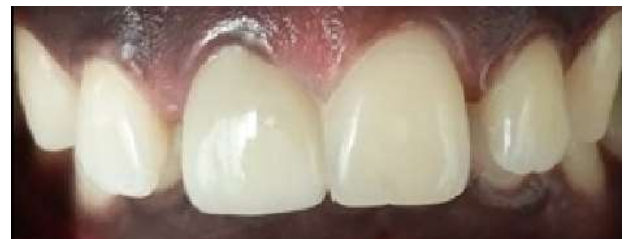

Fig. 6: Crown cemented

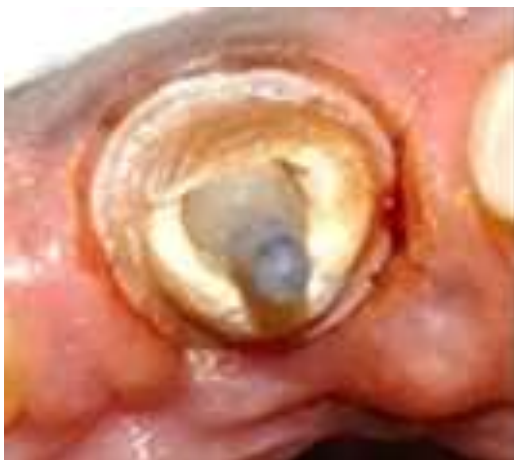

Fig. 3: Fit of anatomical post in the canal with crown preparation

Discussion

The decision to fabricate an anatomic post and core in the present case was based on the presence of a flared canal. For long, cast post and core was the primary choice in such situations. They provide intimate adaptation to the canal walls and require minimal canal preparation. However, the high rigidity of the cast metal post and core can generate a wedging effect resulting in extensive root fracture requiring tooth extraction.³

A new concept evolved in restorative dentistry with the introduction of fiber reinforced composite posts. Since they are compatible with adhesive resins, luting resin cement and composite resin, they form a mechanically homogenous structural complex and this was referred to as the 'Monoblock Concept'.³

With the introduction of fiber posts, Lui et al suggested the restoration of flared canals with composite resin to

reduce the canal width which could then be matched to that of a pre-fabricated fiber post. He introduced the concept of 'Intra-radicular rehabilitation of flared canals' using composite resin along with light transmitting plastic posts.⁴ The problems with this technique are that adequate curing of the composite resin at the deepest regions of the post space remains questionable.

To overcome this problem, the possibility of using accessory fiber posts was suggested by Clavijo et al. Though this seemed a practical technique, in the clinical scenario the thickness of the cement layer did not reduce as voids were still present between the accessory fiber post and the canal walls.² So this could significantly reduce the adhesiveness of the technique.

Boudrias et al in 2001 suggested customization of fiber posts to match the shape and contour of flared canals and called it the 'Anatomic post' concept. This was the technique followed in the current case report. Here, the fiber post is relined with composite resin to obtain the canal contour similar to the fabrication of a wax pattern. This technique is reported to have better physical and mechanical properties.⁵

The advantages of this technique includes customization of the post and core in a single visit, intimate adaptation to the canal shape, minimal thickness of the resin luting cement, decreased polymerization shrinkage, better bonding and chemical union with the resin cement. Here the composite resin can be secondarily cured (ie- both inside the canal as well as outside before the final cementation of the post). Anatomic posts are reported to bend less under oblique loading than other thinner posts by transferring the deformation stresses down the root.

Several in-vitro studies have shown good results for anatomic posts.^{1,4} The high hydraulic pressure that the post exerts on the cement against the dentin walls results in better contact between the cement/post entity and the dentin. This also reduces the voids in the cement thus minimizing chances for debonding of the post. Studies have also observed increase in the number of dentinal tubules filled with resin luting cement because of better penetration of resin into demineralized dentin leading to a more uniform hybrid layer with greater resin tags and adhesive lateral branches. All these findings indicate that the anatomic post has better adhesive capability.^{1,3}

A finite element analysis study on stress distribution of flared canals reported that the roots reinforced with only one pre-fabricated post or those with accessory posts all showed similar stress distribution. Also increasing the thickness of the resin luting cement still had higher total stress accumulation values at the root dentin when compared with anatomic post model. This study concluded that anatomic posts maintained the stress inside the post body and directed less stress to the remaining root structure.⁶

In the present case, we pre-treated the glass fiber post with silane coupling agent before modelling it with composite resin. This was done as researchers have

suggested that silanization of the fiber post enhanced the adhesion of composite resin.¹

There is a growing body of in-vitro and in-vivo studies that recommend standard 2 step etch and rinse adhesive systems in conjunction with dual cure or chemically cured resin cement.¹ These are definitely considered superior to self-etching or self-adhesive cement formulations.

For relining the post, nano-hybrid composite (Tetric-N-Ceram, Ivoclar Vivadent) was used. The advantages of using nano-hybrid composites are that they present superior mechanical and physical properties compared to micro-hybrid composites and also have higher colour stability.

Newer materials and methods are being used to fabricate the anatomic post. Recently the use of flowable bulk fill composite to reinforce the flared root canal along with a fiber post has been reported. The reported advantage is faster curing and placement of composites, speeding up the procedure. Further in-vitro and in-vivo studies are required to prove the stability and the efficiency of this technique in restoring the flared root canal.

Conclusion

Flared canals are challenging clinical situations in practice where the root canal walls are thin and are prone to fracture. Anatomical fiber posts have thus emerged as the definitive option for reinforcing flared canals. Having a precise custom shape and adhesive luting with resin cement provides optimal retention thereby making it a superior treatment option for management of such cases.

Conflict of Interest: None.

References

1. Cardenas A, Siqueira F, Davila-Sanchez A, Gomes G, Reis A, Gomes J. Four-year Follow-up of a Direct Anatomical Fiber Post and Esthetic Procedures: A Case Report. *Oper Dent* 2016;41(4):363-369.
2. Gomes G, Monte-Alto R, Santos G, Fai C, Loguercio A, Gomes O et al. Use of a Direct Anatomical Post in a Flared Root Canal: A Three-year Follow-up. *Oper Dent* 2016;41(1):E23-E28.
3. Amaral F, Jassé F, Calixto L, Silva Júnior J, Neto C, Andrade M et al. Direct anatomical posts for weakened roots: The state of knowledge. *Sci J Dent* 2015;2:13-20.
4. Braz R, Mergulhão V, Oliveira L, Alves M, Canto C. Flared Roots Reinforced With Bulk-fill Flowable Composite — Case Report. *Oper Dent* 2018;43(3):225-231.
5. Grandini S, Sapio S, Simonetti M. use of anatomic post and core for reconstructing an endodontically treated tooth: A case report. *J Adhesive Dent* 2003;5(3):243-247.
6. Belli S, Eraslan Ö, Eraslan O. Effect of Restoration Technique on Stress Distribution in Roots with Flared Canals: An FEA Study. *J Adhesive Dent* 2014;16(2):185-191.

How to cite this article: Shetty A, Raghu R, Shetty A, Gautham PM. Anatomic post and core- A novel approach to restore flared root canals: A case report. *Int J Oral Health Dent* 2019;5(1):41-43.