

## Dentigerous cyst of the jaws: A case series

Kavita Wadde<sup>1,\*</sup>, Nazmul Alam<sup>2</sup>, Ashwini Chapane<sup>3</sup>

<sup>1</sup>Associate Professor, <sup>2</sup>Assistant Professor, <sup>3</sup>Post Graduate Student, Dept. of Oral and Maxillofacial Surgery, Government Dental College and Hospital, Mumbai, Maharashtra, India

**\*Corresponding Author: Kavita Wadde**

Email: dr.kavitawadde@gmail.com

### Abstract

It is the second most common odontogenic cyst & constitutes around 20-24% of all the odontogenic cyst involving the jaw. Usually these cysts remain asymptomatic, rarely showing facial asymmetry & displacement of associated impacted mandibular and maxillary third molar. It's also associated with the supernumerary teeth. The highest incidence of dentigerous cyst occur during the second and third decade & sometimes it may diagnose in later age also.

The purpose of this paper is to present 4 cases of dentigerous cyst in adult associated with impacted third molar or supernumerary teeth, correlation of trauma to the teeth & its pathogenesis. The cyst was enucleated with removal of embedded teeth. It was confirmed by histopathological findings. The patient remains asymptomatic & no complications were noted.

**Keywords:** Cyst, Dentigerous cyst, Mandible, Maxilla, Enucleation, Impacted tooth.

### Introduction

Dentigerous cyst (DC) is usually associated with a crown of unerupted/impacted tooth or trauma to the tooth. Dentigerous cyst is caused by fluid accumulation between the reduced enamel epithelium and the enamel surface of a formed tooth and also known as follicular cyst.<sup>1</sup> According to the literature it most commonly affects the young people with the incidence ratio of 1.6:1. Radiographically dentigerous cyst usually appears as a unilocular, well-defined radiolucent area attached to the tooth at the cemento enamel junction. It has a tendency to displace and resorb the associated tooth. Sometimes the cyst may resemble odontogenic keratocyst (OKC) and unicystic ameloblastoma (UA). Computed tomography provides important information regarding differential diagnosis.<sup>2</sup>

The estimation of occurrence of dentigerous cyst is 1.44 per 100 unerupted teeth. The risk varies considerably. The frequency of occurrence of dentigerous cyst in association of mandibular impacted third molar is more than maxillary impacted third molar.<sup>3</sup>

This paper highlights a case series of dentigerous cyst, with association of the unerupted teeth & correlation of trauma to the teeth, standard treatment modality in adults.

### Case 1

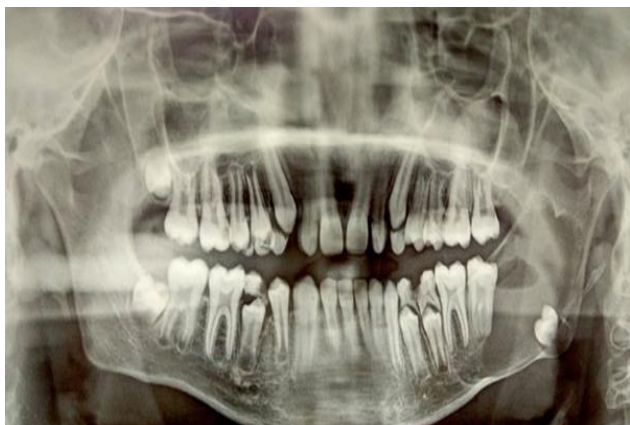A male patient of 14-year-old reported to our department with chief complaint of pain and swelling on the lower left side of the face, since 3 months. Extra-oral examination showed diffuse swelling in the left mandibular angle region (Fig. 1). The swelling was tender on palpation and firm in consistency. Overlying skin was normal and afebrile. Intra-oral examination showed a swelling extending from distal surface of first molar involving the second molar with obliteration of buccal and lingual sulcus.

OPG showed, a unilocular radiolucency from the first molar, involving second molar up to sigmoid notch on the left side of mandible. Lower left third molar was present at the lower border of mandible. Margins of the lesion

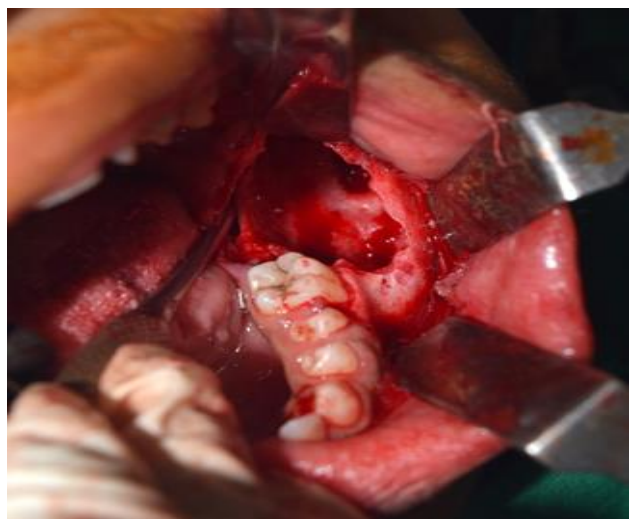
appeared to be scalloped, thinning of lower border of mandible was seen (Fig. 2). On aspiration it showed straw coloured fluid. Provisional diagnosis was dentigerous cyst with a differential diagnosis of OKC (odontogenic keratocyst), radicular cyst. Complete investigations were carried out. Histopathological findings of incisional biopsy was suggestive of dentigerous cyst, so the patient was planned for enucleation of cystic lesion under local anaesthesia. Patient was scrubbed & draped in routine manner. Left inferior alveolar nerve block & buccal infiltration was given with 2% lignocaine with adrenaline. Cervical incision was given buccal flap was reflected, the cystic lining & cystic content were exposed. Third molar was removed and entire cystic lining and cystic content was enucleated (Fig. 3). Interrupted suture was given. Follow up was done after 7 days, 15 days, 1 month up to 2 years no recurrence of cyst was evident.



**Fig. 1: Extra oral picture**



**Fig. 2:** OPG showed unilocular radiolucency from left second molar to left sigmoid notch with impacted left lower third molar

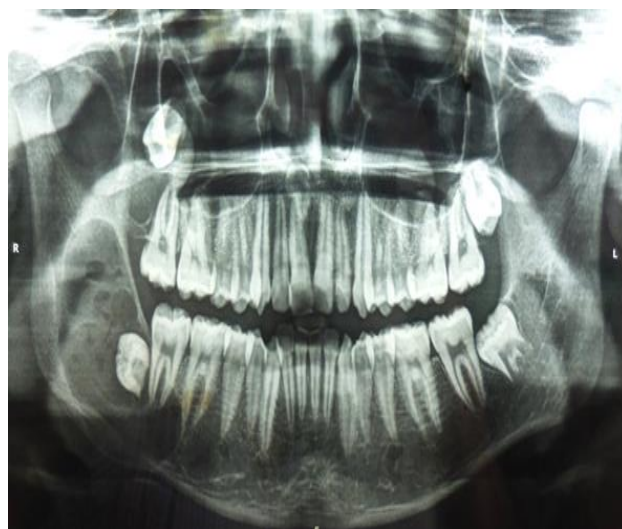

**Fig. 3:** Intraoperative photograph showed enucleation of cystic lesion with removal of lower left impacted third molar

### Case 2

A male patient of 17-year-old reported to our department with the chief complaint of swelling on the lower right side of the face. Extra orally swelling was, diffuse hard & non-tender. Intra-orally, the swelling was seen from distal to first molar involving the ramus of the mandible and obliterating the buccal sulcus. Expansion of buccal cortical plate in the ramus was seen and overlying mucosa was normal. OPG showed a large well defined, corticated unilocular radiolucency was seen on the right side of the body and ramus of the mandible. The lesion was well-defined and corticated. Internal area appears to be homogeneous and radiolucent. Radiopaque septa was seen. Erupting Crown portion of distally angulated mandibular right third molar was present in the lesion. Thinning of lower border of mandible was also present and inferior alveolar nerve canal appeared to be displaced inferiorly and both cortical margins were not traceable. (Fig. 4). Aspiration was done it showed straw coloured fluid. The routine

investigations were done, an incisional biopsy was taken & histopathological findings were suggestive of dentigerous cyst for which enucleation was considered as a treatment option, under local anaesthesia crevicular incision was given in right first molar extending posteriorly with the distal releasing incision towards the external oblique ridge, buccal flap reflected and the cystic lesion was exposed cystic lining removed. Lower right third molar which was embedded in cystic lining was removed, margins smoothed and suturing was done with 3-0 vicryl. Healing was uneventful.



**Fig. 4:** OPG revealed a large well defined, corticated, unilocular radiolucency in the right body and ramus region with impacted right mandibular third molar and radiolucent lesion in the right maxillary tuberosity with impacted maxillary right third molar

### Case 3

A male patient of 42-year-old reported to our hospital. His complaint was painless swelling in the upper left jaw since 1 year. He had history of trauma in the same region, 1 year ago with no history of any systemic illness. Then he noticed the diffuse swelling which was increasing gradually. Intra-oral examination showed a firm non-tender swelling obliterating the buccal sulcus in the left maxillary anterior region up to the midline. The overlying mucosa was normal.

The panoramic radiograph revealed a radiopaque structure in left maxillary sinus. Left side maxillary sinus appears to be radiopaque, extending from the left canine up to the mesial surface of upper right central incisor. Mesial wall of the sinus is not clearly appreciated, floor of the sinus was intact. Condyle and coronoid process appears to be normal.

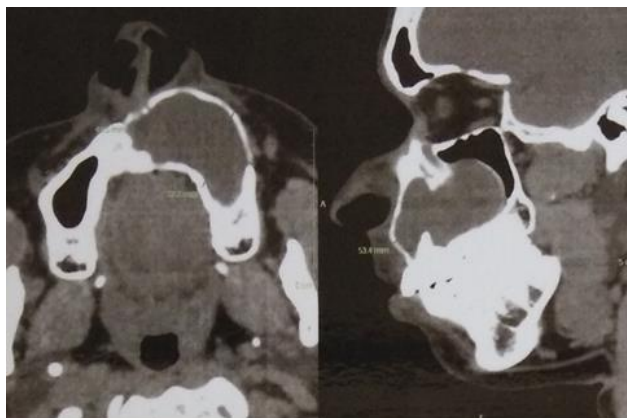
CT scan revealed, in sagittal and axial section shows a round corticated isodense lesion, extending from floor up to the roof of left maxillary sinus (Fig. 5).

Yellow colour fluid was obtained on aspiration suggestive of cystic lesion.

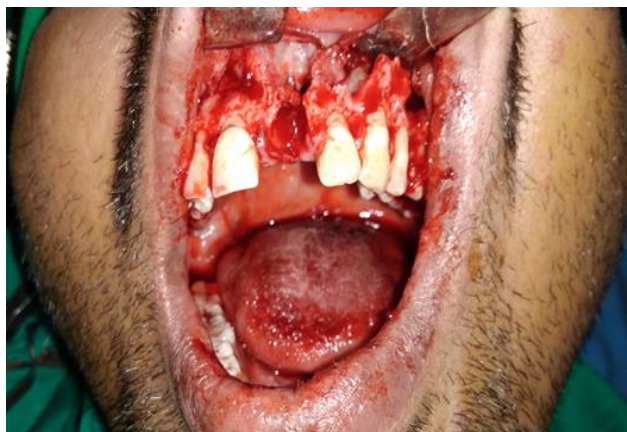
Investigations were carried out & incisional biopsy was taken. Histopathological findings were suggestive of dentigerous cyst. So, enucleation of cystic lesion was



planned under local anaesthesia. Patient was scrubbed and draped, 1:2,00,000 lignocaine with adrenaline was given and the crevicular incision was taken from lateral incisor to 1<sup>st</sup> molar on upper left side with the distal releasing incision. Buccal flap also reflected & cystic lesion was exposed. Cystic lining was removed and supernumerary tooth which was surrounded by cystic lining was removed (Fig. 6). Margins were smoothed, haemostasis was achieved, suturing was done with 3-0 vicryl. Healing was uneventful. Follow up was done for 2 years.



**Fig. 5:** CT scan revealed, in sagittal and axial section shows a round corticated isodense lesion in the left maxillary sinus extending from floor of the maxillary sinus up to the roof of maxillary sinus superiorly



**Fig. 6:** Surgical exposure of cystic lesion

#### Case 4

A male patient of 17-year-old reported to our hospital. He complained of swelling on the mid right side of the face. Extra-orally swelling was diffuse, hard, & non-tender, afebrile, skin over swelling was normal. Intra-orally a swelling in the right maxillary posterior region with obliteration of buccal vestibule was noted, overlying mucosa was normal. Panoramic radiograph revealed, a radiolucent lesion in right maxillary tuberosity area & had shifted upper right third molar in upward direction. It was suggestive of radicular cyst and dentigerous cyst. On aspiration a yellow coloured fluid was obtained & hence the

enucleation was considered as a treatment option under local anaesthesia. Crevicular incision was given from right first premolar to distal of right third molar with distal releasing incision. Entire cystic lining and cystic contents were removed, curettage of bone was done homeostasis achieved and suturing was done with 3-0 vicryl.

#### Discussion

A dentigerous cyst is of developmental origin associated with the crown of an unerupted tooth.

The incidence of cyst associated with the permanent tooth is 95% whereas in supernumerary tooth is 5%.<sup>2</sup>

The exact cause of cyst associated with supernumerary teeth is still unknown but it can be because of local independent or conditioned hyperactivity of dental lamina. Apart from this, some authors have suggested that periapical inflammation of nonvital deciduous teeth in proximity to the follicles of unerupted permanent successors may be a triggering factor of cyst formation.<sup>3</sup>

The pathogenesis is still controversial, the correlation between dentigerous cyst & trauma in the deciduous teeth and crown of successor teeth has been reported.<sup>4</sup> The impact force of trauma could have led to odontogenesis disturbances on the successor tooth.<sup>5</sup>

On radiograph, dentigerous cyst shows a well defined unilocular/multilocular radiolucency involving the crown of an unerupted tooth, so the differential diagnosis of such radiolucency include radicular cyst, odontogenic keratocyst, unicystic ameloblastoma, pinbong tumour, odontoma, & cementoma.

Surgery is commonly recommended for dentigerous cyst because of large size, displacement of teeth, destruction of cortical bone, sometimes compressing vital structures & occasionally lead to pathologic fracture.<sup>5-9</sup>

Cyst enucleation & removal of the impacted tooth or supernumerary tooth should be considered as standard treatment modality of dentigerous cyst for adults.

In our cases, cystic enucleation with removal of an involved tooth was preferred because of large size of the cyst, and also had history of trauma that lead to developmental & eruption disturbances of adjacent teeth which may result in dentigerous cyst.<sup>5-9</sup>

It should be borne in mind that radiographic findings are not diagnostic for dentigerous cyst because odontogenic keratocyst, unilocular ameloblastoma & many other odontogenic tumours have radiological features identical to those of dentigerous cyst. These are ruled out after incisional biopsy.<sup>5-9</sup>

Microscopic examination of dentigerous cyst reveals a thin non-distinctive non-keratinized, fluid filled, epithelium lined sac. The epithelial lining consists of two to four layers of cuboidal epithelial cells & the epithelial connective tissue interface is flat. It is possible for the lining of dentigerous cyst to undergo neoplastic transformation & thus has been reported.<sup>5</sup>

Patient age, size of cystic lesion should be taken into consideration for treatment of dentigerous cyst.

In our cases, cystic enucleation with removal of impacted tooth was done because of the large size of the cyst.

Our treatments were curative and bone formation was complete with no recurrence.

### Conclusion

Early detection and treatment planning for such uncommon cases is required to prevent further complications.

**Conflict of Interest:** None.

**Patient Consent:** Obtained.

### Reference

1. Erzurumlu Zerrin, Dentigerous cyst of the jaws: clinical and radiological findings of 18 cases, *J Oral Maxillofac Radiol* 2014;2(3).
2. Shah KM, Dentigerous cysts associated with an impacted anterior maxillary supernumerary tooth, *BMJ Case Rep* 2013., doi:10.1136/bcr-2012-008329.
3. M S Malini, Dentigerous cyst associated with impacted third molar, *J Health Sci Res* 2015;6(1):11-3.
4. Dentigerous cyst involving permanent incisor: A case report; *S M Dent Oral Disord* 2017,1(1):1002.
5. M.H. K Motamedi. Management of extensive dentigerous cyst, *Br dent j* 2005;198(4):
6. Assael L. A, Surgical management of odontogenic cysts and tumours, *Princ Oral And Maxillofac Surg* 1992;2:685-8.
7. Neville B W, Odontogenic cysts and tumours, *Oral Maxillofac Pathol* 1995;493-6.
8. Regezi J A, Cyst and cystlike lesions, *Atlas Oral Maxillofac Pathol* 2000;88.
9. Conservative treatment of dentigerous cysts in children: report of four cases, *J Oral Maxillofac Surg* 2001;59:331-4.
10. Dentigerous cyst associated with permanent central incisor: A rare entity, *J Indian Soc Pedod Prev Dent* 2005;23:49-50.
11. Ustuner E, Fitoz S, Atasoy C, Erden I, Akyar S. Bilateral maxillary dentigerous cysts: a case report. *Oral Surg, Oral Med Oral Pathol, Oral Radiol, Endodontol* 2003;1:95(5):632-5.
12. Garvey MT, Barry HJ, Blake M. Supernumerary teeth-an overview of classification, diagnosis and management. *J Can Dent Assoc* 1999;65(11):612-6.
13. Giancotti A, Grazzini F, De FD, Romanini G, Arcuri C. Multidisciplinary evaluation and clinical management of mesiodens. *J Clin Pediatr Dent* 2002;26(3):233-7.
14. Scolozzi P, Lombardi T, Richter M. Upper lip swelling caused by a large dentigerous cyst. *Eur Arch Oto RhinoLaryngol Head Neck* 2005;1;262(3):246-9.
15. Benn A, Altini M. Dentigerous cysts of inflammatory origin: a clinicopathologic study. *Oral Surgery, Oral Medicine, Oral Pathology, Oral Radiol Endod* 1996;1;81(2):203-9.
16. Shear M. Cysts of the jaws: recent advances. *J Oral Pathol Med* 1985;14(1):43-59.

**How to cite this article:** Wadde K, Alam N, Chapane A, Dentigerous cyst of the jaws: A case series. *J Oral Med, Oral Surg, Oral Pathol, Oral Radiol* 2019;5(1):14-7.