

## Diagnostic accuracy of digital paranasal sinus view and computed tomography in the evaluation of maxillary sinusitis – A comparative study

Fahd Al Qahtani

Dean, Faculty of Dentistry, Diagnostic and Neuro-vascular Interventional Radiologist, King Fahad Hospital, Al Baha University, Al Baha, Kingdom of Saudi Arabia

**\*Corresponding Author: Fahd Al Qahtani**

Email: [fnq900@yahoo.com](mailto:fnq900@yahoo.com)

### Abstract

**Aim:** The purpose of this study was to assess the diagnostic efficacy of digital Water's radiographic view as compared to the CT scan for evaluation of the patients with maxillary sinusitis.

**Materials and Methods:** A total of 334 patients (110 women and 224 men with a mean age of 34.47 years) who were clinically suspected for acute or chronic rhinosinusitis were included in the study conducted in King Fahad Hospital, Al Baha, Kingdom of Saudi Arabia. Digital Water's radiographic view and CT scan from the sinonasal area was taken for all patients. These radiographs and CT scans were independently viewed by three equally experienced maxillofacial radiologists who were blinded to the study and the relationship between the radiographs. Sensitivity, Specificity, Positive predictor values and negative predictor values were calculated and compared for each.

**Results:** 110 females and 224 males with a mean age of  $34.47 \pm 9.43$  years (Mean  $\pm$  Standard Deviation). From 668 maxillary sinuses evaluated, 12 were totally opacified (1 bilateral and 11 unilateral). CT scan showed sensitivity of 91.23%, specificity of 86.02%, positive predictive value of 94.62% and negative predictive value of 78.43%. The digital radiograph showed sensitivity of 86.89%, specificity of 77.41%, positive predictive value of 89.23% and negative predictive value of 72.92%. Water's' view showed high sensitivity and specificity in detecting the opacified maxillary sinuses. Among 334 patients, 245 had nasal septum deviation detected on CT scans.

**Conclusion:** Water's' views show a reasonably acceptable diagnostic value in sinonasal area. Digital Caldwell's view performs well in assessing maxillary sinus opacification, as well as nasal septum deviation. It has average efficacy in cases of maxillary mucosal thickening.

**Keywords:** Radiography, Computed tomography, Maxillary, Sinusitis.

### Introduction

Inflammatory diseases which affect the paranasal sinuses, especially the maxillary sinus, are fairly common in the world. It usually affects the children and adults equally. Also termed as rhinosinusitis, it occurs both in acute forms and chronic forms, with the acute form being more common and prevalent. Rhinosinusitis has four distinctive categories based on the duration of the symptoms. When the symptoms are resolved within 4 weeks, it is termed as acute rhinosinusitis. If the symptoms last 4-8 weeks, with a more insidious onset, it is termed as subacute sinusitis or unresolved acute rhinosinusitis. The definition of chronic sinusitis states that it is a constant inflammatory state of the sinuses of the para-nasal region that persists for a duration excess of eight weeks. If the patient has three or more repeated episodes in a single year, then it is termed as chronic sinusitis.<sup>1,2</sup> Chronic rhinosinusitis is characteristically classified into two clinically distinguishable types, the main difference between the two being the presence of a nasal polyp. It is termed as chronic rhinosinusitis with nasal polyposis and chronic rhinosinusitis without nasal polyposis. Factors such as allergic conditions, anomalies in the usual anatomy, genetic factors can increase the susceptibility of an individual to developing chronic sinusitis.<sup>3-5</sup>

A proper paranasal sinus radiographic view or Water's view (Occipitomental View) has long been considered the

most trustworthy accessory in the diagnosis of rhinosinusitis. But the computed tomography (CT) is in reality the mainstay of sinonasal area imaging. It can be considered as the Gold Standard in this field, but the standard digital plain film radiography also is very useful, especially in the initial diagnosis of inflammation of the sinus. With the advent of digital radiography, it has become even more reliable in this field. The main radiographic criteria for diagnosing maxillary sinusitis are presence of air fluid levels, thickening of the sinus mucosa and opacification of the sinus.<sup>6,7</sup> These can be easily visualized on a plain film radiograph. Another advantage of the digital radiograph is that it has a significantly decreased radiation exposure to the patient, and can produce realistically high-resolution images. This is particularly beneficial for assessment of the bony landmarks in and around the sinuses.<sup>8-10</sup>

As technology has advanced, plain film radiography has become state of the art. With the myriad advances in imaging technology, digital plain films have become increasingly effective and better than ever before. Digital radiography, although with limitations, has certain distinct and important advantages over the CT scan. It is easily available and readily accessible. It is easy to use and requires moderate expertise and has a much lower radiation exposure for the patient. Also it is very cost effective.<sup>11,12</sup> With emergence of image enhancement in digital imaging,

results of plain field radiography have touched new heights. One may state that digital plain radiography might be considered as an uncomplicated and appropriate imaging modality in initial diagnosis of inflammatory sinus disease.

Less amount of scientific literature exists which evaluates the diagnostic effectiveness of the Water's view in comparison to the CT scan for preliminary assessment of Maxillary sinusitis. Therefore, the present study was undertaken to evaluate the use, and investigate the reliability of digital Water's radiographic views for initial assessment of the patients with maxillary sinusitis.

## Materials and Methods

The present study was conducted in King Fahad Hospital, Al Baha, Kingdom of Saudi Arabia. Patients who reported to the hospital from January 2015 to December 2018 and were provisionally diagnosed as having rhinosinusitis were included in the study. They were referred to the Department of Radiology for the radiographic evaluation. All these patients had at least one or more of the four major signs and symptoms of sinusitis. These included blockage of the nose due to congestion, running nose with discharge which was mucopurulent in nature, moderate to severe pain in the face and head region, pressure and fullness in the head and face, or anosmia / decreased sense of smell. Their physicians had advised digital Water's radiographic view for first radiographic valuation of the maxillary sinuses for each of these patients. Initial assessment was done using these radiographs, and if required, CT scan of the same sinus and nasal area was advised for the patients who warranted a more comprehensive assessment. This study was based on a similar study by Ebrahimnejad H et al (2016).<sup>13</sup>

The inclusion criteria for the study were patients having sinusitis as defined above, patients not suffering from any major illness, patients willing to participate in the study by signing an informed consent, and patients who underwent the radiograph and the CT scan on the same date. The regional ethics committee clearance was taken and the study did not involve any intervention on the patients and was a purely radiographic study from patients referred for radiographs by physicians. Those patients who had undergone any procedures or intervention like medication, nebulisation, etc. in between the time period of plain films and CT scan were excluded from the study. Other type of patients excluded were patients with a recent history of maxillary traumatic injuries and those having sinus pathologies and masses. The Water's View radiographs were captured by Siemens Multix system (Riyadh, Saudi Arabia) 65kW (650mA at 100kV) under automatic exposure control. The CT scans were obtained and evaluated with Siemens Stomatom (Riyadh, Saudi Arabia) at 80-100kW, 70-140kVP, rotation time=0.5 seconds, pitch=0.531 and slice interval=2mm. All the images so obtained were

rendered with the assistance of an algorithm of digital reconstruction, which had a high spatial frequency (high spatial frequency reconstruction algorithm).

The digital Water's view and CT scan of each patient was acquired as stated above. Three equally experienced and previously calibrated maxillofacial radiologists reviewed the radiographs and the CT scans independently. These reviewers were blinded to any kind of connection amid the radiographs and the study. A separate evaluation was done for both the right side and the left side maxillary sinuses. Three parameters assessed were (1) thickening of the maxillary sinus mucosa, (2) opacification of the maxillary sinus, and (3) deviation of the nasal septum. The viewing condition was maintained as even and similar as possible. The Water's radiographs were used for the maxillary sinuses and Nasal septum deviation assessment.

Thickening of the mucosa was noted as 'present' or 'absent' for Water's view as it is difficult to reliably measure the thickness in the same. In the CT scan, the thickening of the maxillary sinus mucosa was evaluated by measuring the mucosal thickness from the maximum mucosal prominence to the corresponding sinus wall. If this thickness was found to exceed 3 millimetres it was noted as pathological.<sup>14</sup> Nasal septum deviation was assessed on the coronal section of the CT scans as described by Ebrahimnejad H et al.<sup>13</sup> Two lines were drawn on the scan. The first line was drawn from the base of the crista galli to the most deviated position of the septum of the nose. The second line was drawn from the base of the crista galli of ethmoid bone (superior insertion of septum) to the inferior insertion of septum at the level of maxillary crest. These two lines intersected superiorly and formed an angle. This was duly measured and noted, in degrees, as the deviation of the septum of the nose. Occasionally, severely deviated nasal septae were encountered on the CT scans and the radiographs. In such cases, like S shaped curved septa, the greater deviated side was used for measurements. The diagnostic efficacy of the Water's view findings were evaluated using the CT scan as a reference. The data so obtained was compiled, descriptive statistical methods were used, and the results were obtained.<sup>16</sup>

## Results

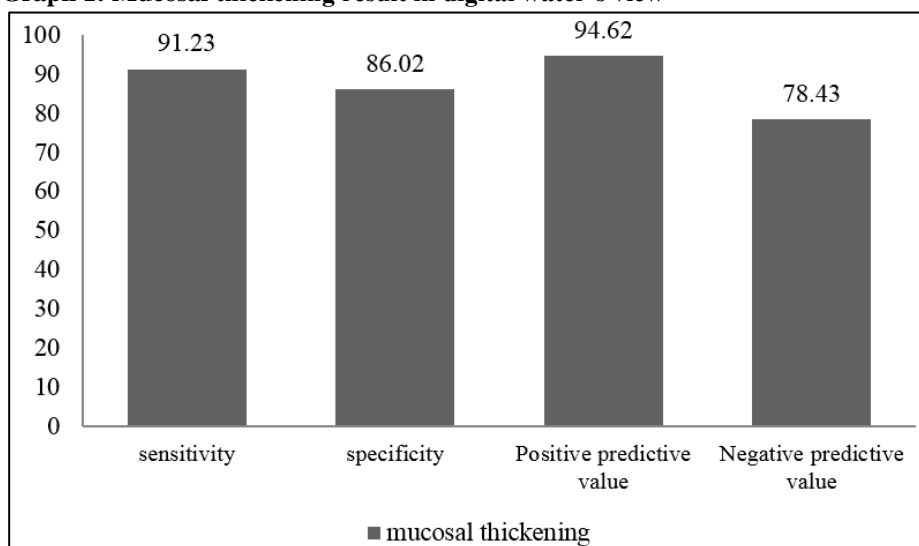
A total number of 334 patients participated in the 4 year long study. Out of the 334 patients, 110 were females and 224 were males. The overall mean age was  $34.47 \pm 9.43$  years (Mean  $\pm$  Standard Deviation). Our study showed that sinusitis was more common in the adult male population. As stated earlier the right and the left maxillary sinuses were evaluated separately, so a total of 668 maxillary sinuses were evaluated. Out of the total, 12 were entirely opacified with one patient having bilateral opacification and the other ten patients had unilateral opacification. For maxillary sinus thickening, Water's view

showed sensitivity of 91.23%, specificity of 86.02%, positive predictive value of 94.62% and negative predictive value of 78.43% (Graph 1). For complete opacification, Water's view showed sensitivity of 82.51%, specificity of 79.02%, positive predictive value of 59.13% and negative predictive value of 62.44% (Graph 2). For nasal septal deviation, Water's view showed sensitivity of 86.89%, specificity of 77.41%, positive predictive value of 89.23% and negative predictive value of 72.92% (Graph 3) as compared to the CT scan.

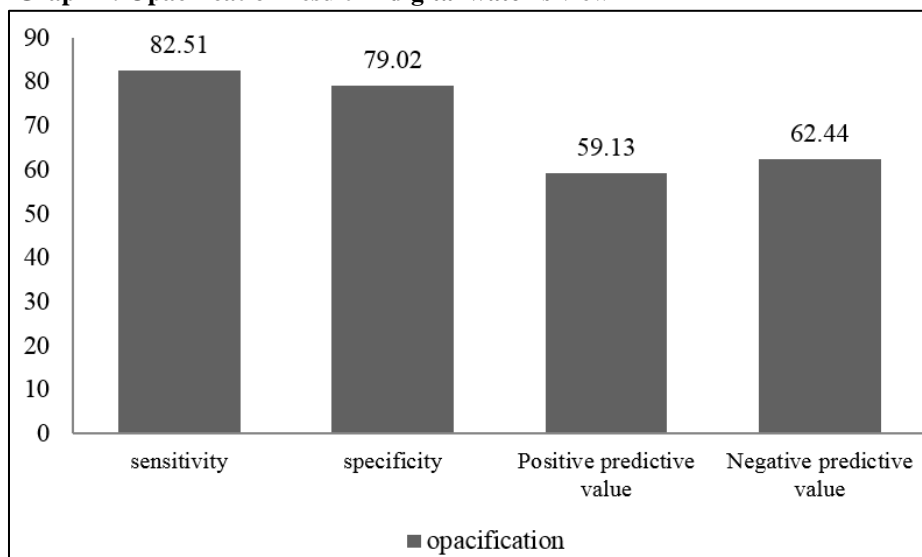
In the present study, even though it had a low positive prediction value, the Water's view showed high sensitivity

and specificity as far as detection of the opacified maxillary sinuses was concerned. In the present study population of 334 patients, nasal septal deviation was observed in the CT scans of 245 individuals. A graphical representation of the radiographic evidence of sinusitis (opacification and pathological mucosal thickening) is depicted as a bar chart for each parameter (Graph 1-4, Table 1). The maxillary sinus mucosal thickening of >3mm was seen in 404 sinuses. On comparison with the CT scan, the digital Water's view showed a higher sensitivity than specificity. This was used to show the efficacy of Water's views in detecting inflammatory maxillary sinus disease.

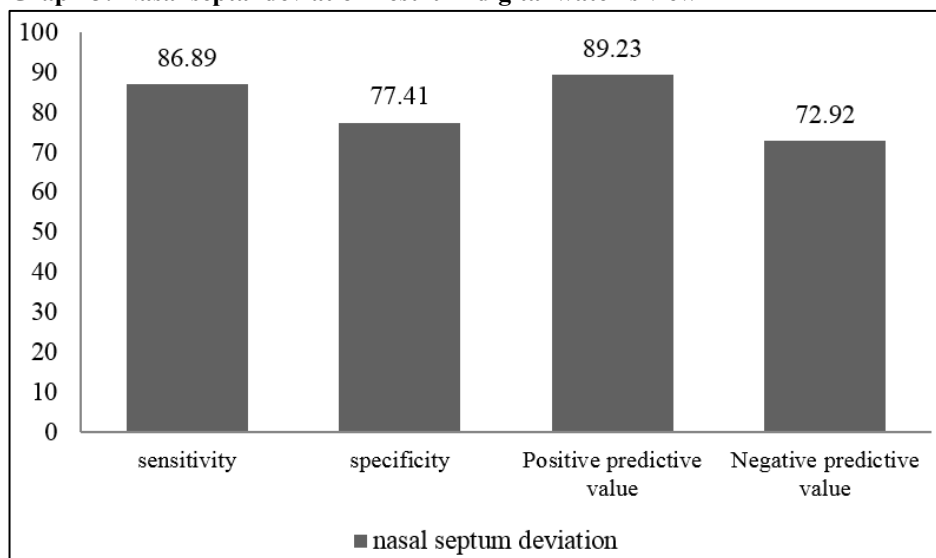
**Graph 1: Mucosal thickening result in digital water's view**



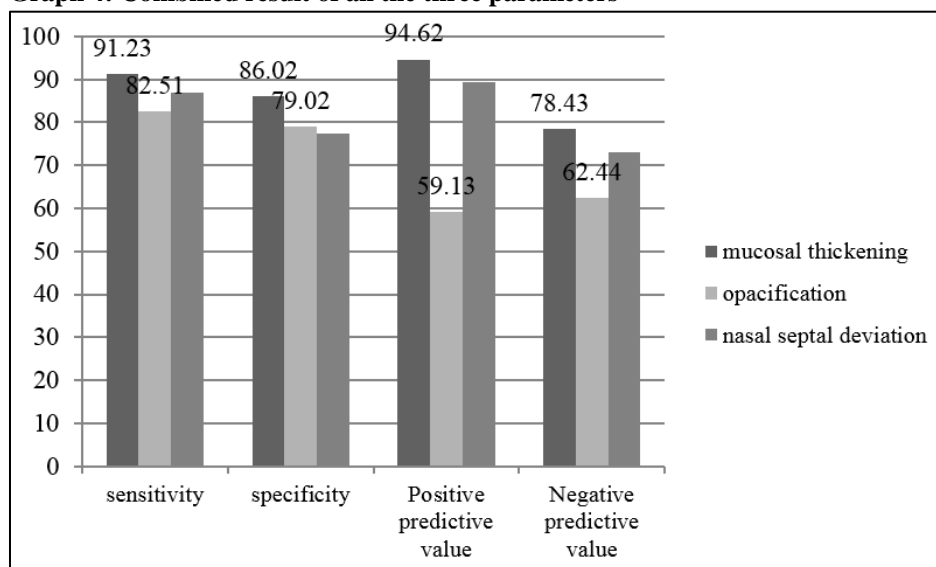
**Graph 2: Opacification result in digital water's view**



**Graph 3: Nasal septal deviation result in digital water's view**



**Graph 4: Combined result of all the three parameters**



**Table 1: Combined result of CT scan and radiograph for maxillary sinusitis**

Parameter	Sensitivity percentage	Specificity percentage	Positive Predictive Value percentage	Negative Predictive Value percentage
Mucosal Thickening	91.23	86.02	94.62	78.43
Opacification	82.51	79.02	59.13	62.44
Nasal Septal Deviation	86.89	77.41	89.23	72.92

**Discussion**

There are very less previous studies which have evaluated the reliability of digital plain films for assessment of paranasal sinuses. Therefore, to assess the same, the current investigative study was undertaken. The aim was the assessment of the diagnostic effectiveness of digital Water's radiographs for maxillary sinusitis. The present study had an advantage of having a fairly large sample size. Digital

simultaneous image capturing was done for each patient. This considerably amplified the trustworthiness of the results. It is well known that inflammatory sinonasal diseases are highly common and prevalent. Thus, they require an easy, fairly accurate and cost effective way for assessment as related their imaging modalities.<sup>10,11</sup>

In the current research digital Water's view was used for the preliminary or initial maxillary sinus evaluation. In a

study done by Burke et al.<sup>14</sup> the authors evaluated the specificity as well as the sensitivity of paranasal sinus radiographs of thirty patients. The patients had a clinically proven diagnosis of acute sinusitis. The CT scan was used as a control, and the plain films were evaluated and compared with it. As soon as the patients were enrolled in the study, paranasal sinus x-rays were acquired as the first step. Thereafter, computed tomography (CT) scans were done within 3 days. The radiologic diagnostic criteria for sinusitis, as defined by the authors, were more than 3 mm of sinus mucosal thickening, presence of an air/fluid level, or opacification of the sinus. Sensitivity and specificity of maxillary sinus opacification were 70% and 100%, and of air/fluid level were 70% and 96%. This is fairly in accordance with the results of the present study. The present study results, however, showed a decreased specificity and an increased sensitivity.

In the present study, an uncommon finding was the absolute opacification of the maxillary sinus. Most of the times, this indicates an underlying severe inflammatory condition like chronic maxillary sinusitis, or a pathological condition, like maxillary sinus tumors.<sup>7</sup> This can emphasize the detail that that the digital Water's view is a acceptable modality for preliminary maxillary sinus evaluation. In the present study, almost all the positive opacification records on Water's radiographs showed pathological mucosal thickening on CT scan.

Another study by Inuma et al<sup>17</sup> examined the reliability of conventional views in predicting the degree of radiopacity of the sinuses. This was irrespective of soft tissue or fluid seen in chronic sinusitis in adults. Total 97 sides of paranasal sinuses of 61 patients suffering with sinusitis were evaluated using plain films. Their CT scans acted as the control. The authors characterized the plain film findings into 3 main headings as (1) under-diagnosis, (2) matched-diagnosis and (3) over-diagnosis. Matched-diagnosis was reported in ethmoidal sinuses, maxillary sinuses and the frontal sinuses. The highest incidences of matched diagnosis were noted to be 78.4% for the maxillary sinus and 71.1% for the frontal sinus. For the other areas, percentages were nasofrontal area (66.0%), anterior ethmoidal cells (52.6%), and posterior ethmoidal cells (52.6%). The posterior ethmoidal cells revealed the highest incidence of over-diagnosis (52.6%), while it was found to be the smallest in the maxillary sinus (20.6%). The anterior ethmoidal cells showed the maximum incidence of under-diagnosis (24.7%). The least under-diagnosis was seen in the maxillary sinus (1.0%).

The results of the current study favour that as far as radiographic signs of maxillary sinusitis are concerned, the assumption that digital Water's view can adequately illustrate them is correct. A varying degree of deviation of nasal septum was seen in 245 patients (73.35%). Water's views correctly diagnosed it in a majority of cases. With

more degree of deviation, the diagnostic efficacy of the digital radiograph increased significantly. It particularly performed fine in this regard.

In another study undertaken by Konen et al.<sup>18</sup> a high resolution CT was used as a reference and compared with a solitary waters' view for the diagnosis of paranasal sinusitis. In their research, a total of 134 patients participated. They were diagnosed to be suffering from sinusitis, and each of them had the Water's view and the CT scan taken. Their results revealed a weighted mean sensitivity of 67.7% for diagnosis of any abnormality in the maxillary sinus. At the same time, it had a higher specificity of 87.6%. The accuracy was deduced to be 78.6% having a positive predictive value of 82.5% and a negative predictive value of 76.9%. In case of the the frontal and ethmoid sinuses, the inter-observer sensitivity for disease diagnosis varied far and wide. It ranged from 0% to 58.9% for the ethmoid sinus and 1.9% to 54.0% for the frontal sinus. As far as the sphenoid sinus was concerned, its sensitivity was exceedingly low, ranging from 0% to 3.8%. It was also noted in their study that inter-observer variation in case of the maxillary sinus was the least. This was even in radiographs which seemed to demonstrate it well. These findings regarding the maxillary sinus were confirmed by the present study.

Pfister et al<sup>19</sup> have stated that there appears to be a regular association between bronchial asthma and sinusitis. Patients who suffer from asthma often have chronic inflammatory changes in the paranasal mucosa. Their study compared the rankings of standard radiography and A-mode ultrasonography as a regular screening procedure in the preliminary radiographic workup of these patients. On comparing, the computed tomography showed mucosal thickening in 61% of the maxillary sinuses. The other sinuses combined showed a mucosal thickening in 74% of the patients. The sensitivity for minimal mucosal hyperplasia was low (52.2%), despite the fact that almost all the cases of severe mucosal thickening were detected. The plain-view radiography gave a specificity of 86.7% for the maxillary sinuses in comparison with the results of computed tomography. However, in contrast, a sensitivity of 70% but a specificity of 22% was noted in A-mode ultrasonography.

Another similar study on 47 patients by undertaken by Aaløkken et al.<sup>20</sup> They also used the CT scan as the control. They compared and assessed the diagnostic efficacy of Water's and Caldwell's views for detecting sinusitis in reference to the CT scans. It was found that in detecting inflammation of the paranasal sinuses, the sensitivity was low for the frontal and ethmoidal sinuses, but the specificity was high for all the sinuses. Only for the maxillary sinusitis both the sensitivity and specificity were high.

Timmenga et al<sup>21</sup> did a study on 40 patients with diagnosed sinusitis. Their study attempted to assess the

diagnostic importance of the Water's radiograph, using the CT scan as the gold standard. Their study revealed that for the Water's view, the sensitivity was 83.3%, specificity was 69.2% and the positive predictive value was 83.3%. Our study results are in agreement with the above study, however, our results showed a higher sensitivity.

Ezeanolue et al<sup>22</sup> undertook a study with the objective of examining different plain radiographic features and correlate them with antral lavage results in patients suffering from chronic maxillary sinusitis. Their study demonstrated that both antral opacity and air fluid levels had a specificity of 92.3% each. The positive predictive value of antral opacity was 96.0%, and for air fluid levels was 87.5%. For gross mucosal thickening and haziness, the specificity was 36.7% and the positive predictive value was 29.4%. Both the values were in the lower range. Their results are not in agreement to the present study.

Some may argue that plain radiography has certain shortcomings. It suffers from reliability issues, even with most experienced radiologists. Also, the observer errors are extremely common. On the other hand, it has some distinct advantages, the foremost being a relative ease of interpretation. It is highly cost effective and much more readily available everywhere in the world, as compared to the CT scan.<sup>23</sup> It also has a much lower radiation dose, reducing the patient and operator radiation exposure. It has been shown in a study by Yoo et al<sup>24</sup> that effective doses measured for digital radiography are much less than that of the CT Scan of the paranasal sinuses. They found that the mean effective doses were to be  $29 \pm 6 \mu\text{Sv}$  for plain film radiography,  $48 \pm 10 \mu\text{Sv}$  for digital tomosynthesis, and  $980 \pm 250 \mu\text{Sv}$  for the CT scan. Though they are fairly good for the initial assessment of sinusitis, plain films may not be reliable enough to assist with the final diagnosis. If severity of illness requires diagnostic certainty, more sensitive imaging studies, such as CT scanning, should be considered. The Sinus x-rays are also less sensitive than sinus CT scans for demonstration of radiographic changes consistent with acute sinusitis.<sup>14</sup>

## Conclusion

It can thus be safely concluded from the above study that for the preliminary diagnosis of the inflammatory diseases of the sinuses, the digital water's views show a reasonably acceptable value. It also demonstrates moderately superior results in assessing maxillary sinus opacification, as well as nasal septum deviation. Digital water's view appears to be a practically reliable modality for maxillary sinusitis preliminary evaluation, even though it has average efficacy in detecting cases of maxillary mucosal thickening. It also is very cost effective for the patient, and considerably reduces the radiation dose to the patient. Thus it can be used a valuable tool in initial assessment of sinusitis.

**Conflict of Interest:** None.

## References

1. Fokkens W, Lund V, Mullol J. European position paper on rhinosinusitis and nasal polyps 2007. *Rhinol* 2007;20 suppl:1-136.
2. Sedaghat AR. Chronic Rhinosinusitis. *Am Fam Physician* 2017;96(8):500-6.
3. Rao JJ, Kumar EV, Babu KR, Chowdary VS, Singh J, Rangamani SV. Classification of nasal septal deviations—relation to sinonasal pathology. *Indian J Otolaryngol Head Neck Surg* 2005;57(3):199-201.
4. Calhoun KH, Waggenspack GA, Simpson CB, Hokanson JA, Bailey BJ. CT evaluation of the paranasal sinuses in symptomatic and asymptomatic populations. *Otolaryngol Head Neck Surg* 1991;104(4):480-3.
5. Rosenfeld RM, Piccirillo JF, Chandrasekhar SS, et al. Clinical practice guideline (update): adult sinusitis. *Otolaryngol Head Neck Surg* 2015;152(2 suppl):S1–S39.
6. Kay NJ, Setia RN, Stone J. Relevance of conventional radiography in indicating maxillary antral lavage. *Ann Otol Rhinol Laryngol* 1984;93(1pt1):37-8.
7. Varonen H, Makela M, Savolainen S, Laara E, Hilden J. Comparison of ultrasound, radiography, and clinical examination in the diagnosis of acute maxillary sinusitis: a systematic review. *J Clin Epidemiol* 2000;53(9):940-8.
8. Mafee MF, Tran BH, Chapa AR. Imaging of rhinosinusitis and its complications: plain film, CT, and MRI. *Clin Rev Allergy Immunol* 2006;30(3):165-86.
9. Momeni AK, Roberts CC, Chew FS. Imaging of Chronic and Exotic Sinonasal Disease: review. *AJR Am J Roentgenol* 2007;189(6 Suppl):S35-45.
10. González Morales JE, Leal de Hernández L, González Spencer D. Usefulness of simple paranasal sinus radiographs and axial computed tomography in the diagnosis of chronic sinusitis. *Rev Alerg Mex* 1998;45(3):17-21.
11. Williams JW Jr, Roberts L Jr, Distell B, Simel DL. Diagnosing sinusitis by X-ray: is a single Waters view adequate? *J Gen Intern Med* 1992;7(5):481-5.
12. Cowen AR, Davies AG, Kengyelics SM. Advances in computed radiography systems and their physical imaging characteristics. *Clin Radiol* 2007;62(12):1132-41.
13. Ebrahimnejad H, Zarch SHH, Laugaroodi AJ. Diagnostic efficacy of Digital Water's and Caldwell's Radiological views of the sinonasal area. *J Dentistry Tehran Univ Med Sci* 2016;13(5):357-64.
14. Burke TF, Guertler AT, Timmons JH. Comparison of sinus x-rays with computed tomography scans in acute sinusitis. *Acad Emerg Med* 1994;1(3):235-9.
15. Elahi MM, Frenkiel S, Fageeh N. Paraseptal structural changes and chronic sinus disease in relation to the deviated septum. *J Otolaryngol* 1997;26(4):236-40.
16. Chu K. An introduction to sensitivity, specificity, predictive values and likelihood ratios. *Emerg Med Australas* 1999;11(3):175-81.
17. Iinuma T, Hirota Y, Kase Y. Radio-opacity of the paranasal sinuses. Conventional views and CT. *Rhinol* 1994;32(3):134-6.

18. Konen E, Faibel M, Kleinbaum Y, Wolf M, Lusky A, Hoffman C, et al. The value of the occipitomeatal (Waters') view in diagnosis of sinusitis: a comparative study with computed tomography. *Clin Radiol* 2000;55(11):856-60.
19. Pfister R, Lütolf M, Schapowal A, Glatte B, Schmitz M, Menz G. Screening for sinus disease in patients with asthma: a computed tomography-controlled comparison of A-mode ultrasonography and standard radiography. *J Allergy Clin Immunol* 1994;94(5):804-9.
20. Aaløkken TM, Hagtvedt T, Dalen I, Kolbenstvedt A. Conventional sinus radiography compared with CT in the diagnosis of acute sinusitis. *Dentomaxillofac Radiol* 2003;32(1):60-2.
21. Timmenga N, Stegenga B, Raghoobar G, van Hoogstraten J, van Weissenbruch R, Vissink A. The value of Waters' projection for assessing maxillary sinus inflammatory disease. *Oral Surg Oral Med Oral Pathol Oral Radiol Endod* 2002;93(1):103-9.
22. Ezeanolue BC, Aneke EC, Nwagbo DF. Correlation of plain radiological diagnostic features with antral lavage results in chronic maxillary sinusitis. *West Afr J Med* 2000;19(1):16-8.
23. Zinreich GJ. Imaging of chronic sinusitis in adults: x-ray, computed tomography, and magnetic resonance imaging. *J Allergy Clin Immunol* 1992;90:445-51.
24. Yoo JY, Chung MJ, Choi B, Jung HN, Koo JH, Bae YA, Jeon K, Byun HS, Lee KS. Digital Tomosynthesis for PNS Evaluation: Comparisons of Patient Exposure and Image Quality with Plain Radiography. *Korean J Radiol* 2012;13(2):136-43.

**How to cite this article:** Qahtani FA. Diagnostic accuracy of digital paranasal sinus view and computed tomography in the evaluation of maxillary sinusitis – A comparative study. *Int J Maxillofac Imaging* 2019;5(1):3-9.