

Cone beam computer tomography a crossway in diagnosis of nasopalatine cyst - A case report

Astha Shrivastava^{1*}, Jaideep Sur², Fatima Khan³, Swati Prasad⁴, Sucharita Roy⁵

^{1,5}PG Student, ²Professor, ³Reader, ⁴Senior Lecturer, Dept. of Oral Medicine and Radiology, Rungta College of Dental Sciences and Research, Bhilai, Chhattisgarh, India

***Corresponding Author: Astha Shrivastava**

Email: asshrivastava.astha@gmail.com

Abstract

Cone beam computer tomography (CBCT) is an advance imaging modality which is very useful for detection of the three dimensional structure or deformity affecting oral and the maxillofacial region and an ideal imaging modality for cystic lesion.¹ Nasopalatine cyst is a developmental, epithelial, non-neoplastic cyst that is considered to be the most common non-odontogenic cyst affecting the maxillofacial region.² These are asymptomatic constituting regular radiological findings, although sometimes patients may report pain due to the compression of structures adjacent to the cyst, it appears as a well-corticated, round or pear shaped radiolucency circumscribed to the maxillary inter incisal region at the midline.^{2,3} Presenting a case of 29 year male patient who has reported to the department with a chief complain of oozing purulent material from anterior region of palate, which was diagnosed as nasopalatine cyst with the help of CBCT surgical correction was done, with satisfactory healing of lesion in CBCT on 10th month follow up.

Keywords: Cone beam computer tomography, Nasopalatine cyst.

Introduction

Nasopalatine cyst is a non- neoplastic, epithelial and developmental cyst that is noted as the most common cyst found in maxillofacial region that is non odontogenic in nature. It is unique in that it develops in a single location – in the midline in anterior maxilla.⁵ This cyst includes about 1% of all cysts involving the maxilla with a high prevalence in male, with the mean age being 43 years.⁵ The cyst has been found to be asymptomatic, constituting regular radiological findings, although sometimes patients mat complain of pain due to the compression created by the cyst to the adjacent structures, the cyst gives an appearance of well-corticated, round to oval, pear or heart-shaped radiolucency present in the maxillary inter incisal region on the midline.⁵ (Fig. 1)

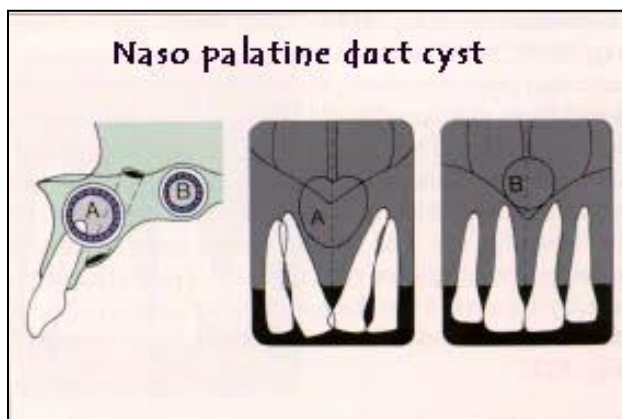


Fig. 1

Case Report

25 year male patients encountered to the outpatient department with a chief complain of a swelling in upper front region of tooth and spillage of purulent material from the same place since 6 month. Patient given habit history of cigarette and Gutkha occasionally since 5 years but has quit the habit 6 month before. Patient was adequately built with normal vital signs. (Fig. 2)

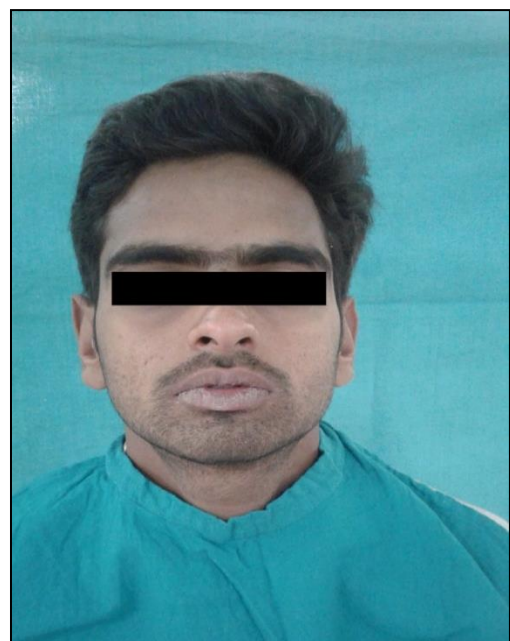

Fig. 2

On Extra oral Examination

There was no appreciable extra oral abnormality was present intraoral examination revealed on inspection, mild inflammation was present on mid palatine raphe involving the incisive papilla with slight swelling extending from incisive papilla till middle portion of the mid-palatal raphe of approximately 1.5 cm in diameter. On palpation, overlying mucosa was non-tender, non-compressible with no sign of drainage and it does not bleed on provocation. Pocket was present in relation to 12, pulp testing shows vital 11, 12 and stains, calculus was present.

On the basis history and clinical examination a provisional diagnosis of periodontal abscess in relation to 12 was made. A differential diagnosis of Nasopalatine cyst or Incisive canal cyst and periodontal cyst was considered on the basis of location and size of the lesion.

Radiological Examination

An anterior maxillary occlusal reveals pear shape radiolucency present in anterior region of maxilla with divergent root in relation to 11 and 21 involving nasopalatine duct canal and anterior one third of the maxilla of approximately 1.5 cm in diameter. (Fig. 3)

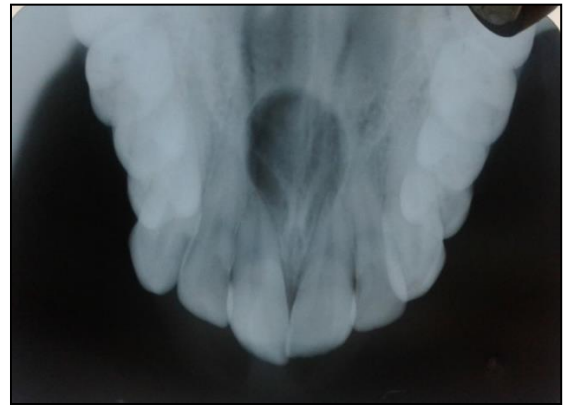


Fig. 3

Patient was then advised for a cone beam computer tomography which reveals a through and through communication of the maxillary antrum of 13.00×14.1 mm in diameter and antral communication of 3.7 mm. (Fig. 4).

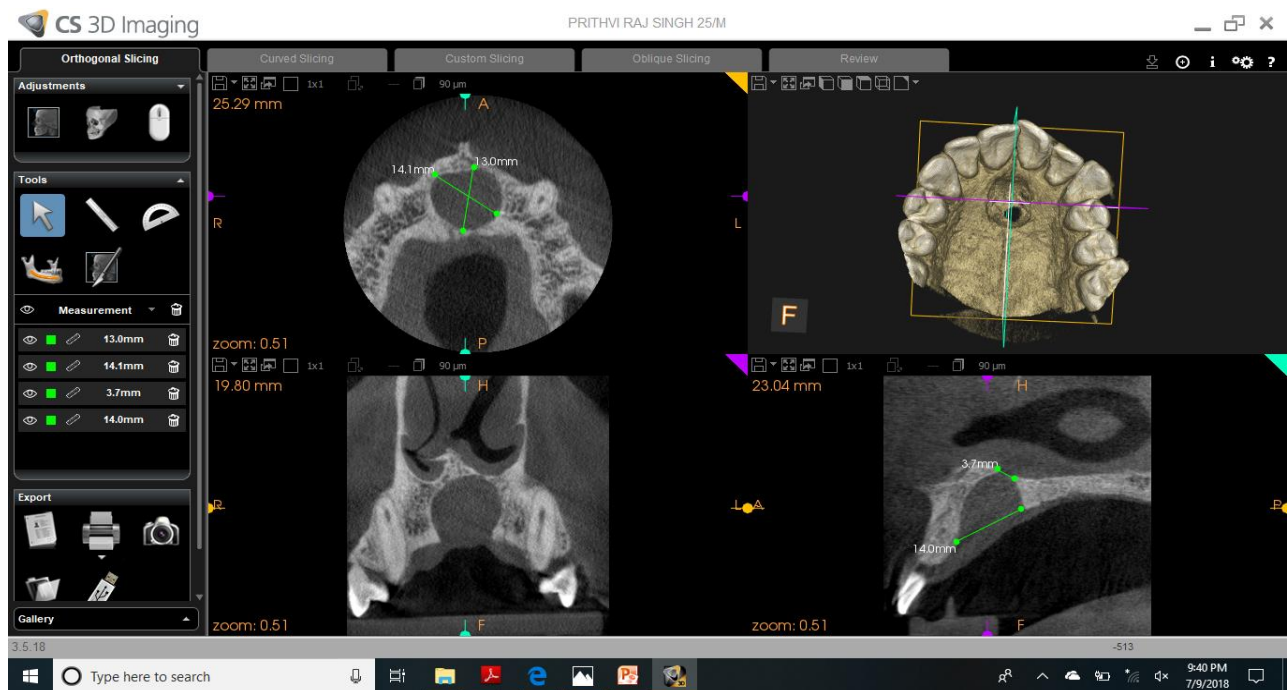


Fig. 4

Surgical enucleation of cyst was done and sent for histopathological examination. (Fig. 5)

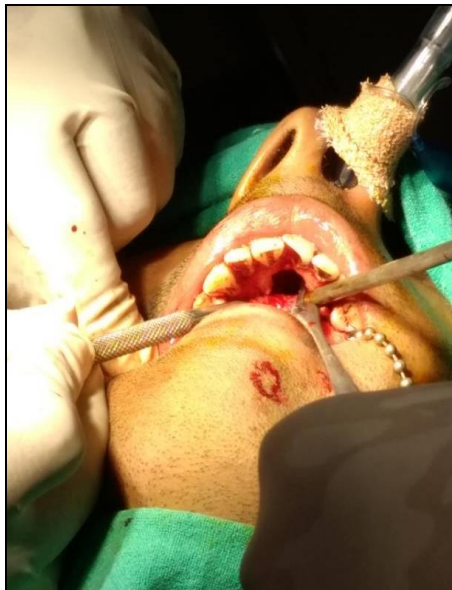

Fig. 5

Which shows H& E stained biopsy section showing stroma with severe chronic inflammatory predominante lymphocytes, plasma cell & macrophages. Few polymorphs are also intermixed with extravasated RBC'S inflammatory areas surrounded by fibrous capsule and areas of nerve bundles are also appreciated. Thin fragments of stratified

epithelium seen in the region of inflammatory area revealed secondary infected nasopalatine cyst. (Fig. 6)



Fig. 6

By reviewing the clinical, radiological and histopathological examination a final diagnosis of nasopalatine cyst was made. Follow-up shows no clinical signs and symptoms.

On 10 month follow up a CBCT was taken which shows satisfactory healing of the cystic lesion. (Fig. 7)

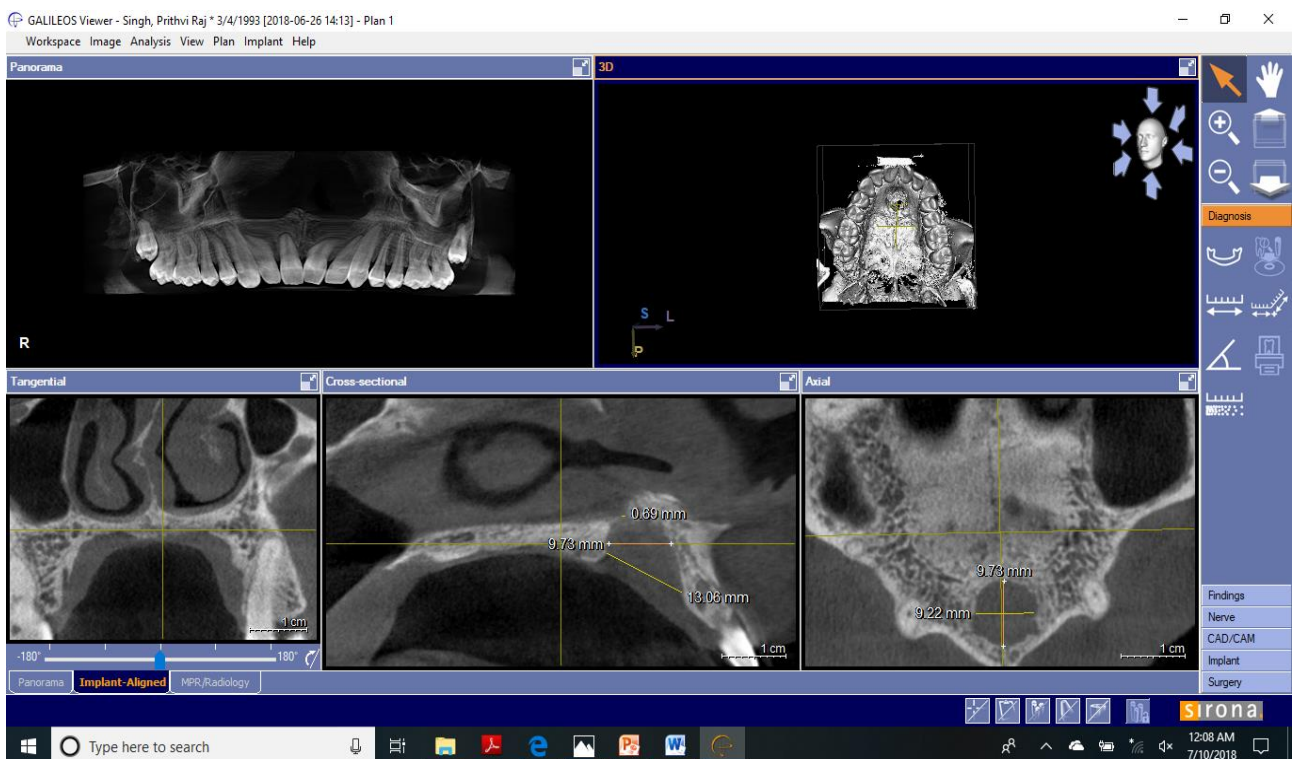


Fig. 7

Discussion

The cone beam computer tomography is a 3 dimensional advance imaging modality used in imaging of maxillofacial region. This enables the proper diagnosis of the extent of the lesion for proper planning of treatment. Nasopalatine cyst is non-odontogenic cyst which is said to be developing from the proliferation of embryological epithelial remnants of nasopalatine ductal cells. The studies shows a higher incidence of nasopalatine cyst among males as compare to females.⁶ It can be seen in any age but are more commonly found in the 4th to 6th decayed of life.⁶ In contrast to our case where 25 year male patient is diagnosed with the cyst. As it is a developmental cyst believed to arise from epithelial remnants of the nasopalatine duct it is assumed to be asymptomatic but in present case the patient was symptomatic as he complains of spillage of purulent material from the anterior palatal region during suckling. S. Shylaja et al have presented the similar case diagnosed as incisive canal cyst in 36yr old women which was diagnosed with the help of maxillary occlusal radiograph.⁷ F E Jaume et al have done a study comprising 22 patient diagnosed with incisive canal cyst which was diagnosed with the help of computerized tomography scan and panoramic radiographs.⁸ In contrast to in our case we used the prior occlusal radiograph which was only explanatory of the bony resorption of palatal region. Than a 3 dimensional imaging by CBCT was taken which revealed that there was a though and through communication present in the antrum. There was an palatal perforation of 13.0 × 14.1 mm and antral communication of 3.7 mm. E F Jaume has suggested a follow up of at least 1 year until the ossification the surgical zone was confirmed by the radiograph.⁸ Where as in our case we have taken a CBCT to confirm the ossification of the cyst on follow up which shows satisfactory healing of the lesion.

Conclusion

To diagnose a case of incisive canal cyst a proper screening of the patients should be done to know the extent of the lesion by radiographs and co relate it by three dimensional scan like CBCT scans should be mandatory to evaluate the exact dimension of cystic and bony lesions. The diagnosis is based on the history, exploration, and radiological exams co related with three dimensional scans (particularly CBCT Scan). The surgical removal the cyst was advised to prevent the further increment in the size of the lesion as soon as the diagnosis was confirmed. After the resection of the cystic lesion the relapse is unlikely to happen, but a post-operative follow up with the proper radiological evaluation of the lesion is mandatory for at least a time of one year.

Conflict of Interest: None.

References

1. W Stuart, P Michael. Text book of oral radiology. 7th edition. 2013.
2. G. Michael. Burket's Text book of Oral Medicine. 12th edition.2014.
3. G G Anil. Ghom's text book of oral medicine. 3rd edition. 2007.
4. R K Freny. Text book of Oral and Maxillofacial Radiology 3rd edition. 2014
5. B Sivapathasundharam. Shafer's Textbook of oral pathology. 8th edition. 2016.
6. T Nagaraj, S Gogula, CK Sumana, H Nigam. Incisive canal cyst - A case report. *Int J Med Dent Case Rep* 2017;4:1-2.
7. S. Shylaja K. Balaji A. Krishna. *Indian J Otolaryngol Head Neck Surg* 2013;65(4):385-8.
8. F E Jaume, M A Nieves, A B Leonardo, E G Cosme. *Med Oral Patol Oral Cir Bucal* 2008;13(7):E438-43.

How to cite this article: Shrivastava A, Sur J, Khan F, Prasad S, Roy S. Cone beam computer tomography a crossway in diagnosis of nasopalatine cyst - A case report. *Int J Maxillofac Imaging* 2019;5(1):15-8.