

Evaluation of efficacy of autologous platelet-rich fibrin along with decalcified freeze dried bone allograft in the management of mandibular grade -II Furcation defects –A clinical and radiographic study

Prameetha George Ittycheria^{1*}, Thomas George. V², Annie Kitty George³, Saumya John⁴, Nebu George⁵

^{1,4}Senior Lecturer, ²Professor and HOD, ³Associate Professor, ⁵Professor, ¹⁻⁵Dept. of Periodontology, ¹⁻⁵Pushpagiri College of Dental Science, Thiruvalla, Kerala, India

*Corresponding Author: Prameetha George Ittycheria

Email: drsajispd@rediffmail.com

Abstract

Aim: In the management of furcation defects a wide range of periodontal regenerative materials have been used. Platelet-rich fibrin (PRF), proposed by Choukran in 2001 is a second generation platelet concentrate with affluence of growth factors. These growth factors have the ability to accelerate soft and hard tissue healing. PRF and its beneficial uses have been studied in the field of plastic surgical procedures, sinus lift procedures, multiple root coverage cases along with coronally positioned flap. PRF is superior to other platelet concentrates due to its ease of preparation, cost effectiveness and it needs no addition of any exogenous compounds. Earlier studies have shown decalcified freeze-dried bone allograft (DFDBA) has osteogenic potential, also PRF along with DFDBA has been successfully used in regeneration of intrabony defects. Hence the present study aimed to assess the additional benefit of using PRF along with DFDBA in the management of mandibular grade II furcation defects both clinically and radiographically.

Materials and Methods: Nine sites of nine patients with chronic periodontitis with mandibular grade II furcation defects with probing pocket depth of ≥ 5 mm and horizontal probing depth of ≥ 3 mm after scaling and root planing were selected for the study. Open flap debridement (OFD) done at the furcation sites, followed by placement with DFDBA and PRF. Clinical and radiographic parameters were measured at baseline and at 6 months postoperatively.

Result: The integrated use of PRF along with DFDBA in furcation defects showed better results in all clinical and radiographic parameters. The beneficial effects of PRF may be the reason for the effective results obtained in this study. When the graft particles mixed with PRF the PRF fragments serve as a biological connector between graft particles. Furthermore, the slow release of cytokines contribute a significant role in the self-regulation of inflammatory and infectious phenomena within the grafted material

Conclusion: It can be concluded that the combination of autologous PRF with DFDBA is an efficient treatment modality for the management of mandibular grade II furcation defects.

Keywords: Decalcified freeze- dried bone allograft, Furcation, Growth factors, Platelet-rich fibrin, Regeneration.

Introduction

Periodontitis is a “complex multifactorial disease, and a series of events including cell adhesion, migration, proliferation and differentiation are required for true periodontal regeneration.¹ Studies have shown that molars with furcation involvement, have a higher rate of periodontal breakdown and respond less favourably to periodontal therapy. This can be due to complex anatomic morphology of the furcation, that impedes accessibility for individual oral hygiene and also to professional root debridement.²

Reports in literature demonstrated periodontal regeneration with coronally positioned flaps,³ barrier membranes and biological agents. Even though these materials are used today, there has been increasing interest in polypeptide growth factors (PGF). PGF like Platelet derived growth factors (PDGF) and TGF- β were present in α granules of platelet and they have the potential to regulate cell proliferation, chemotaxis and differentiation.^{4,5} Platelet –rich fibrin (PRF) described by Choukroun et al in 2001, as a “second generation platelet concentrate which is pooled with platelets, growth factors, cytokines and glycoproteins, and they are the key factors for periodontal regeneration with added synergetic effect on the healing process of soft and hard tissue”.^{6,7}

Recent evidence has shown that viable growth factors in PRF can induce cell proliferation of osteoblast, periodontal ligament cells but it will suppress the oral epithelial cell migration, which is a key factor in periodontal regeneration.⁸ PRF has been proven to be beneficial in the field of plastic surgical procedures, sinus lift procedures and multiple root coverage cases.⁹ Also, PRF is superior to other platelet concentrates due to its ease of preparation, cost effectiveness and it needs no addition of any exogenous compounds like bovine thrombin and calcium chloride.

The osteogenic potential of decalcified freeze -dried bone allograft (DFDBA) was proposed by Urist et al.¹⁰ The demineralisation of graft exposes the bone morphogenetic proteins-2(BMP-2) and BMP-7, which were capable of inducing mesenchymal cells to differentiate into osteoblast,¹¹ also provides an osteoconductive surface for cell attachment.¹² A randomized clinical trial was conducted by Chadwick et al in the management of periodontal intrabony defects with a test treatment of platelet-rich fibrin compared to an active control treatment of demineralized freeze-dried bone allograft. The clinical or radiographic outcomes showed that both treatment modalities resulted in significant improvements in hard and soft tissue measurements.¹³

Many studies conducted to evaluate the efficacy of PRF and DFDBA in the treatment of intra bony defects. To the

best of our found knowledge there have been no studies to evaluate the collaborative effect of PRF and DFDBA in the management of mandibular grade -II furcation defect.

The clinical and radiographic changes of patients using decalcified freeze- dried bone allograft (DFDBA) and PRF in the buccal furcation defect were illustrated in this study.

Materials and Methods

The study was conducted at Department of Periodontology at Pushpagiri College of Dental Sciences and Research center, Thiruvalla, Kerala. Patients presenting with mandibular grade-II furcation defects, belonging to the age group of 35- 65 years were enrolled in this study. Ethical clearance for the study was obtained from the institutional ethical committee. No.PCDS/IEC/S19/12/14). and the study was conducted in accordance with the Helsinki Declaration of 1975, as revised in 2000. An explanation about the study was given to the patients, there after a written informed consent was obtained. This clinical trial was conducted in nine sites of nine chronic periodontitis patients with grade-II mandibular furcation defects with probing depth (PD) ≥ 5 mm and horizontal probing depth ≥ 3 mm after scaling and root planning. Only vital teeth were included in the study. Subjects with underlying systemic illness, those taking any drugs known to affect the outcome of periodontal therapy and drugs affecting platelets were excluded. Smokers, immune compromised individuals, pregnant or lactating subjects were excluded.

Presurgical Therapy

Phase-I therapy done, which includes full mouth scaling, root planning and selective occlusal grinding where ever indicated. Oral hygiene instructions were reinforced to the study group. For measurements of bone defects standardized technique with the help of position indicating device (RINN XCP system) and digital radiovisuography (Kodak RVG 5100), radiographs were taken.¹⁴ Clinical parameters were recorded at various time period ie, at base line, 4th week after phase-I therapy, 3 months and at the 6th month after intervention. (Fig. 1)

Radiographic Assessment

Radiographic evaluation of the defect was done at base line and 6 months postoperatively (Figure4). The radiolucent area below the furcation fornix was measured by a computer aided software programme (*Scion image, Frederick, MA*). [15,16]

PRF Preparation By Choukron¹⁷

A standard protocol of PRF preparation followed as proposed by Choukron. After getting the informed consent, from the antecubital vein a 10 ml of blood was drawn just before the surgery. The collected blood was immediately centrifuged at 3,000 rpm for 10 minutes. This resulted in 3 layers

1. Top most layer consists of acellular platelet poor plasma (PPP) as a supernatant

2. PRF clot in the middle layer
3. RBCs at the bottom.

The platelet poor plasma (PPP) was removed from the centrifugation tube. PRF was separated from the red corpuscles which were present at the base level using a sterile tweezers and scissors. After that it is transferred on to a sterile dappen dish. (Fig. 2)

Surgical Protocol

Intraoral and extraoral antiseptics were applied. After giving local anaesthesia, a crevicular incision was given using No: 15 blade. To expose the furcation defect a full thickness flap was reflected. Meticulous defect debridement was done using Quetin BL-1 furcation curette.

Following OFD half portion of PRF mixed with bone graft to obtain a homogenous mass to fill the furcation defect and the other half portion of PRF was used as a membrane, which was trimmed and placed over the defect filled with DFDBA (Rocky Mountain).¹⁸ Using 3-0 non-absorbable braided black silk surgical suture, mucoperiosteal flaps were repositioned and sutured. Non-eugenol periodontal dressing (Coe-pak) were also placed. (Figure3)

Post Operative Care

After the surgical procedure, the patients were prescribed with suitable antibiotics (amoxicillin 500 mg tid, 3 days), and non-steroidal anti-inflammatory drug (combiflam tid, 3 days). Chlorhexidine digluconate 0.2% rinse twice daily were also prescribed for two weeks. Periodontal dressings and sutures were removed seven days after surgery. Oral hygiene instructions were again reinforced.

Results

The sample size has been calculated as 9 sites using an α error of 5% and the power of the test as 80% at a confidence of 95%. The changes after 6 months as compared to base line data in both groups were tested using Friedman test. A p- value less than 0.05% was considered as statistically significant.

The study was done between the ages of 35-65 years with a mean of 55.78 ± 6.18 years. The materials used in the study were well-tolerated as there was no cases of post operative infection reported. Healing of all the sites were also uneventful, during the course of the study. The maintenance of oral hygiene was also satisfactory in all the patients. There was a statistically significant reduction in gingival index and plaque scores in the study groups from baseline to 6months. The mean reduction of the above parameters from baseline to 6 months was 1.997 ± 0.379 mm 2.11 ± 0.167 mm respectively. Figure5 and 6 shows gingival and plaque index from baseline to six months respectively. Table 1 and 2 shows descriptive statistics of gingival index and plaque index respectively.

In the study, there was greater reduction in probing pocket depth (PPD) of 2.45 ± 0.706 mm after 6 months also

the mean change in recession was 1.45 ± 0.059 mm. A gain of 2.941 ± 0.518 .mm RHCAL and gain of 4.00 ± 0.132 mm RVCAL was achieved in study group Table 3 and figure 7 shows changes in the clinical parameters over 6-month period.

With regard to mean alveolar bone defect fill, it was 1.21 ± 0.507 mm² and percentage of defect fill achieved was 58.76 ± 10.84 respectively. Table 4 and figure 8 shows comparison of mean alveolar bone defect (MABD) and mean change in millimeter at baseline and 6 months

Discussion

The ultimate goal of periodontal treatment is not only preventing the progression of periodontal disease, but also the regeneration of lost structures.¹⁹ When appropriate parameters are addressed, the survival rate and treatment outcome of furcation has been recognized as feasible and predictable.²⁰⁻²² DFDBA is widely used in periodontal regeneration, as it had been demonstrated to be safe and induces the host undifferentiated mesenchymal cells to differentiate into osteoblasts with subsequent new bone formation.²³ Some donor bone has shown no activity at all and had found to have act only as type –I collagen. These shortfalls lead to extend their search for another material with regenerative potential. Alpha(α) granules of platelet forms ample of growth factors including platelet-derived growth factor, transforming growth factor β (including β^1 and β^2 -isomers), vascular endothelial growth factor(VEGF), and epidermal and insulin-like growth factor-1(EGF,IGF).²⁴

PRF has a natural fibrin framework which can protect growth factors from proteolysis. The complex 3-D architecture helps to concentrates not only platelet but also leukocytes.²⁵ Another characteristic feature of PRF is, its simpler and less expensive nature to prepare, and also less risky to the patients. PRF resorbs gradually due to the dense fibrin matrix, so there is a sustained release of platelet and leukocyte derived growth factors into the wound area upto a period of ≥ 7 days.²⁶⁻²⁸

The gingival and plaque index showed statistically significant improvement from baseline to 6months in the study group. The mean reduction of gingival index from baseline to 6 months was 1.997 ± 0.379 mm and the mean reduction of plaque index from baseline to 6 months was 2.11 ± 0.167 mm. The patients in the study group exhibited good oral hygiene maintenance during the entire study period. The reason for this improvement was the result of repeated reinforcement of oral hygiene instructions. According to Macheti et al optimal plaque control has been considered to be a crucial factor in regenerative outcome and also plaque-infected teeth will lose attachment after any type of surgery.^{29, 30}

In this study a mean probing pocket depth reduction of 2.45 ± 0.706 mm occurred after 6 months. The results of the present study are in concordance with Chadwick et al.¹³ Bansal and Shah also demonstrated a significant reduction in probing depth from baseline to 6 months in their studies.^{31,32} The mean change in recession was $1.45 \pm$

0.059 mm. The fibrin matrix show mechanical properties and biologic functions like fibrin glues and maintains the flap in a high and stable position, enhances neoangiogenesis, reduces necrosis and shrinkage of the flap, and guarantees maximal root coverage. The reduction in gingival recession achieved in the study was better when compared with the study done by Chadwick et al 2016¹³

The RHCAL was measured using Nabers probe as suggested by Eickholz et al 1995.³³ A gain of 2.941 ± 0.518 .mm RHCAL and gain of 4.00 ± 0.132 mm RVCAL was achieved in study group. More favorable outcomes are expected in sites in which the interproximal bone height is coronal to the entrance of the furcation defect compared with those in which it is located at the same level or even more apical.

Radiographs were used in the present study to supplement the clinical findings. A definite increase in radio opacity was observed in the furcation areas at 6 months. Standardized IOPA of the sites were taken with the help of position indicating device (RINN- XCP system DENTSPLY, USA) and digital radiovisiography (Kodak RVG 5100). For radiographic assessment, a computer-aided software programme (Scion image, Frederick, MA) was used. The radiolucent area in the furcation was measured with the help of this software.³⁴⁻³⁷

In the present study, the mean bone defect fill was 1.21 ± 0.507 mm² and percentage of defect fill achieved was 58.76 ± 10.84 . The integrated use of PRF along with DFDBA showed better results in all clinical and radiographic parameters. The beneficial effects of PRF may be the reason for the effective results obtained in this study. When the graft particles mixed with PRF the PRF fragments serve as a biological connector between graft particles. Furthermore, the slow release of cytokines contribute a significant role in the self-regulation of inflammatory and infectious phenomena within the grafted material.³⁸

The result of present study yielded greater clinical and radiographic improvements. PRF and DFDBA had been shown to be an effective modality of therapy in the regenerative treatment of grade II furcations. The future long-term studies with larger sample size and utilization of advanced radiological techniques can be carried out to further explore the role of PRF in the management of furcation defects. A histomorphometric analysis could go a long way in assessing predictable periodontal regeneration.

Table 1: Descriptive Statistics of Gingival Index of Study Group

GI	Mean	SD	Mean Rank
GI [B]	2.200	0.734	4
GI [Ph-1]	1.289	0.513	3
GI[3 mo]	0.556	0.464	1.72
GI [6mo]	0.203	0.351	1.28

GI [B] Gingival index –Baseline, GI [Ph-1] Gingival index –After phase-I therapy, GI[3 mo]- Gingival index – After 3months, GI[6 mo]- Gingival index –After 6 months.

Table 2: Descriptive Statistics of Plaque Index of Study Group

PI	Mean	Std. Dev	Mean rank
PI[B]	2.78	0.667	3.83
PI[Ph-1]	2.11	0.601	3.17
PI[3 mon]	0.78	0.441	1.56
PI[6mon]	0.67	0.5	1.44

PI[B]- Plaque index at base line, PI[Ph-1]- Plaque index after phase-I therapy, PI[3 mon]- Plaque index after 3 months, PI[6 mon]- Plaque index after 6 months.

Table 3: Changes in the Clinical Parameters over 6-month Period

Periodontal parameters	Baseline Mean± SD	6 months Mean± SD	p value
PPD	4.78 ± 0.667	2.33 ± 0.707	0.001*
REC	3.67 ± 0.500	2.22 ± 0.441	0.001*
RHCAL	5.33± 1.118	2.389 ± 0.600	0.010*
RVCAL	8.44± 0.882	4.44 ± 1.014	0.006*

Friedman test was used for analysis. *P* value < 0.05 significant*

PPD- Probing pocket depth, Rec- Recession, RHCAL- Relative horizontal clinical attachment level, RVCAL- Relative vertical clinical attachment level, ABD- Alveolar bone defect.

Table 4: Comparison of Mean Alveolar Bone Defect (MABD) and Mean Change in mm at baseline, and 6 months

Mean alveolar bone defect (MABD)	Mean± SD
Baseline	2.13±1.243
6 Months	0.92 ± 0.736
Mean Change	1.21± 0.507
P Value	0.008*

Comparison done by Friedman test, *P* value < 0.05 significant

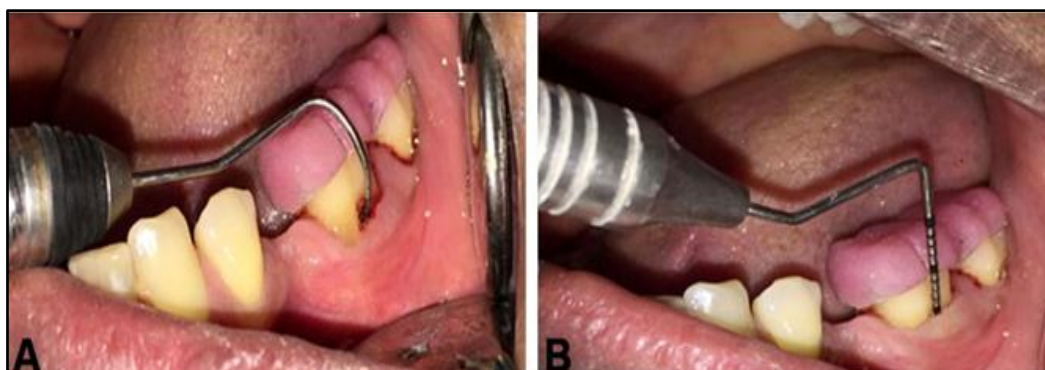


Fig. 1: Pre Operative measurement: A) Horizontal clinical attachment level with neber's Probe, B) Vertical Clinical attachments level with UNC-15 Probe

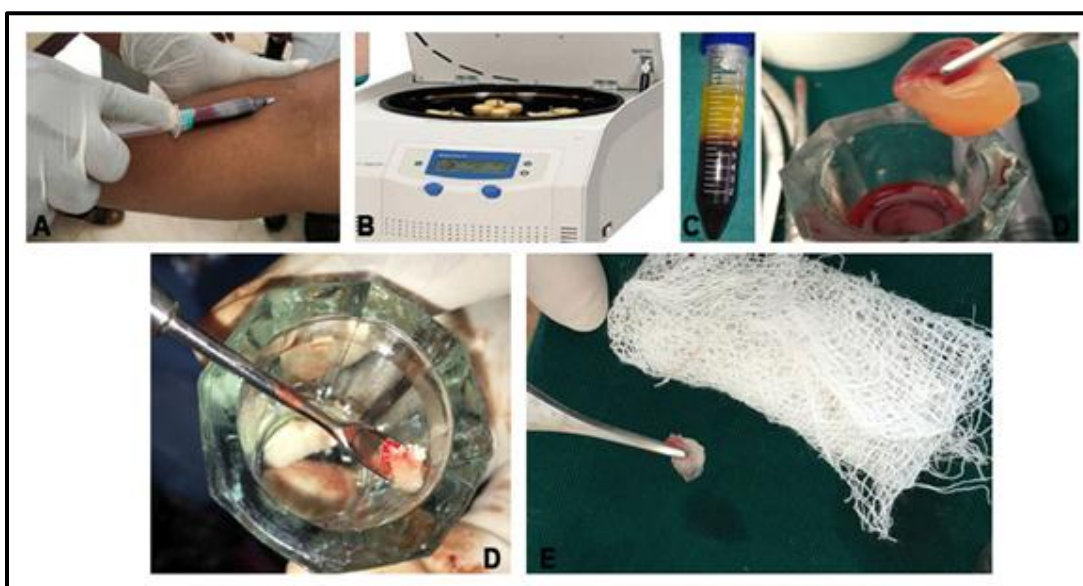


Fig. 2: Platelet-rich fibrin (PRF) preparation: A) Blood collection. B) Centrifuge machine. C) PRF obtained in the middle layer after centrifugation, D) Portion of PRF mixed with DFDBA. E) Preparation of PRF membrane.

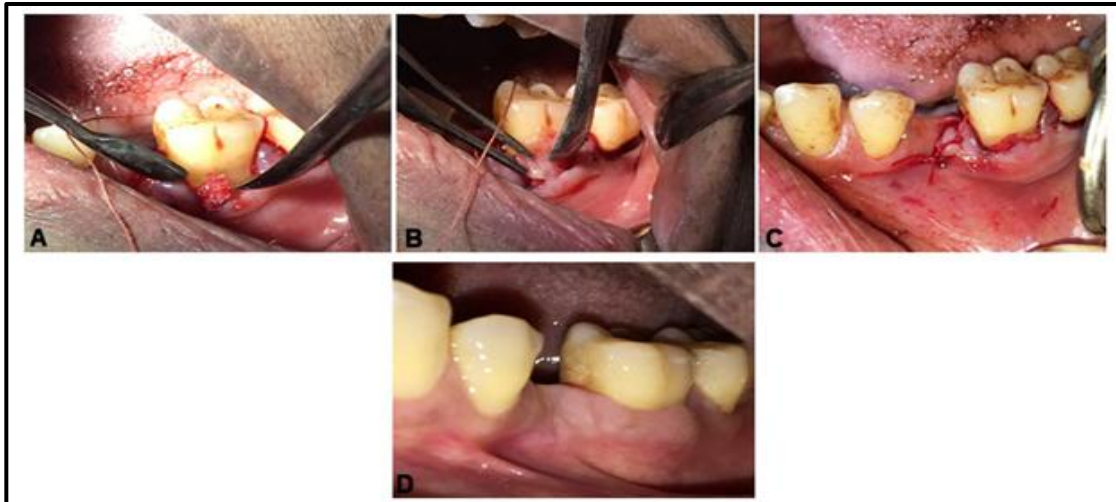


Fig. 3: A) Placement of DFDBA. B) PRF membrane placed over DFDBA. C) Sling-Sutures placed in operator site. D) Post-operative view.

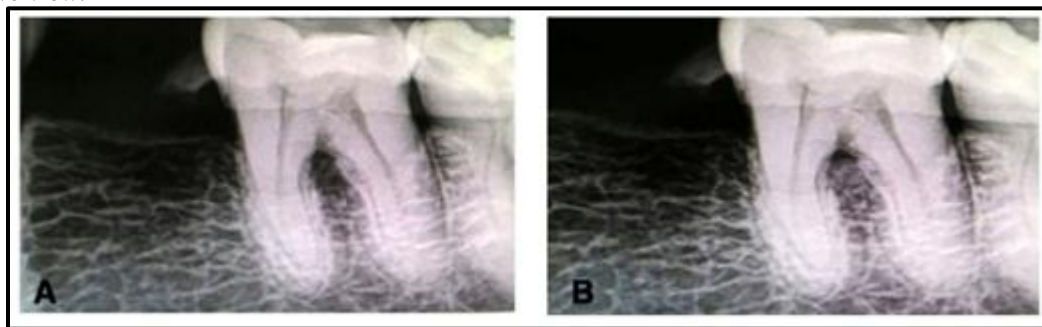


Fig. 4: Radiograph: A) Base line B) After 6 months

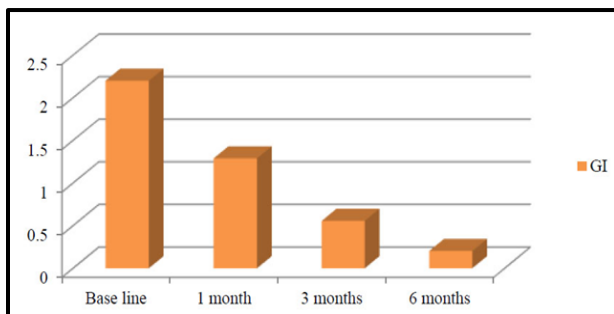


Fig. 5: Demonstrating Gingival index of study group from baseline to 6 months

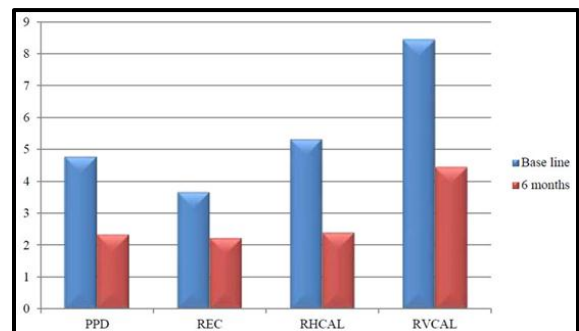


Fig. 7: Bar graph demonstrating changes in the clinical parameters over 6 months period

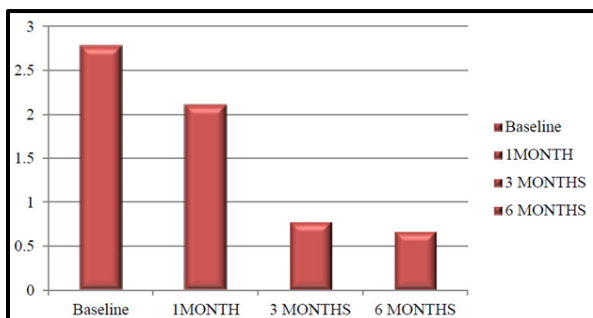


Fig. 6: Bar graph demonstrating plaque index from baseline to 6 months

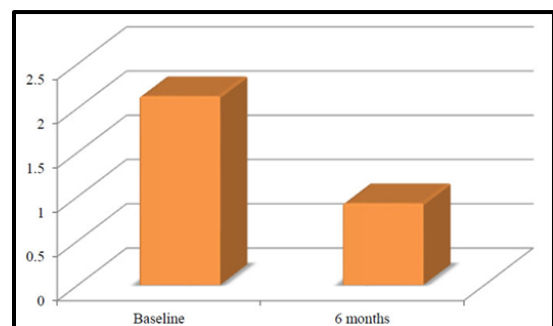


Fig. 8: Bar graph demonstrating variations in mean alveolar bone defect (ABD) change in mm² at baseline and 6 months

Conclusion

Management of furcation has always been a challenge. The results of the study showed significant closure of the furcation defects clinically as well as radiographically. Within the realms of possibility, it can be concluded that PRF along with DFDBA has been shown to be an effective treatment option in for mandibular grade II furcation defects. Utilization of PRF in the periodontal regeneration procedures would be cost effective and less technique sensitive treatment both for patients and dentist.

Conflict of Interest: None.

References

- Giannobile W. The potential role of growth and differentiation factors in periodontal regeneration. *J Periodontol* 1996;67:545-53.
- Lang N.P, Cumming B.R & Loe, H, Toothbrushing frequency as its relates to plaque development and gingival health. *Journal of Periodontology* 1973;44,396-05.
- Fuentes P, Garrett S, Nilveus R, Egelberg J. Treatment of periodontal furcation defects. Coronally positioned flap with or without citric acid root conditioning in class -II defects. *J Periodontol* 1993;20(6):425-30.
- Lekovic, V., Camargo, P. M., Weinlander, M., Vasilic, N., Aleksic, Z. & Kenney, Effectiveness of a combination of platelet-rich plasma, bovine porous bone mineral and guided tissue regeneration in the treatment of mandibular grade II molar furcations in humans. *J Clin Periodontol* 2003;30:746-51.
- Assoian, R. K., Grofendorst, G. R., Miller, D. M. & Sporn, M. B. Cellular transformation by coordinated action of three peptide growth factors from human platelets. *Nature* 1984; 309, 804-6.
- Choukroun, J, Adda F, Schoeffer.C and Vervelle, A. PRF: an opportunity in perio- implantology. *Implantodont* 2000;42:55-62
- Dohan DM, Choukran J, Diss A, Dohan SL, Dohan AJ, Mouhyil J, et al Platelet -rich fibrin (PRF): a second generation platelet concentrate. Part 11: Platelet related biologic features. *Oral Surg Oral Med Oral Pathol Oral Radiol Endod* 2006;101(3)e 45-50
- Tsai C H, Shen SY, Zhao, JH and Chang YC. Platelet-rich fibrin modulates cell proliferation of human periodontally related cells invitro. *J Dent Sci* 2009;4:130- 5
- Charrier JB, Monteil JP, Albert S, Collen S, Bobin S, Dohan Ehrenfest DM. Relevance of Choukran's PRF and SMAS flap in primary reconstruction after superficial or subtotal parotidectomy in patients with focal pleiomorphic adenoma: a new tec. *Rev Laryngol Otol R hinol* 2008;129(4-5)313-8.
- Urist MR: Bone formation by autoinduction, *sci*1965;150:893.
- Schwartz Z, Mellonig JT, Carnes DL, Jr de la Fontaine J. Ability of commercial Demineralized Freeze Dried Bone Allograft to induce new bone formation. *J Periodontol* 1996;67:918- 26
- Zhang M, Powers RM, Jr, Wolfenbarger L. A quantitative assessment of osteoconductivity of human demineralized bone matrix. *J Periodontol* 1997;68;1076- 84.
- Jane K Chadwick, Michael P Mills, Brian L.Mealey. Clinical and radiographic evaluation of demineralised freeze- dried bone allograft versus platelet-rich fibrin for the treatment of periodontal intrabony defects in humans. *J Periodontol* 2016; 87(11)1253-60.
- Person GR, Falk H, Laurell L. A retrospective radiographic outcome assessment study of intra-bony defects treated by osseous surgery or by bone graft procedure. *J Clin Periodontol* 2000;27:104-8
- Sharma A, Pradeep AR. Autologous platelet-rich fibrin in the treatment of mandibular degree II furcation defects: a randomized clinical trial. *J Periodontol* 2011;82:1396-03
- Bajaj P, Pradeep AR, Agarwal E et al. Comparative evaluation of autologous platelet-rich fibrin and platelet -rich plasma in the treatment of mandibular grade II furcation defects: A randomized controlled clinical trial. *J Periodontol Res* 2013;48:573-81.
- Choukroun J, Adda F, Schoeffer C, Vervelle A.PRF: an opportunity in perio-implantology. *Implantodontie* 2001;42:55-62
- Sharma A, Pradeep AR. Treatment of 3-wall intrabony defects in patients with chronic periodontitis with autologous platelet-rich fibrin: a randomized controlled clinical trial. *J Periodontol* 2011;82(12):1705-12.
- Kanakamedala A, Ari G, Sudhakar U, Vijaylakshmi R, Ramakrishnan T, Emmadi P. Treatment of a furcation defect with combination of PRF and bone grafts-a case report. *ENDO (Lond Engl)* 2009;3:127-35
- Jepsen S, Eberhard J, Herrera D, Needleman I. A systematic review of guided tissue regeneration for periodontal furcation defects. What is the effect of guided tissue regeneration compared with surgical debridement in the treatment of furcation defects? *J Clin Periodontol* 2002;29(3): 103-116;160-62.
- Murphy KG, Gunsolley JC. Guided tissue regeneration for the treatment of periodontal intrabony and furcation defects. A systematic review. *Ann Periodontol* 2003;8(1):266-302.
- Reynolds MA, Aiehelmann Reidy ME, Branch -Mayys GL, Gunsolley JC. The efficacy of bony replacement grafts in the treatment of periodontal osseous defects. A systematic Review. *Ann Periodontol* 2003;8(1):227-65.
- Gajiwala AL, Kumar BD, Chokhani P. Evaluation of demineralised, freeze-dried, irradiated bone allografts in the treatment of osseous defects in the oral cavity. *Cell Tissue Bank* 2007;8:23-30
- Toffler M, Toscano N, Holtzaw D, Corso MD, Ehrenfest DM. Introducing Choukroun's PRF to the reconstructive surgery millieu. *J Implant Adv Clin Dent* 2009;1:21-32
- Lundquist R, Dziegiel MH, Agren MS. Bioactivity and stability of endogenous fibrogenic factors in platelet-rich fibrin. *Wound Repair Regen* 2008;16:356-63.
- Dohan DM, Choukroun J, Diss A. Platelet-rich fibrin (PRF): a second-generation platelet concentrate. Part II: platelet related biologic features. *Oral Surg Oral Med Oral Pathol Oral Radiol Endod* 2006;101:E45e50.
- Dohan DM, Choukroun J, Diss A, et al. Platelet-rich fibrin (PRF): a second-generation platelet concentrate. Part III: leucocyte activation: a new feature for platelet concentrates? *Oral Surg Oral Med Oral Pathol Oral Radiol Endod* 2006;101:E51-55.
- Tsai CH, Shen SY, Zhao JH, Chang YC. Platelet-rich fibrin modulates cell proliferation of human periodontally related cells in vitro. *J Dent Sci* 2009;4:130e5
- Machtei EE, Cho MI, Dunford R, Norderyd J, Zambon JJ, Genco RJ. Clinical, microbiological, and histological factors which influence the success of regenerative periodontal therapy. *J Periodontol* 1994;65:154-61
- Machtei EE, Schallhorn RG. Successful regeneration of mandibular Class II furcation defects: An evidence-based treatment approach. *Int J Periodontics Restor Dent* 1995;15:146-67.
- Chhaya Bansal, Vipin Bharati, Evaluation Of Efficacy Of Autologous Platelet-Rich Fibrin With Demineralised -Freeze Dried Bone Allograft In The Treatment Of Periodontal Intrabony Defects. *J Indian Soc Periodontol* 2013;17;3:361-66.

32. Monali Shah, Jay Patel, Deepak Dave and Sujal Shah. Comparative evaluation of platelet-rich fibrin with demineralized freeze-dried bone allograft in periodontal infrabony defects: A randomized controlled clinical study. *J Indian Soc Periodontol* 2015;19(1):56–60.
33. Eickholz P. Reproducibility and validity of furcation measurements as related to class of furcation invasion. *J Periodontol* 1995;65:984-9.
34. Pradeep AR, Thorat MS, clinical effect of subgingivally delivered simvastatin in the treatment of patients with chronic periodontitis A randomized clinical trial. *J Periodontol* 2010;81:214-22.
35. Thorat M, Pradeep AR, Pallavi B. Clinical effect of autologous platelet-rich fibrin in the treatment of intra-bony defects: a controlled clinical trial. *J Clin Periodontol* 2011;38(10):925–32.
36. AR Pradeep, Kanika Nagapal, Shruti Karvekar, Platelet-Rich Fibrin with 1% metformin for the treatment of intrabony defects in chronic periodontitis: A Randomized Controlled Clinical Trial. *J Periodontol* 2015;86:729-37.
37. A.R Pradeep, Shruti Karvekar, Kanika Nagpal. Rosuvastatin 1.2 Mg In Situ Gel Combined With 1:1 Mixture Of Autologous Platelet- Rich Fibrin And Porous Hydroxyapatite Bone Graft In Surgical Treatment Of Mandibular Class II Furcation Defects: A Randomized Clinical Control Trial. *J Periodontol* 2016;87:5-13
38. Simonpieri A, Del Corso M, Sammartino G, Dohan Ehrenfest DM. The relevance of Choukroun's platelet-rich fibrin and metronidazole during complex maxillary rehabilitations using bone allograft. Part I: A new grafting protocol. *Implant Dent* 2009;18:102–11.

How to cite this article: Ittycheria PG, V TG, George AK, John S, George N, Evaluation of efficacy of autologous platelet-rich fibrin along with decalcified freeze dried bone allograft in the management of mandibular grade -II Furcation defects –A clinical and radiographic study.. *Int J Periodontol Implantol* 2019;4(1):11-17.