

Histopathology findings of chronic liver diseases in pediatric age group

Sachin Devidas Dhole¹, Manjusha Punjaji Tambse^{2,*}

^{1,2}Assistant Professor, ¹Dept. of Pediatrics, ²Dept. of Pathology, ¹ACPM Medical College, Dhule, ²Shri Bhausaheb Hire Government Medical College, Maharashtra, India

***Corresponding Author: Manjusha Punjaji Tambse**

Email: drmanjusha.tambse@gmail.com

Abstract

Objectives: Early and accurate diagnosis of Chronic liver diseases (CLD) in children is very important as it is associated with major cause of mortality and morbidity. Though, nowadays most advanced and ancillary diagnostic techniques are available, Liver biopsy still plays a very important role in diagnosis of chronic liver diseases in children. The present study is aimed to study the role of liver biopsy in diagnosis of various chronic liver diseases in children and to evaluate the histopathologic findings of various liver and hepatobiliary diseases in children.

Materials and Methods: This was a prospective study carried out in a large teaching hospital. Total 55 children in pediatric age group (1-12yrs) who presented with chronic liver disease were subjected to liver biopsy. Relevant investigations were done. The procedure was carried out under all aseptic condition after obtaining a written informed consent of the patient's parents. The liver biopsy procedure was done through two approaches one percutaneous and second is transjugular approach. The second approach was used in patients with deranged PT/PI, to avoid the risk of internal bleeding. The biopsy piece was collected in formalin and sent to histopathology for analysis. An expert pathologist was identified for the study of these biopsy pieces. The biopsy findings were evaluated.

Results: In our study the incidence of CLD was high in 6-12 yr of age group (34.34%) with a male predominance (60%). In our study the most common presenting complaint was jaundice and abdominal distension (38.18%) followed by jaundice alone (34.54%). Liver biopsy demonstrated various histopathological abnormalities like inflammation (80%) followed by ballooning of hepatocytes (74.54%). Other findings included cholestasis/necrosis/fibrosis/glycogenation/special stains positivity/cirrhosis. The incidence of cirrhosis on liver biopsy was 41.81%. We diagnosed maximum cases of Wilson's disease 12 out of which 9 patients had cirrhosis. In our study maximum (18) patients out of 55 had metabolic liver disease, followed by hepatitis (9).

Conclusion: As incidence of Chronic Liver Diseases is very low in pediatric age group a very high index of suspicion is required. Every case needs through history and investigations to reach at a specific diagnosis. Liver biopsy is gold standard and plays a very important and crucial role in the diagnosis of chronic liver diseases in children.

Keywords: Cirrhosis, CLD, Liver biopsy, Metabolic liver diseases, Wilson's disease.

Introduction

Early and accurate diagnosis of chronic liver diseases in pediatric age group is utmost important as it is associated with major cause of morbidity and mortality in children. Chronic liver disease (CLD) implies a long standing irreversible change in hepatic structure which may end in complications like cirrhosis leading to premature death. Duration of more than six months to define CLD is often misleading and not applicable to a majority of cases.¹ In this advanced era of ancillary diagnostic modalities like biochemical investigations, serological markers, radiological studies and molecular studies liver biopsy still plays an important role in accurate diagnosis especially in evaluating the response to treatment, to gauge disease severity and to assess the prognosis.² It is considered as gold standard for diagnosis and determining disease severity and prognosis.² Liver biopsy plays vital role in the precise diagnosis in cases of hepatosplenomegaly, cholestatic jaundice, PUO, neoplastic and metabolic disorders.

Spectrum of chronic liver diseases includes infections, developmental abnormalities, metabolic liver disorders and cirrhosis.³ Early recognition of CLD is important so as to avoid the subsequent delay in the initiation of effective therapies. It is important to differentiate idiopathic neonatal hepatitis from biliary atresia in an infant presenting with

cholestasis as the former can be managed medically and in the later only early surgical intervention can save life.⁴

The technique of liver biopsy was first introduced by Paul Ehrlich in 1983 to study the glycogen content of diabetic liver.⁵ Later Menghini in 1958 made the technique quicker and easier by introducing 1.4mm diameter liver biopsy needle.⁶ Nowadays three types of needles are available for liver biopsy i.e. Trucut, Menghini and Vim-Silverman or Jamshidi.⁷

Liver biopsy can be done using two approaches. One is percutaneous which is very commonly used and second is transjugular approach which is used in case of grossly deranged liver function where percutaneous approach has danger of bleeding. A satisfactory biopsy tissue is 1-4cm long and 10-50mg in weight.

Uses of liver biopsy are ⁸

1. To provide precise histology diagnosis.
2. For enzyme analysis to detect inborn errors of metabolism
3. For analysis of stored material such as iron, copper or specific metabolites.
4. To monitor responses to therapy.
5. To detect complications of treatment with potentially hepatotoxic drugs.

Liver biopsy can yield sufficient tissue representative of diffuse process involving the liver with minimum risk to patient but the focal lesions can be missed with this technique. But if a focal lesion is suspected it can be targeted by Ultrasonography guided technique. To maximize the outcome, adequate sample length and appropriate correlation of hepatic morphology and clinical history is required.^{9,10}

Aims and objectives

1. To study the role of liver biopsy in diagnosis of various chronic liver diseases in children.
2. To evaluate the histopathologic findings of various liver and hepatobiliary diseases in children.

Materials and Methods

This was a prospective study carried out in a large teaching hospital. Total 55 children in the age group of 1-12yrs who presented with chronic liver disease comprised the study group. All the 55 children underwent liver biopsy. Total duration of study was 28 months. We included the cases admitted in pediatric wards for work up of chronic liver disease.

First the detailed clinical history of the presenting complaints of all the patients was noted in a predesigned proforma. After a detailed history, height, weight, vital parameters and general examination of the patients was done. Relevant biochemical and hematological investigations were done. Serological markers and special investigations if needed were done. Radiological investigations were done wherever necessary.

Liver biopsy

Liver biopsy was done in patients where the above tests did not enable us to arrive us at a conclusive diagnosis. The procedure was done only after fulfillment of prerequisite protocols for liver biopsy. They included normal prothrombin time (PT) and prothrombin index (PI) or near normal of both, normal platelet count and normal bleeding time, clotting time. In difficult cases where the liver was shrunken the procedure was done under USG guidance. The procedure was carried out under all aseptic condition after obtaining a written informed consent of the patient's

Table 3: Presenting complaints in this series:

S. No	Presenting complaints	No. of patients	%	Outcome	
				Death	Survived
1.	Jaundice and abd. Distension	21	38.18	13	8
2.	Jaundice	19	34.54	4	15
3.	Abd. Distension	7	12.72	0	7
4.	Neurological symptom	5	9.09	1	4
5.	Bleeding	2	3.63	-	2
6.	Asymptomatic	2	3.63	-	2
	Total	55		18	37

parents. The liver biopsy procedure was done only on indoor patients. The procedure was done through two approaches one percutaneous and second is transjugular approach. The second approach was used in patients with deranged PT/PI, to avoid the risk of internal bleeding.

The procedure was done by an expert pediatrician using Trucut liver biopsy needle which is easily available. Pressure was applied on the prick site to reduce bleeding. The biopsy piece was collected in formalin and sent to histopathology for analysis. An expert pathologist was identified for the study of these biopsy pieces. Various routine stains and special stains like PAS, orcein were used for study. For patients in whom ante mortem liver biopsy was not possible due to deranged PT/PI or where the patient expired before biopsy could be done, postmortem liver biopsy was performed for the diagnosis.

Results

Table 1: The incidence of chronic liver disease according to age (N=55):

S. No	Age group in yrs	No. of cases	%
1.	0-1	13	23.63
2.	1-3	7	12.72
3.	3-6	16	29.09
4.	6-12	19	34.54

In our study of 55 case the incidence of CLD was high in 6-12 yr of age group (34.34%) followed by 3-6yr age group (29.09%). Least incidence was seen in 1-3yr age group (12.72%).

Table 2: Incidence of chronic liver diseases according to sex:

Sex	No. of cases	%
Male	33	60
Female	22	40

In our study incidence of CLD was predominantly high in males, 33 patients (60%) as compared to females, 22 patients (40%).

In this study most common presenting complaints was jaundice and abdominal distension observed in 21 patients (38.18%) followed by jaundice alone in 9 patients (34.54%). The outcome was poor and death rate was very high in patients presented with jaundice and abdominal distension, 13 patients expired out of 18.

Table 4: Various histopathological features seen in Liver Biopsy:

S. No	Histopathological abnormality	No. of patients	%
1.	Abnormal liver architecture	32	58.18
2.	Ballooning of hepatocytes	41	74.54
3.	Cholestasis- canalicular/ intrahepatic	27	49.09
4.	Inflammation-mononuclear/mixed	44	80
5.	Necrosis-focal/piecemeal/massive	15	27.27
6.	Fibrosis- periportal/bridging	40	72.72
7.	Glycogenation of hepatocytes	15	27.27
8.	Special stain positive- (reticulin/orcein/PB/PAS/D)	13	23.63
9.	Cirrhosis	23	41.81

PB- Prussian Blue

PAS- Periodic Acid Schiff

D- diastase

Liver biopsy demonstrated various histopathological abnormalities like inflammation either mononuclear or with neutrophils in 44 patients (80%) followed by ballooning of hepatocytes in 41 patients (74.54%). Other findings included cholestasis/necrosis/fibrosis/glycogenation/special stains positivity/cirrhosis.

Table 5: Incidence of cirrhosis on liver biopsy:

S. No.	Liver biopsy in CLD	No. of patients	% of patients	Death	% of death
1.	Cirrhosis on biopsy	23	41.81	13	56.52
2.	No cirrhosis on biopsy	32	58.19	5	15.62
	Total	55	100	18	

On liver biopsy cirrhosis was seen in 23 patients (41.81%) and no features of cirrhosis in 32 patients (58.19%). Outcome in patients with cirrhosis on biopsy was poor with death in 13 patients (56.52%) and in non- cirrhosis features it was better as compared cirrhosis on biopsy, 5 deaths (15.62%).

Table 6: Interpretation of liver biopsy:

S. No.	Biopsy	Cirrhosis	Non cirrhosis	Total
1.	Hepatitis	-	9	9
2.	Autoimmune hepatitis	3	3	6
3.	Wilson's disease	9	3	12
4.	Alpha1 Antitripsin deficiency	2	-	2
5.	GSD	1	1	2
6.	NLSD	-	2	2
7.	CMV/Toxo. hepatitis	-	4	4
8.	EHBA	3	1	4
9.	Neonatal hepatitis	3	2	5
10.	Tuberculosis	-	4	4
11.	Miscellaneous-EHBO Lupus hepatitis	1 1	1 Sclerosing cholast 1 BCS 1Normal	5
	Total	23	32	55

EHBA- Extra hepatic Biliary Atresia

GSD- Glycogen Storage disease

NLSD- Neutral Lipid Storage disorder

EHBO- Extra hepatic Biliary obstruction

BCS- Budd chiari Syndrome

We had maximum cases of Wilson's disease 12 out of which 9 patients had cirrhosis.

Table 7: Spectrum of chronic liver disease

S. No	System involved	No. of cases	%
1.	Metabolic liver disease	18	32.72
2.	Autoimmune hepatitis	6	10.90
3.	Hepatitis	9	16.36
4.	Neonatal hepatitis	5	9.09
5.	Tuberculosis	4	7.27
6.	TORCH hepatitis	4	7.27
7.	EHBA	4	7.27
8.	Miscellaneous	5	9.09
	Total	55	100

In our study of 55 patients with chronic liver diseases maximum (18) patients had metabolic liver disease, followed by hepatitis (9).

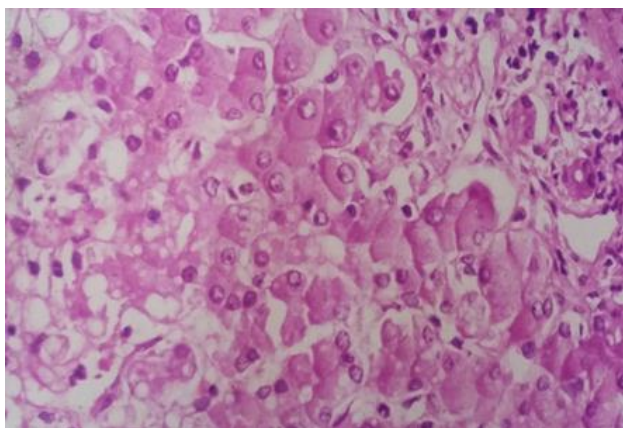


Fig. 1: Wilson's Disease-photomicrograph showing ballooning of hepatocytes, cholestasis, micro vesicular fatty change, periportal inflammation, duct proliferation.

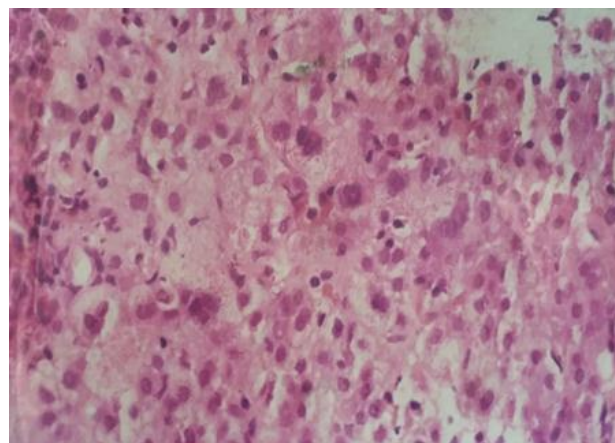


Fig. 3: Neonatal Hepatitis- photomicrograph shows prominent giant cell transformation, lobular inflammation, extramedullary erythropoiesis

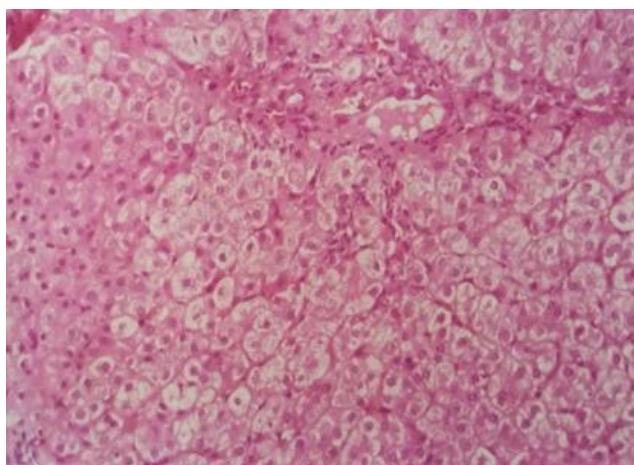


Fig. 2: Alagille Syndrome: Photomicrograph shows near absence of bile ductules in interlobular septae, pseudoxanthomatous transformation of hepatocytes.

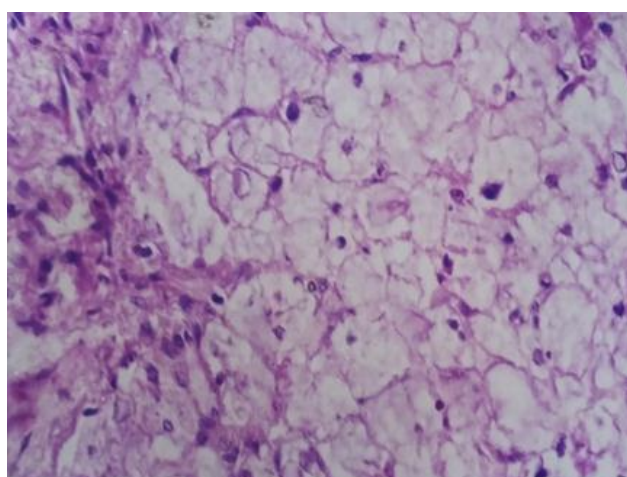


Fig. 4: Glycogen storage disease (Type4) - photomicrograph shows loss of normal architecture, hepatocytes severely distended with granular cytoplasm and glycogenated nuclei

Discussion

In our study the incidence of CLD was 1% of total admissions in the pediatric ward (55 out of 5146). The study shows that CLD is not the major disease in children. It is quite rare as compared to other pediatric disease for e.g. Respiratory infections. So for considering and diagnosing the child with CLD, a very high index of suspicion is required.

There was seen a male predominance in our study (60%) which is correlating with the studies done by Qureshi¹¹ and Mehnaz¹² et al. The most common presenting complaint as noted by us was jaundice and abdominal distension (38.18%), followed by jaundice alone (34.45%). Therefore a total of 40 patients (72.72%) had jaundice. Similar findings were observed by Qureshi¹¹ and Malik¹³ et al. There are a few patients of CLD who may not present with jaundice, 15(27.28%) of 55 cases did not have jaundice. A study done at AIIMS in which 25% of total 200 children enrolled in the study did not have jaundice¹⁴. Therefore if jaundice is absent one should not miss the diagnosis of CLD.

Liver biopsy is diagnostic with special stains for fat. We had two cases of neutral lipid storage disease. Both the biopsy revealed that the cytoplasm and nuclei were distended with striking number of large lipid droplets. Liver histology was studied in 55 patients, of which 16 were postmortem samples. These patients could not undergo a biopsy earlier due to excessive bleeding tendency or poor general condition. The various histopathological changes are shown in results (table IV). They included destroyed liver architecture, ballooning of hepatocytes, fatty change, inflammation, fibrosis, necrosis, giant cell transformation, sinusoidal dilatation, bile duct proliferation with or without bile duct cholestasis, Kupfer cell hyperplasia, cirrhosis, deposition of glycogen, special stains giving positive findings and interlobular bile duct paucity. In some patients stains like orcein and PAS were used. The commonest finding was inflammation and infiltration of mononuclear cells. This may be seen alone or may accompany necrotic and degenerative parenchymal changes. Ballooning of hepatocytes denotes hydropic degeneration and is a sign of liver dysfunction. This change is reversible. Fatty change occurs due to large cytoplasmic droplets of fat and displacement of cell nuclei.

Hyaline degeneration and Mallory bodies were seen in 2 patients. Necrosis can be focal, bridging, piecemeal or massive. Focal necrosis is also called a pinpoint necrosis and can occur in any type of liver injury. Piecemeal necrosis occurs when there is loss of cells in the limiting plate and adjacent parenchyma in the periportal zone. This is a slow continuous process associated with chronic hepatitis especially autoimmune hepatitis¹⁵. It was seen in 3 of the 6 patients with autoimmune hepatitis. Massive or submassive necrosis involves large areas and is an extreme form associated with fulminant hepatic failure and poor outcome. Patients with resolving hepatitis have mild changes in biopsy and the liver architecture was maintained. Patients who were less than one year (disease was not long standing)

had fairly maintained liver architecture. Patients with destruction of liver architecture had poor outcome. Hepatic fibrosis was differentiated from true cirrhosis by persistence of recognizable normal lobular pattern. Thus fibrosis was a component of chronic active inflammation. Bile duct proliferation was seen in patients with obstruction. E.g. EHBA.

Nayak and Nandini¹⁶ have given comparative evaluation of important histological parameters in biliary atresia and neonatal hepatitis. A definitive diagnosis of biliary atresia and neonatal hepatitis is rather difficult on histology. The authors say that ductal proliferation, ductular bile plug and fibrosis are present more often in biliary atresia. Whereas inflammation, hemopoiesis is more commonly associated with idiopathic neonatal hepatitis. Giant cells could be seen in both conditions. Bile lakes and bile duct thrombi favor diagnosis of extra hepatic Biliary Atresia (EHBA). In our study it was found in all cases of EHBA. Cirrhosis was diagnosed in biopsy when there was loss of normal architecture, nodular parenchyma with fibrous septae separating the nodules. The changes were seen in 23 out of 55(41.81%). In our study the outcome of these patients was poor. Interlobular duct paucity was seen in 2 patients. Bile duct paucity was associated with vascular degeneration. Extramedullary hematopoiesis was seen in 3 patients with hepatitis due to TORCH infection. Epithelioid cells were observed in 4 patients with tuberculous granulomas in liver. In the 2 cases with glycogen storage, ballooning of cytoplasm with granular appearance was noted. The liver tissue in these patients was collected in formalin and alcohol. The biopsy was subjected to PAS staining and diastase solubility. These 2 patients were categorized as GSD type III after analyzing their other biochemical investigations like glucose tolerance test. Patients with Wilson's disease showed a variety of changes and 8 patients had positive orcein stain. Positive PAS staining granules were detected in 2 patients both of whom had alpha 1 antitrypsin (ATT) deficiency.

There is no identical study available in liver histology in pediatric chronic liver diseases. The largest study to analyze chronic liver disease in children was performed by Yachha et al¹⁷ where 235 children were studied. In that study also all the children were not subjected to biopsy.

We did not encounter any complication after liver biopsy as it was done in patients with normal PT/PI with standard protocol for liver biopsy¹⁸. Of the 55 patients in our study, with chronic liver disease 18 patients expired. Thus giving mortality rate at 32.72%

Conclusion

As the incidence of chronic liver disease in children is less as compared to other diseases, therefore for the diagnosis of CLD in children a very high index of suspicion is required. The patients of chronic liver diseases should be thoroughly investigated without wasting much time. A biopsy must be performed in every case and strict follow up should be maintained. Liver biopsy is a gold standard in the diagnosis of chronic liver diseases.

Acknowledgements

We are thankful to all the ward staff and technicians in histopathology section for their help.

Conflicts of Interest: None.

References

1. N.K. Arora, R. Lodha, P. Mathur, N. Arora: Child with Chronic Liver Disease, *Pediatr Today* 1998;1(2):207-211.
2. Ovchinsky N, Moreira RK, Lefkowitz JH, Lavine JE. The Liver Biopsy in Modern Clinical Practice: A Pediatric Point-of-View. *Adv Anat Pathol* 2012;19:250-62.
3. Monajemzadeh M, Tabriz HM, Fallahi G, Farahmand F. Liver Needle biopsy in Iranian pediatric patients: Diagnostic significance and pattern of liver diseases. *Indian J Pathol Microbiol* 2009;52(1):10.
4. Dehghani SM, Heghighat M, Imanieh MH, Germizadeh B. Comparison of different diagnostic methods in infants with Cholestasis. *World J Gastroenterol* 2006;(12):5893-6.
5. Sherlock S, Dooley J. Biopsy of the liver. In: Diseases of the liver and biliary system. 10th ed. Oxford: Blackwell Science, 1997;33-42.
6. Menghini G. One-second needle biopsy of the liver. *Gastroenterology* 1958; 35:190-99.
7. Arturo Bravo, Sunil Sheth, Sanjiv Chopra: Liver Biopsy, *Engl J Med* 2001;344:495-500.
8. Vicky Lee and Ballistreri: Manifestations of Liver Disease. Section 6, The Liver and Biliary System, in Nelson's Textbook of Pediatrics, 17th Edition Behrman, Kliegman, Jenson, International Edition, 2004, Saunders, Ch. 336: 1308-1312
9. Czaja AJ, Carpenter HA. Optimizing diagnosis from the medical liver biopsy. *Clin Gastroenterol Hepatol* 2007;5:898-07.
10. Karim B, Rehman M. Safety of blind liver biopsy. *Indian J Pediatr* 2004;71: 899-901
11. H. Qureshi, M Hanif, J. Raza, Z. Issani: Etiology of Chronic Liver Disease in Children. *J Pak Med Assoc* 2004;54(3):119-22.
12. MehnazA: Chronic Liver Disease in Children An overview, *Med Spect* 1999;20:7-11
13. M. Malik, W. Hussain, M Aslam, S. Magbool: Clinical Spectrum of Chronic Liver Disease in Pakistani Hospitalised Children. *Pak Ped J* 2000;(24):9-12
14. N.K. Arora, R. Lodha, P. Mathur, N. Arora: Child with Chronic Liver Diseases, *Pediatr Today* 1998;1(2):207-11.
15. R.S. Patrick and J. McGee: Clinicopathological Correlations of Liver Biopsy. In "Biopsy Pathology of the Liver", Chapman and Hall, 1980Ch-13:318-322.
16. N.C.Nayak, Nandini Vasdev: Neonatal Cholestasis Syndrome, Identifying the Disease from Liver Biopsy. *Ind Pediatr* 2002;39(5):421-24.
17. S. K. Yachha, B. C. Sharma, A. Khanduri, A. Srivastava: Current Spectrum of Hepatobiliary Disorders in Northern India. *Ind Pediatr* 1997;34(10):885-9.
18. Deirdre A. Kelly: Liver Biopsy Protocol, Useful Investigations in the Assessment of Liver Disease, Section-1, Investigating the Liver, In Diseases of the Liver and Biliary System in Children, Kelly, 1999, Blackwell Science. Ch. 1: 7.

How to cite this article: Dhole SD, Tambse MP, Histopathology findings of chronic liver diseases in pediatric age group. *Int J Med Paediatr Oncol* 2019;5(1):31-36.