

## Case report of an acute presentation of diplegia in a four-month old - to expect the unexpected!

Pearl Mary Varughese<sup>1,\*</sup>, Sathesh Ponnarmani<sup>2</sup>

<sup>1</sup>MBBS, MD Pediatrics, <sup>2</sup>MD DM (Pediatric Critical Care), <sup>1,2</sup>Dept. of Pediatrics, <sup>1,2</sup>Pondicherry Institute of Medical Sciences, Pondicherry, India

**\*Corresponding Author: Pearl Mary Varughese**

Email: [pearlmaryvar@gmail.com](mailto:pearlmaryvar@gmail.com)

### Abstract

Spinal tumors are rare in infancy. Among them, atypical teratoid/rhabdoid tumor of the spine is an even more rare pediatric neoplasm with grave prognosis. Here we present a case of atypical teratoid/rhabdoid tumor (ATRT) of the lumbar spine in a four months old male who presented with acute onset of lower limb weakness. Magnetic resonance imaging of the spinal cord revealed a highly cellular intradural intramedullary embryonal tumour from D8-L4. Immunohistochemically, integrase inhibitor 1 (INI-1) stain show loss of expression. Despite surgical resection, the infant presented with new metastatic lesions and hydrocephalus. Ventriculo-peritoneal shunt was placed and the prognosis was explained to the parents.

**Keywords:** Intramedullary, Rhabdoid tumor, Hydrocephalous.

### Introduction

Spinal cord tumors in pediatric population is rare, representing less than 1% of all central nervous system tumors.<sup>1</sup> Among spinal tumours, atypical teratoid/rhabdoid tumor is a highly malignant tumor and can occur in various other anatomic sites, such as the liver, abdomen, kidney or soft tissues.<sup>2</sup> It was first described in 1978 as a variant of Wilms tumor with rhabdomyosarcomatous features and was recognized as a separate tumor entity by the World Health Organization only in 1993.<sup>3,4</sup> The prognosis is bleak with a median survival being 6 months even with optimum surgical and medical treatment.<sup>5</sup>

Till some years back, ATRT was frequently misdiagnosed as primitive neuroectodermal tumor (PNET) due to their histological and radiological resemblance.<sup>6</sup> Thus confirmation of the diagnosis of AT/RT is important because the tumors typically have a poorer prognosis and require intensive therapy that differs markedly from the treatment for PNET/MB.<sup>5,7</sup> Though now, immunohistochemical analysis has made the diagnosis possible, the standard treatment still remains a controversy.<sup>8,9</sup>

Although there is sufficient literature on brain AT/RT, spinal AT/RT continues to be a rare entity with lumbar location even less frequently reported.<sup>10,11</sup> Here a case of a four months old male infant with primary spinal AT/RT is being reported and we review the literature with regard to the pathology, treatment and outcome of this rare entity

### Case Report

4 months old male child was brought by his parents with complaints of irritability with frequent passing of urine for 3 days. Three days later, it was noticed that there was paucity of movements in the lower limbs. He had an episode of acute gastroenteritis with no dehydration 10 days back, for which he was admitted in our hospital for two days and was treated by plan A correction. The parents had not noticed any irritability or weakness before this incident.

There was no history of fever, ruling out infectious etiology. There was no history of any feeding difficulties, respiratory complaints and upper limb weakness, thus ruling out bulbar palsy, respiratory muscles and upper limbs involvement. There was no history of any recent intramuscular vaccination. Birth history and developmental history was normal. Family history was not significant.

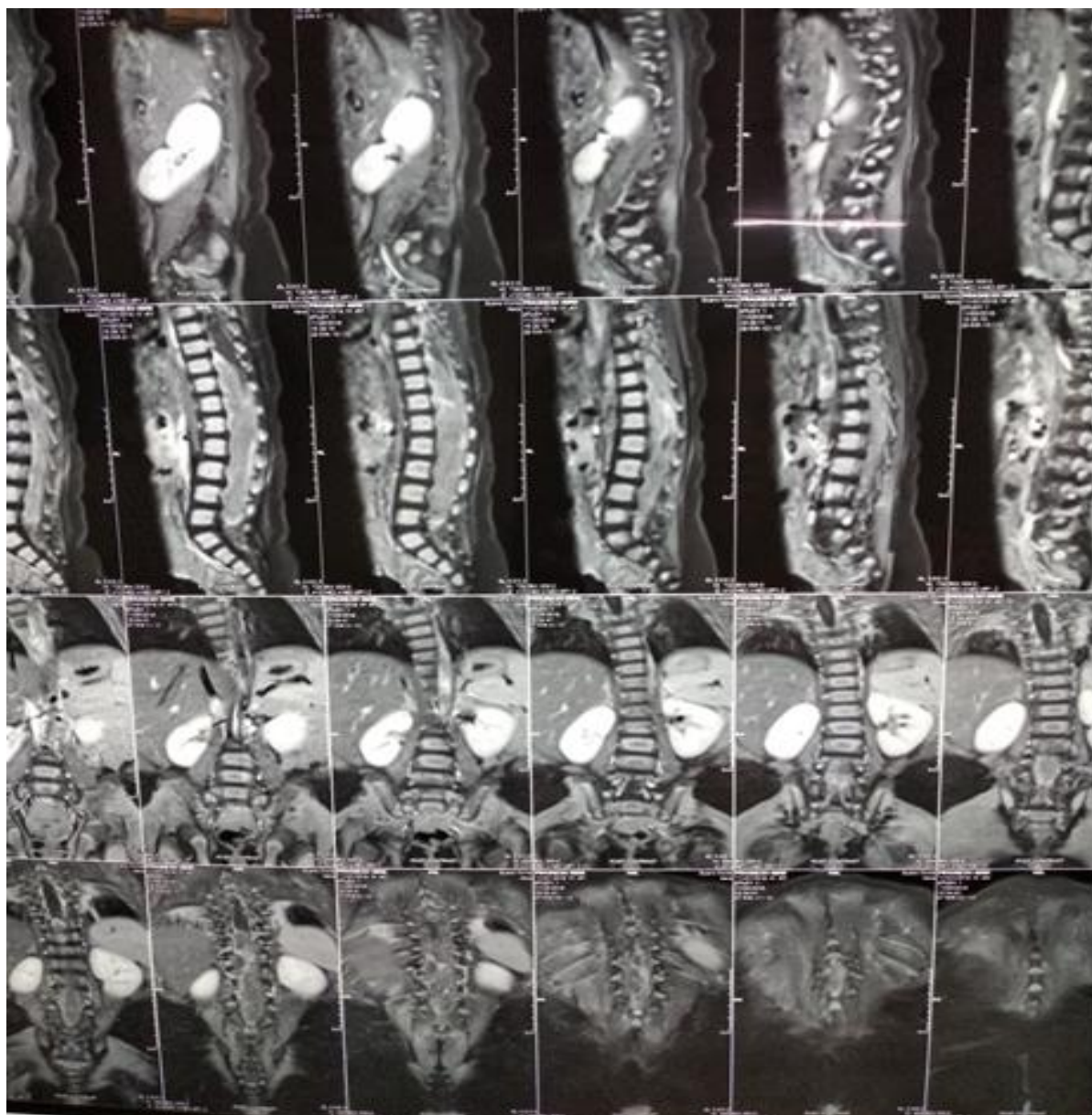On examination, the child was found to be irritable, but consolable. All the growth parameters were normal for age (weight 8kg, length 70cm and head circumference 41cm). The vitals were stable. There were no neuro-cutaneous markers. The head was atraumatic and normocephalic, and extraocular movements were intact, pupils were equal, round, and reactive to light and accommodation. There was no significant lymphadenopathy or hepatosplenomegaly and other systemic examinations were normal. Neurologically, cranial nerves were intact. The upper limbs had power 5/5 with intact reflexes while lower limbs had power 0/5, with absent knee, ankle and plantar reflexes. The sensations were intact in the lower limbs. Abdominal reflex and bulbocavernosus reflexes were absent too. There was no bony tenderness or deformities on palpation of the long bones.

The blood parameters with complete blood count, CRP, ESR, liver profile, renal function tests, electrolytes, Creatinine kinase-MB levels were found to be within normal limits. A lumbar puncture performed after consent was obtained from the parents and the results were normal. Blood, urine and CSF cultures were negative. MRI spine showed a partly well-defined T1 isointense and T2 hyperintense intramedullary lesion extending from upper body of D9 to upper border of L4 showing homogenous enhancement on post contrast study. There was expansion of the spinal cord with scalloping of the vertebral bodies. Chances of transverse myelitis / space occupying lesion were considered as the probable diagnosis. Cranial MRI was normal and showed no metastasis. MR spectroscopy was done which showed a large lipid lactate peak and high

choline levels. Metastasis was ruled out by chest and abdomen imaging. 24 hours urinary vanillylmandelic acid (VMA) levels were also within normal limits ruling out neuroblastoma

He was initially started on broad-spectrum intravenous antibiotics due to the possibility of abscess. He was monitored for progression of the weakness. An initial course of intravenous dexamethasone was given for 5 days to see if the tumour regressed. As there was no improvement, D7-S1 laminotomy was done and tumor excised on 10<sup>th</sup> day of

hospitalization. Intra operative neuro-monitoring showed only 40-50% Compound muscle action potentials (CMAPs) in both the nerve to quadriceps (L2, 3, 4) and the nerve to sphincter were anatomically preserved. There was tumour infiltration into the adjacent nerves and the conus seen. The post-operative period was uneventful, intravenous antibiotics were continued for 5 days. He was catheterized and discharged on oral antibiotics on day 22 of hospitalization



**Fig. 1:** MRI spine showed a partly well-defined T1 isointense and T2 hyperintense intramedullary lesion extending from upper body of D9 to upper border of L4 showing homogenous enhancement on post contrast study. There was expansion of the spinal cord with scalloping of the vertebral bodies.

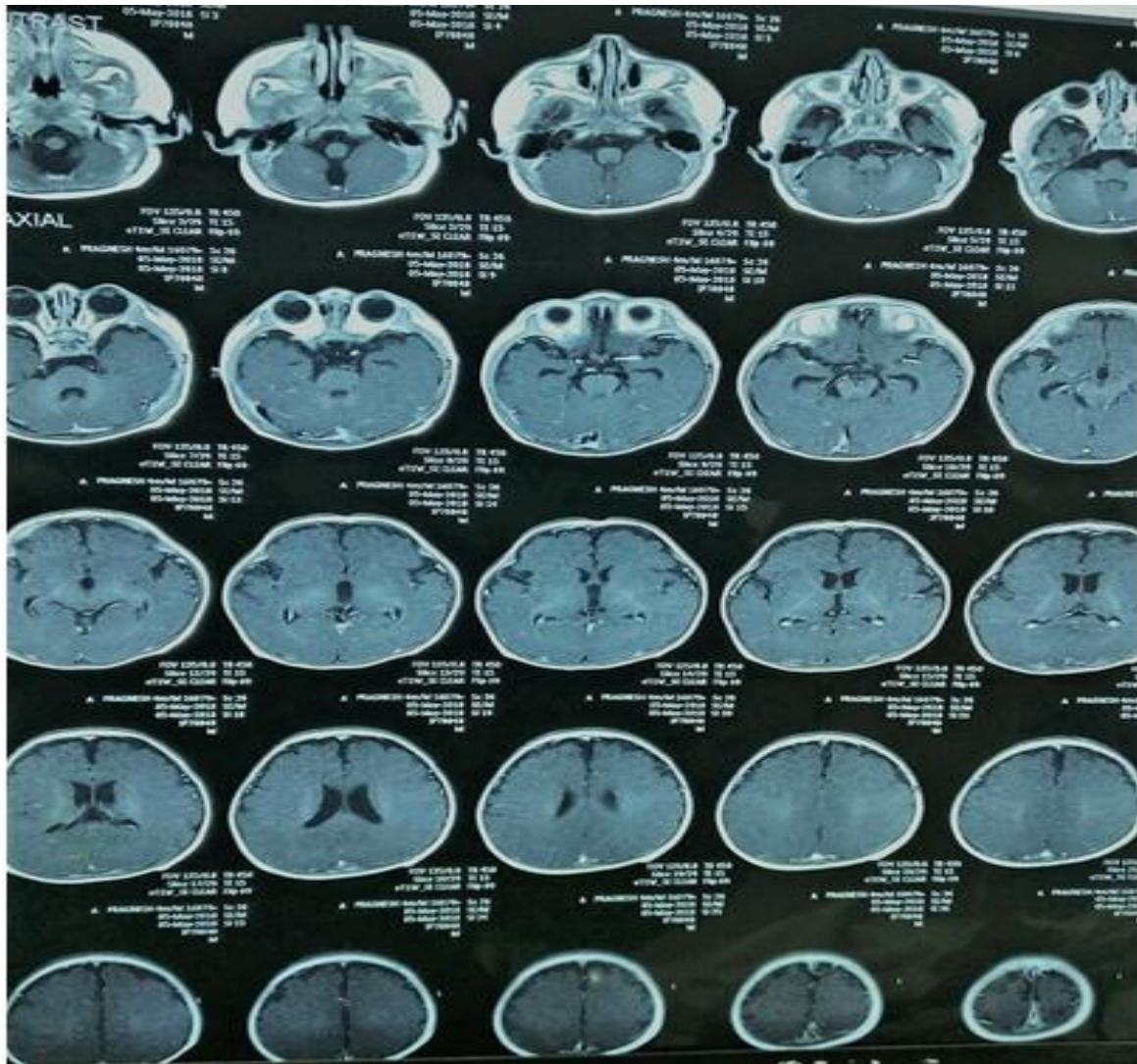


Fig. 2: Cranial MRI was normal and showed no metastasis.

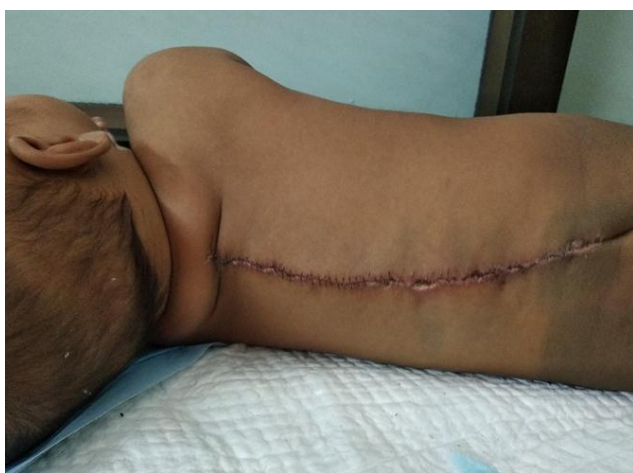

Fig. 3: Post-surgical scar of the patient underwent D7-S1 laminotomy with excision of tumor

**Neuropathology**

Histopathological examination showed a highly cellular embryonal tumour infiltrating fibro collagenous tissue and focally the cord parenchyma. Tumour cells were arranged in sheets and there were areas of necrosis and hemorrhage within the tumour. Cells were highly undifferentiated into polyhedral with vesicular to hyperchromatic nuclei. Some cells had prominent nucleolus and interspersed bi and multinucleate cells were seen. There was a high Nuclear: Cytoplasmic ratio in most of the cells whilst few cells had moderate to abundant eosinophilic cytoplasm imparting a rhabdoid like morphology. Mitosis and apoptosis were brisk. There was loss of integrase integrator-1 (INI-1) immunoeexpression. LCA, CD3, CD20, myeloperoxidase, CD99 and synaptophysin are negative. Loss of INI1 expression as observed in our case is now considered the gold standard for establishing the diagnosis of AT/RT.

Two weeks later, the child was re-admitted with vomiting and abnormal gaze. There was still no improvement in the power of his lower limbs and there was no further progression of weakness. Oculomotor nerve

palsy was seen. In view of suspected hydrocephalus/ brain metastasis, neuroprotective measures were taken. Repeat MRI taken showed communicating hydrocephalus under pressure with new metastatic lesions in the supratentorial regions and cerebellum. There was a new metastatic lesion at C3 level causing obstruction to the CSF flow. Ventriculotomy and urgent ventriculoperitoneal shunt for CSF diversion was created. Intra operative and post-operative periods were uneventful. Parents were counselled about palliative care with analgesics and symptomatic treatment. They were not willing for further management and have been lost to follow up for the last six months

## Discussion

AT/RT is a rare and highly malignant CNS neoplasm that often occurs in children, mostly below 2 years of age.<sup>5</sup> The tumor is markedly aggressive, with a median survival time of less than a year even with medical and surgical management.<sup>7</sup> It was initially described in 1978 as an aggressive variant of Wilms' tumor arising from the kidney.<sup>3</sup> Primary intracranial disease was first reported by Lefkowitz et al.<sup>12</sup> In 1996, Rorke et al identified it as a distinct CNS neoplasm and it was renamed as "atypical teratoid/rhabdoid tumor" (AT/RT).<sup>13</sup> The term "rhabdoid" was adopted because of its microscopic similarity to rhabdomyosarcoma. The "atypical" refers descriptively to the "teratoid" part of the tumor which show elements of two germ cell layers (ectoderm, i.e., primitive neuroepithelial, epithelial, and mesoderm, i.e., "rhabdoid") but is otherwise quite different from classical teratoid tumors.<sup>14</sup>

The proven number of cases of spinal ATRT are very few compared to the cranial counterparts. During a 19-year study period, Tekautz et al reported only one case of spinal AT/RT out of 31 patients diagnosed with CNS AT/RT.<sup>10</sup> In a meta-analysis of 133 cases of CNS AT/RT in children, only 1 case was located in the spinal cord.<sup>11</sup> So far, fewer than seven cases of spinal AT/RT in the lumbar region only have been reported. Overall prognosis of both cranial and spinal AT/RT is extremely poor and has a survival period ranging from 6-18 months.<sup>5,7,10</sup>

Historically, the incidence of AT/RT was underestimated because of its similarity to PNET, both histologically and by imaging.<sup>7</sup> Diagnosis is based on immunochemistry findings and light microscopy and can be further supported by genetic analysis.

ATRT is the only nervous system tumor for which a pathognomonic alteration of a tumor suppressor gene has been identified. ATRT is characterized by the loss of a tumor suppressor gene that has been identified as the hSNF5/INI-1 gene on chromosome 22.<sup>17</sup> This gene, however, is only found to be positive in 76% cases.<sup>18</sup> Other genetic abnormalities include monosomy 22; or novel complex rearrangements involving chromosome 6 and 11.<sup>15</sup> According to Biegel et al., absence of INI1 immune expression as seen in our case is associated with even poorer prognosis.<sup>15,16</sup>

Once the diagnosis of AT/RT is confirmed by pathology, abdominal imaging should be obtained to

exclude a primary renal tumor. Metastases should also be ruled out. The neuroimaging reports are usually nonspecific. The tumors are heterogeneous with solid portions that are isointense/hypointense on T2-weighted images. Hemorrhage and calcifications may be seen, and early CSF dissemination is common.<sup>5-7</sup> Unless contraindicated, CSF studies should be done as AT/RT can metastasize via CSF seeding. The presence of large rhabdoid tumour cells with eccentric nucleus in CSF, not only helps in confirming the diagnosis but also indicates disseminated disease and mandates aggressive therapy.<sup>19-20</sup> Hydrocephalus occurs in 1 to 8% of patients, probably due to tumoral obstruction of the subarachnoid CSF flow or impaired CSF absorption. Due to the high probability of metastasis, neuroimaging is recommended every 3 months for a period of 1 year following tumor resection.

There is no established treatment modality for children with CNS AT/RT. Most patients are treated with multimodal therapy in the form of maximal surgical resection followed by radiotherapy and adjuvant chemotherapy. Due to the neurocognitive changes, radiotherapy is usually not considered in the younger children. Although complete surgical resection is often impossible given the invasive nature of the tumor, studies show that these children have longer median survival. Chemotherapy (both systemic and intrathecal) have been used in many trials and the role of high dose chemotherapy is still debatable.

New therapeutic agents are being investigated with targeted action based on molecular and genetic studies. Aurora kinase A inhibitors induces cell death in AT/RT cell lines and thus sensitizes them to combination therapy. Histone deacetylase inhibitors decrease expression of cyclin D1 and reduce tumor cell proliferation. Insulin-like growth factor (IGF-1R) and its ligand IGF-II are present in AT/RT, thus use of the IGF-1R inhibitors inhibits tumor cell proliferation. Multi-kinase inhibitors sorafenib and sunitinib have been shown to inhibit the target receptors in AT/RT.<sup>8,9,21</sup> Most of these novel therapeutic agents are still in clinical study trials (phase II/III).

## Conclusion

ATRT is a highly aggressive tumour with a poor prognosis and survival rate. This tumour should always be considered in the differential diagnosis of pediatric CNS tumors with rapid deterioration. Several new therapeutic agents are being developed to prolong survival and to combat this rare and enigmatic tumor. More clinical trials and further understanding of molecular biology are necessary to develop optimal treatment approaches for children with AT/RT.

**Financial Support and Sponsorship:** None.

**Conflicts of Interest:** None.

## References

1. Huisman TA. Pediatric tumors of the spine. *Cancer Imaging* 2009;9(Special issue A):S45.
2. Stabouli S, Sdougka M, Tsitsopoulos P, Violaki A, Anagnostopoulos I, Tsonidis C, Kolioukas D. Primary atypical teratoid/rhabdoid tumor of the spine in an infant. *Hippokratia* 2010;14(4):286.
3. Beckwith JB, Palmer NF. Histopathology and prognosis of Wilms tumor results from the first National Wilms' Tumor Study. *Cancer* 1978;41(5):1937-1948.
4. Kleihues P, Burger PC, Scheithauer BW. The new WHO classification of brain tumours. *Brain pathol* 1993;1;3(3):255-268.
5. Hilden JM, Meerbaum S, Burger P, Finlay J, Janss A, Scheithauer BW et al. Central nervous system atypical teratoid/rhabdoid tumor: results of therapy in children enrolled in a registry. *J clin oncol* 2004;15;22(14):2877-2884
6. Lee YK, Choi CG, Lee JH. Atypical teratoid/rhabdoid tumor of the cerebellum: report of two infantile cases. *Am j neuroradiol* 2004;1;25(3):481-3.
7. Burger PC, Yu IT, Tihan T, Friedman HS, Strother DR, Kepner JL et al. Atypical teratoid/rhabdoid tumor of the central nervous system: a highly malignant tumor of infancy and childhood frequently mistaken for medulloblastoma: a Pediatric Oncology Group study. *Am j surg pathol* 1998;1;22(9):1083-1092.
8. Ginn KF, Gajjar A. Atypical teratoid rhabdoid tumor: current therapy and future directions. *Front oncol* 2012;12;2:114.
9. Biswas A, Kashyap L, Kakkar A, Sarkar C, Julka PK. Atypical teratoid/rhabdoid tumors: challenges and search for solutions. *Cancer manag res* 2016;8:115.
10. Tekautz TM, Fuller CE, Blaney S, Fouladi M, Broniscer A, Merchant TE, Krasin M, Dalton J, Hale G, Kun LE, Wallace D. Atypical teratoid/rhabdoid tumors (ATRT): improved survival in children 3 years of age and older with radiation therapy and high-dose alkylator-based chemotherapy. *J Clin Oncol* 2005;1;23(7):1491-1499.
11. Oka H, Scheithauer BW. Clinicopathological characteristics of atypical teratoid/rhabdoid tumor. *Neurol med chir* 1999;39(7):510-518.
12. Lefkowitz IB, Rorke LB, Packer RJ. Atypical teratoid tumor of infancy: definition of an entity. *Ann Neurol* 1987;22:448-449
13. Rorke LB, Packer RJ, Biegel JA. Central nervous system atypical teratoid/rhabdoid tumors of infancy and childhood: definition of an entity. *J Neurosurg* 1996;85:56-65
14. Dardis C, Yeo J, Milton K, Ashby LS, Smith KA, Mehta S et al. atypical Teratoid rhabdoid Tumor: Two case reports and an analysis of adult cases with implications for Pathophysiology and Treatment. *Front neurol* 2017;20;8:247
15. Biegel JA. Molecular genetics of atypical teratoid/rhabdoid tumors. *Neurosurg focus* 2006;20(1):1-7.
16. Biegel JA, Tan L, Zhang F, Wainwright L, Russo P, Rorke LB. Alterations of the hSNF5/INI1 gene in central nervous system atypical teratoid/rhabdoid tumors and renal and extrarenal rhabdoid tumors. *Clin Cancer Res* 2002;1;8(11):3461-3467.
17. Hoot AC, Russo P, Judkins AR, Perlman EJ, Biegel JA. Immunohistochemical analysis of hSNF5/INI1 distinguishes renal and extra-renal malignant rhabdoid tumors from other pediatric soft tissue tumors. *Am j surg pathol* 2004;1;28(11):1485-1491
18. Jin S, Sun C, Yu S, Wang Q, An T, Wen Y. Atypical teratoid/rhabdoid tumor of the brain in an adult with 22q deletion but no absence of INI1 protein: a case report and review of the literature. *Folia Neuropathol* 2015;1;53(1):80-85.
19. Huang EC, Guzman MA, De Girolami U, Cibas ES. Cytologic characterization of atypical teratoid/rhabdoid tumor in cerebrospinal fluid. *Cancer cytopathology* 2014;1;122(12):903-908.
20. Choi J, Kim H, Kim SH. Atypical teratoid/rhabdoid tumor: analysis of cytomorphologic features in CSF, focused on the differential diagnosis from mimickers. *Diagn cytopathology* 2012;1;40(7):592-596.
21. Frühwald MC, Biegel JA, Bourdeaut F, Roberts CW, Chi SN. Atypical teratoid/rhabdoid tumors—current concepts, advances in biology, and potential future therapies. *Neuro-oncology* 2016;10;18(6):764-778.

**How to cite this article:** Varughese PM, Ponnarneni S, Case report of an acute presentation of diplegia in a four-month old - to expect the unexpected!, *Int J Med Paediatr Oncol* 2019;5(1):39-43.