

Urethral duplication with review of literature

Shivam Priyadarshi^{1*}, Nachiket Vyas²

¹Senior Professor, ²Professor, ^{1,2}Dept. of Urology, Sawai Man Singh Medical College, Jaipur, Rajasthan, India

*Corresponding Author: Shivam Priyadarshi

Email: spriyadarshi64@gmail.com

Abstract

An eight year old boy with complete duplication of urethra presented with continent voiding per rectum and few drops from the normal meatal site on straining. The boy had stenotic native penile urethra and an ectopic urethral opening just inside the anus. Cystourethrogram confirmed saggital Y duplication of urethra. Investigations revealed no other anomaly except duplication of ureters on left side. We report this case because of its extreme rarity.

Keywords: Urethra, Abnormalities, Duplication.

Introduction

Duplication of urethra or accessory urethra is a rare congenital anomaly of the urogenital tract. Various types have been identified. Clinical presentation vary according to the type of anatomical abnormality. Duplication may begin from bladder neck proximal to distal urethra and may be complete or incomplete. It is most common in saggital plane with a dorsal and ventral urethra. Usually the ventral urethra is most functional and contains the sphincteric mechanism. Management is complex and depends on the duplication subtype.¹⁻³

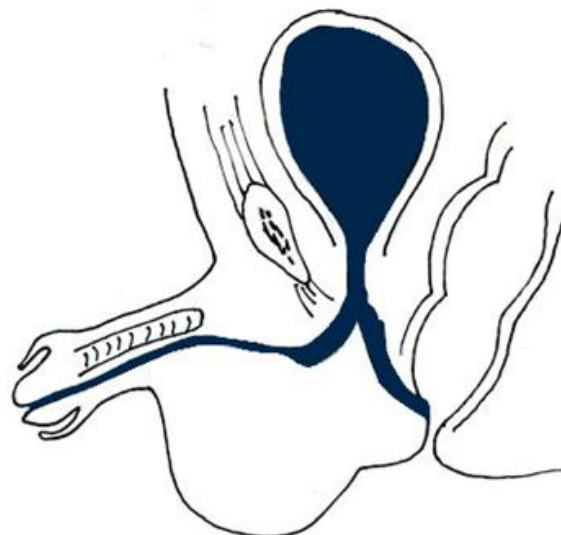
Case Report

An eight year old boy, was referred as a case of urethral anomaly presenting with voiding per rectum and few drops from the normal meatal site on straining (Fig. 1). Family history was not significant. Physical examination revealed a well nourished male with normal external genitalia. Native penile urethra was stenotic and a 3F ureteric catheter could pass only upto 1 cm. Ectopic urethral opening could be seen opening just inside the anal verge and was easily calibrated with urethral dilator (Fig. 2). Blood chemistry was normal. Excretory urography showed bilaterally normal functioning kidneys with duplicate ureters on left side. Bladder capacity was adequate with no significant residual urine. Voiding cystourethrogram and retrograde urethrogram revealed normally placed penile urethra with a very thin streak of dye and a perineal limb of normal urethral calibre.

The patient was managed in two stages. In the first stage, exploration revealed a thin atretic penile urethra and a normal calibre anal limb which was mobilised and brought into the perineum to form a perineal urethrostomy. In the second stage urethral reconstruction was done with transverse preputial island flap and hairless midline scrotal skin. The patient had an uncomplicated outcome.

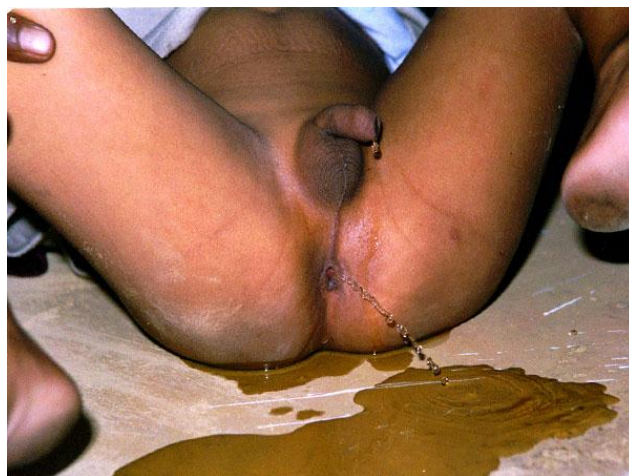

Fig. 1: Child presenting with continent voiding per rectum and few drops from the normal meatal site



Saggital Y duplication of urethra. Accessory track opening just inside the anus

Fig. 2: Line diagram showing anatomy of saggital Y urethral duplication

Discussion

Duplication of urethra is a rare congenital anomaly. It is most commonly found in males with only a few cases reported in females. Embryologically it appears to be a misalignment of the termination of the cloacal membrane and its relationship with the formation of genital tubercle and urogenital sinus. It has been grouped into two broad groups-Sagittal and Collateral.⁴ Sagittal is again divided into Y duplication, spindle, epispadiac and hypospadiac based on the position of ectopic urethral meatus. Both hypospadiac and epispadiac forms can be complete, incomplete or abortive. A urethra that splits partway along its course and then reunites without an additional ectopic meatus is defined as a spindle duplication, whereas one that ends ectopically in the perineum or anus is called a Y duplication.⁵ Collateral is grouped into complete and abortive. The most complete classification has been offered by Effmann et al.⁶

Type I- Incomplete urethral duplication,

Type II- Complete urethral duplication,

Two meatuses

1. Non communicating urethras arising independently from the bladder.
2. A second channel arising from the first and exiting independently.

Complete duplication joining at one meatus.

Type III- Duplication as a component of caudal duplication.

This case of Y sagittal duplication, according to the above classification falls into type II a.²

Other associated anomalies include bladder exstrophy, duplication of bladder, hypospadias, cryptorchidism and anal stenosis. Few cases of urethral triplication have also been reported. The Y type fistula usually takes its origin from the prostatic urethra and is commonly associated with stenosis of the anterior portion of the normally situated urethra. Urethral duplication in females in absence of duplication of bladder is extremely rare. Management varies from no treatment to complex staged urethroplasty.⁷ Blind ending accessory urethras generally do not cause symptoms and therefore do not require excision. Some prefer dilatation

of apical urethra but being hypoplastic the risk of inadequate urine flow is high. When the meatus of the ventral urethra is close to the apical urethral meatus, simple meatoplasty may give good functional results. In case ventral urethra is more posterior, urethroplasty is necessary. For Y type duplication scrotal flaps may be used for urethroplasty.⁸ Accessory dorsal urethra may be surgically excised taking care of the external sphincter and the neurovascular bundle.⁹

Conclusion

Urethral duplication is a rare congenital anomaly with a variable clinical presentation depending on urethral anatomy. Usually the ventral urethra is more functional and maintained after surgical correction. Management of sagittal Y urethral duplication involves complex staged urethroplasty. Overall the outcome is favourable in majority of cases and urinary continence as well as excellent cosmesis is achieved.

Conflict of Interest: None.

References

1. Gillenwater Y, Grayhack JT, Howards SS, Duckett JW. Adult and Paediatric urology, 3rd edition by A S Patterson. St. Louis 1996;2436-38..
2. Pshiramis KE, Colodny AH. Complete patent duplication of the urethra. *J Urol* 1986;136:63-67.
3. Kelalis P, King LR, Belman AB. Clinical Paediatric Urology, 2nd edition. Saunders, Philadelphia, 1992;656-60.
4. Woodhouse CR, Williams DI. Duplications of the lower urinary tract in the children. *Br J Urol* 1979;51:481.
5. Williams DI, Bloomberg S. Bifid urethra with preanal accessory track(Y duplication). *Br J Urol* 1975;47:877.
6. Effman EL, Lebowitz RL, Colodny AH. Duplication of urethra. *Radiol* 1976;119:179.
7. Prasad K, Vivekanandhan KGI. Duplication of urethra. *Paed Surg Int* 1999;15:419-421.
8. Podesta ML, Medel R. Urethral duplication in children: surgical treatment and results. *J Urol* 1998;160:1830-33.
9. Salle JLP, Sibai H. Urethral duplication in the male: Review of 16 cases. *J Urol* 2000;163:1936-40.

How to cite this article: Priyadarshi S, Vyas N, Urethral duplication with review of literature. *J Urol, Nephrol Hepatol Sci* 2019;2(1):6-7.