

## Early surgical intervention in elderly ureterocele alleviates lower urinary tract symptoms (LUTS) and recurrent urinary tract infection (UTI): A case series

Prashant Gupta<sup>1\*</sup>, Neeraj Agarwal<sup>2</sup>

<sup>1</sup>Assistant Professor, <sup>2</sup>Associate Professor, Dept. of Urology, Sawai Man Singh Medical College Hospital, Jaipur, Rajasthan, India

\*Corresponding Author: Prashant Gupta

Email: drprashant4647@gmail.com

### Abstract

Ureterocele is a congenital developmental defect mostly diagnosed in childhood. Elderly presentation of ureterocele is very rare and is usually diagnosed by chance when patient presents with some other complaints e.g. infection, stones. Reported here are three elderly male patients being treated for recurrent urinary tract infection (UTI) for more than a year without any success. They presented with unilateral ureteroceles with moderate hydroureteronephrosis. All of them were operated by endoscopic incision of the ureterocele without any ureteral stent in situ. Excellent post operative recovery with sterile urine culture achieved. Patients are completely fit and have had no further lower urinary tract symptoms (LUTS) symptoms till date. Thus all elderly patients presenting with LUTS are not prostatic should be thoroughly investigated and diagnosed before treating. Treatment of elderly ureterocele by Endoscopic incision gives excellent results hence should not be hesitated.

**Keywords:** Congenital, Endoscopic incision, Hydroureteronephrosis, LUTS, Recurrent UTI, Ureterocele.

### Introduction

Ureteroceles are cystic dilatations of the distal ureter that occur due to congenital ureteric wall weakness<sup>1</sup>. It is most commonly seen in children which is associated with duplex system mainly heterotopic. Elderly presentation of the ureterocele is very rare and is mainly orthotopic<sup>2</sup> and is usually present with LUTS and recurrent UTI. Very few cases are reported and even fewer publications on adult ureterocele in the literature. Here we present three elderly male patients presenting urinary tract symptoms and UTI which were later diagnosed with ureterocele and were successfully treated with endoscopic incision of ureterocele after thorough radiological investigations and lab tests.

### Discussion

A ureterocele is a cystic out-pouching of the distal ureter into the urinary bladder. It is one of the most challenging urologic anomalies faced by pediatric and adult urologists. Ureteroceles may pose a diagnostic and therapeutic dilemma with perplexing clinical symptoms resulting into different schools of thought for its treatment. Ureteroceles may be asymptomatic or may produce a wide range of clinical signs and symptoms ranging from recurrent cystitis UTI to bladder outlet obstruction to renal failure.<sup>3-6</sup> Because of the obstructive nature of ureteroceles, the activity of the affected renal unit varies from a normal, well-functioning kidney to a non-functioning, dysplastic kidney. However, with a proper diagnosis and treatment, the outcome remains excellent. Ureteroceles occur in approximately 1 out of 4000 children<sup>7</sup>. Females are affected 4-7 times more often than males. Approximately 80% of ureteroceles are associated with the upper pole moiety of a duplex system. When ectopic ureteroceles are associated with duplicated collecting systems, the upper pole moiety may be dysplastic or poorly functioning. Single-system ectopic ureteroceles are uncommon and are most often found in males. The most commonly accepted theory behind

ureterocele formation is the obstruction of the ureteral orifice during embryogenesis, with incomplete dissolution of Chwalla's membrane. This is a primitive, thin membrane that separates the ureteral bud from the developing urogenital sinus. Failure of this membrane to completely perforate during development of the ureteral orifice is thought to explain the occurrence of a ureterocele. Classification of ureterocele<sup>8</sup> based on the features of the affected ureteral orifice is as follows:

1. Stenotic ureteroceles - located inside the bladder with an obstructing orifice.
2. Sphincteric ureteroceles - lie distal to the internal sphincter. The ureterocele orifice may be normal or patulous, but the distal ureter leading to it becomes obstructed by the activity of the internal sphincter.
3. Sphincterostenotic ureteroceles - have characteristics of both stenotic and sphincteric ureteroceles.
4. Cecoureteroceles - are elongated beyond the ureterocele orifice by tunneling under the trigone and the urethra.

Currently, most pediatric ureteroceles are found during routine prenatal screening.

Adult ureteroceles may also be found incidentally during imaging studies, often obtained for complaints of unrelated symptomatology. During last 20 years the interventional approach for ureterocele has evolved from major open surgery to minimally invasive endoscopic puncture. The endoscopic approach<sup>9</sup> decreases the need for open surgical procedures and is more convenient with reduced postoperative morbidity in pediatric as well as adult patients.

### Case 1

A male patient aged 61 years with no history of diabetes or hypertension and normal blood biochemistry presented with the chief complaint of LUTS including storage as well as voiding symptoms from past 5 – 6 years.

His IPSS score was 24 and the USG findings were as – Right moderate hydroureteronephrosis with ureterocele at lower end. A Prostate of 26 gms and an insignificant amount of Post void urine. A urine culture positive for *E. coli* and colony counts  $> 10^5$ . In spite of a prolonged antibiotic & alpha blocker treatment the urine culture remained positive and symptoms remained unrelieved. So the patient was advised intravenous pyelography (Fig. 1.) which showed fusiform enlargement of right lower ureter with moderate hydronephrosis and hydroureter.

After counselling the patient underwent Cystoscopy and right side RGP. There was an obstructed ureterocele present on the right side so an endoscopic incision was given using Collin's knife (Fig. 2.). As a result after 2 weeks the patient's urine culture became sterile for the first time after a very long span and IPSS score came down to 6.

### Case 2

A male patient aged 56 years with no history of diabetes or hypertension and normal blood biochemistry presented with the chief complaint of LUTS along with predominantly storage symptoms from past 12 years. His IPSS score was 28 and the USG findings were as – A prostrate of 32 gm, a PVR of 18 ml with gross hydronephrosis and hydroureter on left side. A urine culture positive for *Enterococcus* with colony counts  $> 10^5$ .

After prolonged unsuccessful treatment with antibiotics and alpha blockers intravenous pyelography was done showing left side moderate hydronephrosis hydroureter with left side fusiform dilatation of lower ureter (Fig. 3.).

After counselling patient underwent Cystoscopy which showed fully obstructed ureterocele with a pin point ureteric opening. A Glide wire was negotiated with difficulty and endoscopic incision was given using Collin's knife and ureterocele widely opened. Turbid urine was drained from the left ureter. Post operative antibiotics were administered based on the culture report. Patient was discharged on day 2 with catheter in situ under antibiotic regime. The urine culture became sterile after 2 weeks and IPSS score came down to 7.

### Case 3

A male patient age 53 years came to us with complaints of left abdominal pain and recurrent urinary tract infection for more than a year. He had symptoms of increased frequency, urgency and bouts of fever in past. His IPSS score was 15. Even after getting treatment from multiple physicians the symptoms were not relieved completely. On ultrasonography, he had mild hydroureteronephrosis on the left side. His renal function tests were normal. Urine routine microscopy showed 10 – 15 pus cells and numerous RBCs so he was subjected to culture sensitivity which showed enterococci. He also underwent intravenous pyelography (Fig. 4) that showed complete duplex system on left side with mild to moderate hydroureteronephrosis with ureterocele in upper moiety and lower moiety opened with a separate ureter laterally which showed grade 2 reflux on MCU done later. Right side showed partial duplex system

upto upper ureter. After proper counselling patient was taken for cystoscopy under antibiotic cover and endoscopic incision was given on the ureterocele to relieve obstruction. After surgery patient's urine culture became sterile and the IPSS score reduced. By 6 week follow up the patient was completely relieved of his symptoms. As the reflux was of low grade, reimplantation surgery was not planned.

All three cases were under treatment by alpha blockers and antibiotics from a very long time but no successful results were found. A small surgical intervention was the key to their successful recovery and a comfortable life without any medications whatsoever.

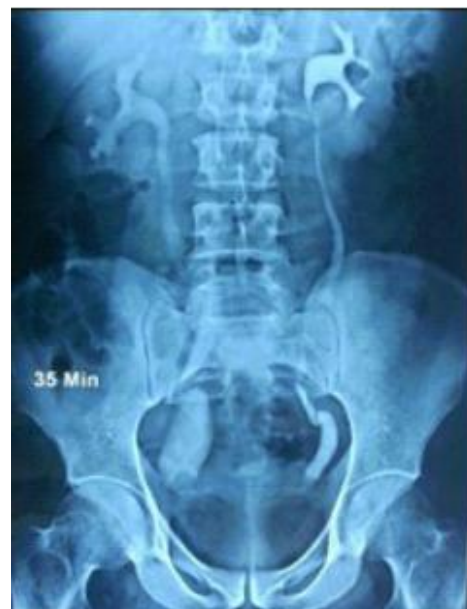

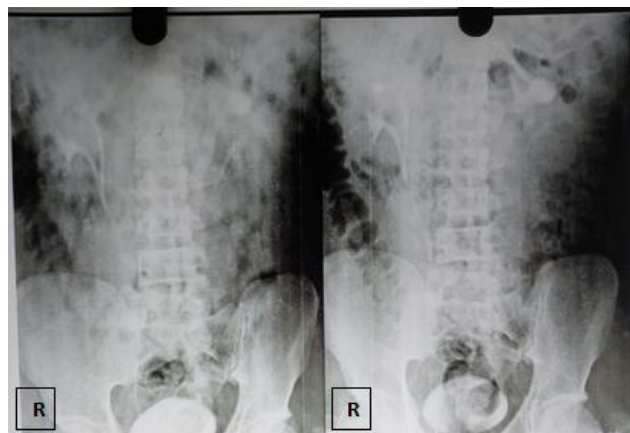
Fig. 1: Right side ureterocele present.

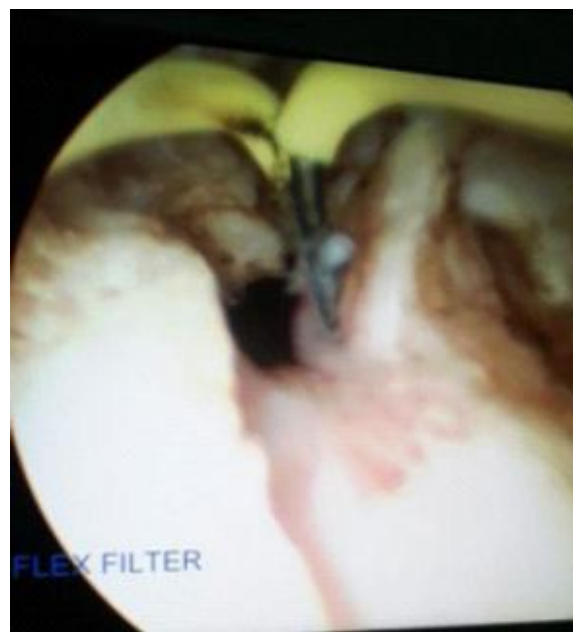
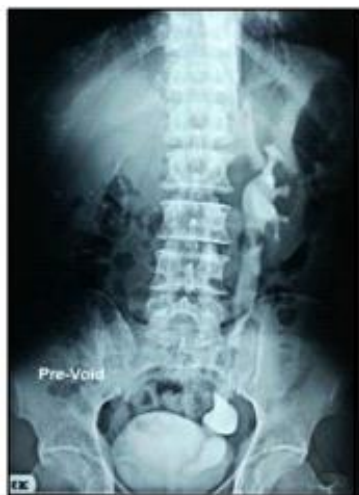
Fig. 2: Endoscopic incision give with Collins knife karl storz



**Fig. 3: Fusiform ureterocele present on left side**



**Fig. 4: Left side ureterocele in complete duplex system**

### Conclusion

Any elderly patient presenting with LUTS should not be blindly treated as prostatism. They should be investigated properly and timely intervention should be done to alleviate patient suffering. Endoscopic surgery<sup>10,11</sup> is a key procedure which should be freely utilized to mitigate this anomaly equally in children as well as elderly patients.

**Acknowledgement:** Dr. Surbhi Gupta for preparing and formatting the article.

**Conflict of Interest:** None.

### Reference

1. Neufang KF, M U, Beyer D. The roentgen diagnosis of ureterocele-with special reference to the simple orthotopic ureterocele in adults. *Rontgenblatter* 1981;34:9–14.
2. Catherine RH, Amjad A, Glen Y, Michael LE and Benjamin NB. Adult Ureterocele Presenting with Ureteral Obstruction and Urosepsis during Pregnancy. *Urol J* 2015;4;12(4):2285–6.
3. Sinha RK, Singh S, Kumar P. Prolapsed ureterocele, with calculi within, causing urinary retention in adult female. *BMJ Case Rep* 2014;2014

4. Prakash J, Goel A, Kumar M, Sankhwar S. Stone in ureterocele peeping through ureteric orifice. *BMJ Case Rep* 2013;2013
5. Westesson K, Goldman H. Prolapse of a single-system ureterocele causing urinary retention in an adult woman. *Int Urogynecol J* 2013;24:1761–3.
6. Clark CW, Leadbetter GW Jr. General treatment, mistreatment and complications of ureteroceles. *J Urol*. 1971;106(4):518-20.
7. Cooper CS, Passerini-Glazzel G, Hutcheson JC, Iafrate M, Camuffo C, Milani C et al. Snyder HM 3rd. Long-term followup of endoscopic incision of ureteroceles: intravesical versus extravesical. *J Urol* 2000 Sep;164(3 Pt 2):1097-9
8. Peters CA, Schlüssel RN, Mendelsohn C. Ectopic ureter, ureterocele, and ureteral anomalies. In: Wein AJ, ed. *Campbell-Walsh Urology*. 10th ed. Philadelphia, PA: Elsevier Saunders; 2011:chap 116.
9. Hagg MJ, Mourachov PV, Snyder HM, Canning DA, Kennedy WA, Zderic SA, Duckett JW. The modern endoscopic approach to ureterocele. *J Urol* 2000;163(3):940-34.
10. Sander JC, Bilgutay AN, Stanasel I, Koh CJ, Janzen N, Gonzales ET et al. Outcomes of endoscopic incision for the treatment of ureterocele in children at a single institution. *J Urol* 2015;193(2):662-6.
11. García Saavedra S, Peláez Mata D, Alvarez Zapico JA, Alvarez Muñoz V, Díaz Blanco M, García Crespo JM. Endoscopic treatment of ureterocele in children: is a long term effective technique?. *Cir Pediatr* 2006;19(1):15-8.

**How to cite this article:** Gupta P, Agarwal N, Early surgical intervention in elderly ureterocele alleviates lower urinary tract symptoms (LUTS) and recurrent urinary tract infection (UTI): A case series. *J Urol, Nephrol Hepatol Sci* 2019;2(1):8-10.