

## Occupational heavy metal fume inhalation induced Acute kidney injury

Vikash Khandelia<sup>1</sup>, Umashankar Nama<sup>2</sup>, Vijay Kumar Meena<sup>3\*</sup>, Tasneem Koser<sup>4</sup><sup>1</sup>Associate Professor and HOD, <sup>2,3</sup>Junior Residents, <sup>4</sup>Medical Officer, <sup>1,4</sup>Dept. of Nephrology, <sup>1,4</sup>Govt. Medical College, Kota, Rajasthan, India**\*Corresponding Author: Vijay Kumar Meena**

Email: aharivijaymi29@gmail.com

**Abstract**

We present a case of severe haemolytic anemia with acute kidney injury within 48 hour of inhalation of toxic fume of mixtures of aluminium and lead in a heavy metal factory worker. Patient required 7 sessions of intermittent haemodialysis and after 3 weeks patient become nonoliguric and dialysis independent and made a full recovery in 3 month. We suggest that workers in metal factory should be tested for blood levels of metals on a periodic basis to avoid health hazards due to chronic exposures to toxic metal fumes.

**Keywords:** Heavy metal, Acute kidney injury, Haemolytic anemia, Toxic fumes, Dialysis.**Introduction**

Industrial workers are at risk of developing various complications due to ingestion and inhalation of heavy metals.<sup>1</sup> Heavy metals ingestion leading to nephrotoxicity has been described with cadmium, lead, mercury, zinc, aluminium<sup>2</sup> and naphthalene.<sup>3</sup> Glue and thinner (benzene, toluene etc). sniffing is a serious medical problem because these components can cause sudden death and severe damage to liver, kidney, brain, heart and bone marrow<sup>4</sup>. Aluminium glue inhalation had been documented to cause kidney damage.<sup>5</sup> Normally inhalation of heavy metal toxins lead to pulmonary complications<sup>1,6</sup> but we present a case where inhalation of toxic fumes of lead and aluminium in a metal factory, led to severe haemolysis with oliguric acute kidney injury.

**Case Report**

A 33 year old metal factory worker presented to emergency department with complaints of pain abdomen, nausea, vomiting, shortness of breath and restlessness after exposure to toxic metal fumes at his workplace. He was working in a metal factory of aluminium and lead products. On attempting to extinguish the fire in his metal factory, he accidentally inhaled toxic metal fumes, about 48 hour before admission.

His wife gave history of decline in urine output and red colour urine about 50-100 ml 4-6 hours before admission.

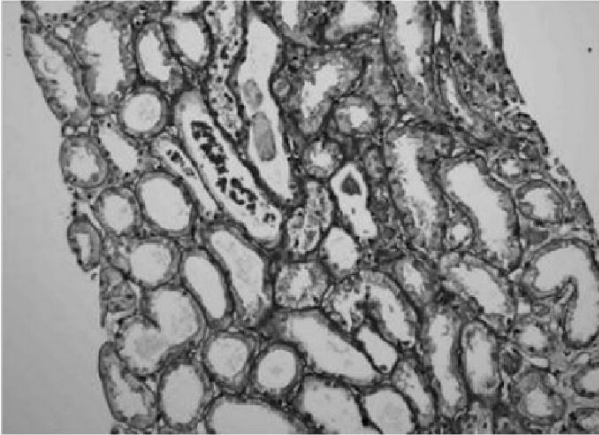
He had no previous medical history of note and was usually fit and well.

On examination he was pale and in respiratory distress with respiratory rate of 32 per minute and oxygen saturation 92% in room air. He was conscious and oriented to time, place, person. His vitals were stable with blood pressure of 132/82 mmHg, pulse rate 110 beats per minute and chest auscultation revealed bilateral diffuse inspiratory crackles.

Laboratory investigations revealed severe anaemia [haemoglobin 5.7 gm/dl], renal impairment [serum urea 172 mg/dl, serum creatinine 7.8 mg/dl] with blood gas showing severe metabolic acidosis. He was shifted to intensive care unit with close monitoring of vitals, central venous pressure, urine output etc. He was treated with diuretics, blood transfusion and in view of severe metabolic acidosis with pulmonary edema, was subjected to intermittent haemodialysis. Further workup was suggestive of evidence of haemolysis [elevated serum lactate dehydrogenase (LDH) levels and serum bilirubin levels, schistocytes on peripheral smear] with bilateral normal size kidney on sonography and normal glucose-6-phosphate dehydrogenase levels. Patient was subjected to haemodialysis and blood transfusion as per protocol and renal biopsy was done on day 14<sup>th</sup> to ascertain the cause of renal involvement as patient was anuric with declining LDH levels.

**Table 1: clinical and lab parameters during hospital stay**

	Day 1	Day3	Day5	Day7	Day10	Day14
Hb	5.7gm/dl	5.1gm/dl	6.1gm/dl	5.6gm/dl	6.5gm/dl	7gm/dl
TLC	11030	12590	12420	10190	11138	10543
PLT	220000	150000	145000	155000	206700	260000
B.urea	172	204	112	206	146	86
S.creat	7.8	9.8	8.5	10.7	8.2	6.2
S.LDH	12358	10078	8219	4579	2175	2029
S. bili	3.3	2.6	1.6	0.8	0.8	0.7
Urine output	Nil	Nil	20ml	30ml	70ml	60ml



**Fig. 1: Renal biopsy showing pigment cast in tubules.**

### Discussion

Our patient was working in a metal factory where aluminium and lead were processed. He was exposed to toxic fumes when he was trying to extinguish the fire in metallic products.

Exposure to toxic heavy metals like Lead, cadmium, mercury, silver can lead to hemolysis<sup>7</sup> and acute kidney injury. Chronic exposure to lead, cadmium, mercury and silver has major toxic effect on kidneys because of long half life and accumulation in renal cortex<sup>8</sup> and progressive decline in glomerular filtration rate (GFR).

Inhalation of toxic fumes has been associated with toxic fume fever<sup>9-10</sup> with approximately 2000 cases reported annually. Aluminium glue inhalation had been documented to cause kidney damage.<sup>5</sup> Aluminium is an element that has toxic effects on neurological, hematopoietic system and bone metabolism.<sup>5</sup>

But in our case inhalation of lead and aluminium fumes led to severe haemolytic anemia with acute kidney injury within 48 hours of inhalation. The exact etiology is uncertain as previous literature has not mentioned this kind of association. We postulate that toxins got absorbed through respiratory tract after reaching in bloodstream led to hemolysis and further complications.

It has been demonstrated that some toxic metals such as lead are elevated in the blood of solvent-addicted patients. So it may be possible that our patient was already exposed chronically to the toxins and developed hemolysis and acute kidney injury after exposure to the toxic fumes.

### Conclusion

Inhalation of toxic metal fumes has been associated with various clinical manifestations but our case is probably the first one, where patient developed severe haemolysis and acute kidney injury within 48 hours of exposure to toxic metal fumes of aluminium and lead. We suggest that workers in metal factory should be tested for blood levels of metals on a periodic basis to avoid health hazards due to chronic exposures to toxic metal fumes.

**Conflict of Interest:** None.

### References

1. Howard HU. Harrison's Principles of Internal Medicine. 20<sup>th</sup> Ed. Chapter 449, Heavy metal poisoning, Pg.3297-3300.
2. Recep Kutlubay, Emin oguzhan. Aluminium induced kidney damage by intraperitoneal administration of alpha tocopherol. *Int j Toxicol* 2007;262:95-101.
3. Timos Valaes, Spyros A Doxiadis, Phaedon Fessas. Acute hemolysis due to naphthalene inhalation. *J Pediatr* 1963;63(5):904-15.
4. Yoshida T, Ishiwata T, Miyata K, Ishizawa F. Analysis of toluene in exhaled air of glue sniffers and workers using thinner at work place. *Chudoku Kenkyu* 2004;17:45-50.
5. Cemal Akay, Suleyman Kalman. Serum aluminium levels in glue-sniffer adolescent and in glue containers. *Basic Clin Pharmacol Toxicol* 2008;102(5):433-6.
6. B. Nemery. Metal toxicity and respiratory tract. *European Respir j* 1990;3:202-19.
7. Ribarov SR. On the heavy metal compounds haemolytic action. *Acta Pharmacol Toxicol [Copenh]* 1986;59(7):478-81.
8. Gonick, HC. Nephrotoxicity of cadmium and lead. *Indian J Med Res* 2008; 128: 335-352.
9. Liss GM. Health effects of welding and cutting fume-an update. Ontario; Ministry of labour final report, 1996 Dec; section 3.3.
10. Offerman PV, Finley CJ. Metal fume fever. *Ann Emerg Med* 1992;21:872-5.

**How to cite this article:** Khandelia V, Nama U, Meena VK, Koser T, Occupational heavy metal fume inhalation induced Acute kidney injury. *J Urol, Nephrol Hepatol Sci* 2019;2(1):11-12.