

## Foramina of alisphenoid- A morphological and morphometric study in an adult dry skull of South Indian population

Mamatha. Y<sup>1,\*</sup>, Thilak Nidhi Y. T<sup>2</sup>

<sup>1</sup>Associate Professor, <sup>2</sup>MBBS III<sup>rd</sup> Year Student, <sup>1,2</sup>Dept. of Anatomy, <sup>1,2</sup>Kodagu Institute of Medical Sciences Madikeri, Karnataka, India

\*Corresponding Author: Mamatha. Y

Email: drmamthay@gmail.com

### Abstract

**Introduction:** The skull base presents various foramina establishing communications between extracranial and intracranial structures. The alisphenoid presents common foramina like Foramen ovale [FO] and Foramen Rotundum [FR] and accessory foramina like emissary sphenoidal foramina/foramen Vesalius, concerned with various advanced surgical procedures involving the middle cranial fossa.

**Objectives:** The objectives of this study were to determine exact range of measurements of FO and FS and also to determine the incidence of accessory foramina in alisphenoid.

**Materials and Methods:** The present research study was conducted on One hundred (100) dry adult skulls, and various parameters like length and width were measured using digital vernier caliper and morphological features like shape, absence or any other abnormalities of foramina were observed. The observed data was tabulated and analyzed statistically using SPSS Software Version 20.

**Results:** In our study, mean width of FO was with mean of 3.96±0.74 mm and 4.0±0.77, length was 7.2±0.99 mm and 7.15±0.88mm, FS length mean was 2.71±0.58 mm and 2.67±0.50 mm, width mean was 1.93±0.45mm and 1.98±0.47mm on right and left side respectively. Morphological variants shape like oval (91%), round (9%) and it was oval in 89% and round in 11% on right side and left side of FO respectively. FS was round shaped in 100% of cases.

**Conclusion:** The present study provides baseline data of normal and variant morphological and morphometric dimensions of various foramina affecting alisphenoid, the area which have got greater clinical implications.

**Keywords:** Foramen, Spinosum, Ovale, Emissary, Vesalius, Alisphenoid.

### Introduction

The skull base has a lot of foramina that establishes communications between the intracranial and extracranial structures through various neurovascular structures. Along with common foramina, there are foramina called emissary foramina, which allows the passage of emissary veins to carry blood between internal and external structures of the skull. A variety of neoplastic processes and trigeminal neuralgia have been documented to involve the Foramen ovale and rotundum. Among various foramina affecting greater wings of sphenoid, Foramen Ovale [FO] and Foramen spinosum [FS] are important foramina concerned with advanced diagnostic and therapeutic procedures involving middle cranial fossa like trigeminal radiofrequency rhizotomy, placement of an electrode for EEG analysis, microsurgical procedure using middle meningeal artery as a graft etc.<sup>1</sup> The foramen rotundum (FR) is generally 3.4 mm long, which traverses the maxillary nerve is situated just below and posterior to the medial end of the superior orbital fissure. Posterolateral to the rotundum (FR) lies the Foramen ovale (FO), Behind the FO is the Foramen spinosum (FS), which traverses the middle meningeal artery and nervous spinosus. It is usually two to four metric linear units long with median diameter about 1.5 to 3.62 mm. In addition, there could also be accessory foramina like ovale accessorium that communicates middle cranial cavity to the pterygoid fossa. This was described as an opening with smooth walls in front and medial to FO which leads

to an oblique channel opened near the root of pterygoid process. It is generally known that "Vein of Vesalius", an emissary vein through which the cavernous sinus communicates with pterygoid plexus. However, a small nerve (nervulus sphenoidalis lateralis) may also pass through this foramen into cavernous sinus.<sup>2</sup>

Knowledge of variations of foramina Ovale and Spinosum along with accessory foramina will help in distinguishing potentially abnormal foramina from normal during CT and MRI scan procedures. This study is of great clinical and anatomical significance for diagnosing tumors, treating trigeminal neuralgia and differentiating any abnormal bony growth in this region.<sup>3</sup>

Variations of Skull base foramina are always found to be associated with vascular and nervous malformations as implicated by various clinical symptoms. Thus the present study was undertaken to define range of dimensions of foramen ovale and spinosum in 100 dried adult skulls among South Indian Population. Prior knowledge of variations in morphology and morphometric data of such foramina may be important for academic, anthropological, forensic and clinical purpose and this study aims to highlight such.

### Materials and Methods

The present study was conducted on 100 adult dried human skulls. Measurements of the foramina ovale and spinosum were taken using digital vernier caliper by placing on the anteroposterior (length) and transverse (width) diameters of the foramina. Observed measurements were

compiled and morphological variants were photographed. Various measurements between right and left side were statistically analyzed, using SPSS (V20) by using student's 't' test method and p-value < 0.05 was considered statistically significant.

## Results

We observed morphological variants of FO like round (9%) and oval (91%) on right side and on left side it was oval in 89% and round in 11% respectively (Table 4). FS was in round shape in 100%. In the present study, Emissary sphenoidal foramen were observed in 10 cases- 6 on right and 4 on left side of skulls (Table 3).

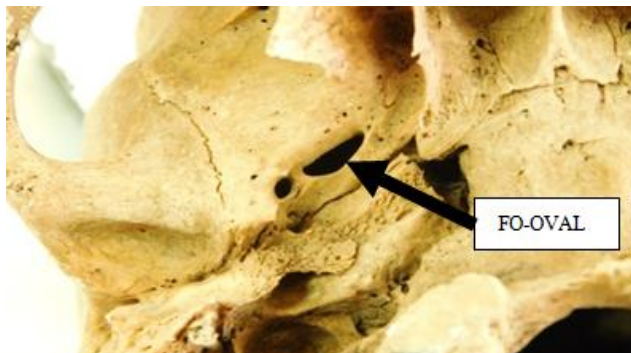

Fig. 1: FO- Oval shaped

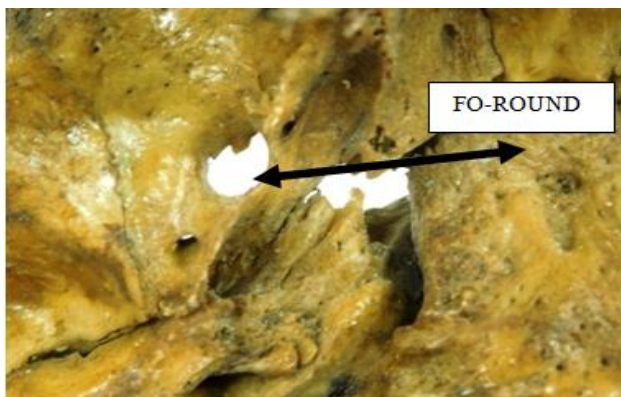

Fig. 2: FO-Round shaped

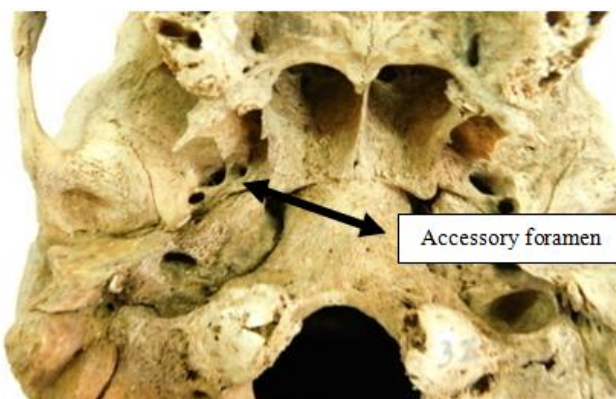


Fig. 3: Accessory emissary foramen – Foramen of Vesalius.

## Morphometric dimensions Analysis

In our study, on the right side, FO length ranged from 10.6 -5.02mm and on the left side was from 8.86 – 5.04 mm with mean of  $7.2\pm 0.99$  mm and  $7.15\pm 0.88$ mm respectively, width of FO ranged from 6.32 – 2.38 mm on right side and 6.8– 2.51 mm on the left side with mean of  $3.96\pm 0.74$  mm and  $4.0\pm 0.77$  mm respectively [Table.1]

In the present study, length of right FS ranged from 4.13 – 1.65mm while on the left side it was 3.89 -1.45 mm with a mean of  $2.71\pm 0.58$  mm and  $2.67\pm 0.50$  mm respectively. The width range was between 2.9 – 1.14mm on right side and 3.26 – 1.23 mm on left side with a mean of  $1.9\pm 0.45$ mm and  $1.98\pm 0.47$ mm respectively [Table 2]. The difference between observed mean values was not statistically significant with ( $p \geq 0.05$ ) in both the cases. But it was observed that there was a positive correlation between length & width of foramens.

## Discussion

According to the Wood jones F (1931), opines that the foramen ovale forms an important venous outlet in humans. Occasionally Foramen ovale may be narrowed or subdivided into compartments due to the in growing spicules of bone, the anterior portion of which may be considered as the foramen of Vesalius or emissary sphenoidal foramen. Sometimes, 2 to 3 mm anteromedial to foramen ovale lies foramen of vesalius. Hence the emissary sphenoidal foramen is can be an expression of the variant differentiation of cranial venous outlets that is characteristic of humans and does not occur in any of other primates.<sup>4</sup>

Embryologically variation in the dimension and shape of foramina of alisphenoid can be explained on the basis of its development. Sphenoid bone develops from pre and post-sphenoid centres which contribute to the formation of basis phenoid (body) part and lesser wing, the post-sphenoid centre forms the greater wing and pterygoid process of sphenoid bone. The foramen ovale is situated at the posterior border of greater wing of sphenoid bone. FV is the point of fusion between the membranous part of the ossification bone and the medial cartilaginous part which is given the name, ala temporalis. The morphologically variant foramina and grooves around the foramen ovale region can develop from the defects in the parts of the membranous bone and the bridging venous plexus from the middle meningeal vein through pterygoid venous plexus. As the skull base development begins after the development of neurovascular structures of cranium, the presence of FV depends on the individual venous drainage organization.<sup>5</sup>

Tuel et al reports in his study that knowledge about position and topographical relation of the FO is important related to operations of cavernous sinus done by lateral approach, which minimizes complications of injury to trigeminal nerve.<sup>6</sup>

Zdilla MJ et.al, emphasise that the FS acts as a landmark in numerous neurosurgical procedures involving the middle cranial fossa. Variants like duplicaton of foramen may disorient the surgeon; alter the flow of blood with

**Table 1: Observed morphometric dimensions of foramen ovale.**

	Maximum Length		Maximum -Width	
	Right	Left	Right	Left
Max	4.13	3.89	2.98	3.26
Min	1.65	1.45	1.14	1.23
Mean	2.71852	2.67297	1.938541	1.9807
Median	2.67	2.65	1.895	1.915
Mode	2.18	2.65	1.76	1.76
SD	0.583469	0.507969	0.455067	0.477177
p value	0.556666456		0.566245058	

**Table 2: Observed morphometric measurements of foramen spinosum**

	Maximum - Width		Maximum -Length	
	Right	Left	Right	Left
Max	6.32	6.8	10.6	8.86
Min	2.38	2.51	5.02	5.04
Mean	3.9682	4.0065	7.2748	7.1545
Median	3.945	3.96	7.33	7.125
Mode	3.23	4.85	7.63	7.12
SD	0.746712	0.770629	0.994096	0.883749
p value	0.721528274		0.366869557	

**Table 3: Incidence of occurrence of accessory foramen**

	Accessory Foramen	
	Foramen vesalius	
	Right	Left
Absent	94	96
Present	6	4

**Table 4: Incidence of Occurrences of different morphological pattern of FO**

	Shape of FO	
	Right	Left
oval	91	89
round	9	11

**Table 5: showing Comparative study of foramen Vesalius along with the present study:<sup>11</sup>**

Name of author	Year	Incidence	Bilateral	Unilateral
Boyd et al	1930	36.8%	14.7%	21.8%
Bergmen et al	1995	40%	35%	13%
Berge et al	2001	59%	35%	24%
Gupta et al	2005	32.58%	22.85%	20.58%
Kale et al	2009	45%	25%	19.9%
Rossi et al	2010	40%	13.76%	26.25%
Vipavadee et al	2012	16%	4.2%	11.9%
Hussain et al	2012	36%	24%	16%
Neha Gupta et.al	2014	34%	14%	20%
Present Study	2017	10%	-----	10%

resultant duplication of middle meningeal artery and may have anthropological implications.<sup>7</sup>

The FV is additionally thought-about to be one among the foremost pathologically affected foramina as tumors of cavity origin typically tend to invade the center portion of the bone base. In view of the surgical and anaesthetic procedures involving the skull-base, associate correct osteometric analysis of the FS and FV together with their relative incidences, shapes, morphometric details, several relations to the FO and presence of any anomalies bears much significance.<sup>8</sup>

The foramen ovale plays a very important role in various surgical as well as diagnostic procedures. It helps in the easy access of the trigeminal nerve thus helps to anaesthetize the Mandibular nerve. Foramen ovale plays a vital role in procedures like percutaneous biopsy of tumors of cavernous sinus, percutaneous trigeminal rhizotomy for trigeminal neuralgia due to easy access of the gasserian ganglion and electroencephalic analysis of the seizure for selective amygdalohippocampotomy my patients. The dimensions of the Foramen ovale are used to assess the skull base symmetries.<sup>9</sup>

Knowledge of the exact topography and morphometry dimensions of the Foramen ovale is required for a more precise anatomico-electro-clinical correlation of seizures. EEG (Electroencephalographic) analysis of seizure by placing an electrode at Foramen ovale is now being done. This electrode technique provides good neurophysiological information in patients for selective amygdalohippocampectomy.<sup>10</sup>

The incidence of occurrence of foramen Vesalius in the present study was in 10% which almost near to the observation of vipavadee et.al and here it was more on left side unilaterally. In the present study, mean length of FS was  $2.71 \pm 0.58$  mm and  $2.67 \pm 0.50$  mm respectively. The mean width was  $1.93 \pm 0.45$  mm and  $1.98 \pm 0.47$  mm respectively which was near the value reported by Siddharth Tiwari et al, among south Indian population with mean length of FS  $2.95 \pm 1.32$  mm,  $3.20 \pm 0.8$  mm, mean width of  $2.1 \pm 0.8$  on right and  $2.2 \pm 0.7$  mm left side respectively.<sup>12</sup>

In the present study the FO length ranged from 10.6 -5.02 mm and on the left side was from 8.86 – 5.04 mm with mean of  $7.2 \pm 0.99$  mm and  $7.15 \pm 0.88$  mm respectively, width of FO ranged from 6.32 – 2.38 mm on right side and 6.8– 2.51 mm on the left side with mean of  $3.96 \pm 0.74$  mm and  $4.0 \pm 0.77$  mm respectively, almost similar with the findings reported by an author Somesh MS et al, with the mean length and width values  $7.64 \pm 1.19$  mm,  $5.12 \pm 0.82$  mm,  $7.5 \pm 1.2$  mm,  $5.2 \pm 0.9$  mm on right and left side of skulls respectively.<sup>13</sup>

## Conclusion

The present study was aimed at having a detailed description of foramen of alisphenoid including its variant shapes, sizes, etc in order to provide good insight for neurosurgeons, neuroradiologists and neurologists who performs many neurosurgical procedures in the middle cranial fossa. Not solely that, this study is of anatomical significance but also clinically significant to medical practitioners and radiologists as for the understanding and recognition of the morphometric variations of the foramina during routine radiological and clinical investigation. The presence of accessory foramina is rare. Owing to being a small and variant foramen, the FV is not routinely in attention during surgery. Foramen inominatum has been given very low importance and has not been much researched on. Because of such data studies about the occurrence of the FV, may assist the neurosurgeon to realize that the FV is located very close to the FO, particularly at the extracranial view of the skull base. Therefore, in case it exists, the approach through the FO could be the more complicated procedure and also may impose great threat to the surgeon.

## Acknowledgement

I would render heartfelt thanks to all the teaching and Nonteaching faculties who were their along with this studies until completion. Sincere thanks to ICMR- STS for creating an oppourtunity to conduct, the scientific and ethical committee for their needy help for the completion of this study.

**Conflict of Interest:** None.

## References

1. Phalguni Srimani, Foramina in Allisphenoid: An Observational Study on their. *Osseo Morphology Morphometry* IJARS/2014/8.76:0001.
2. Nadire Unver Dogan et.al. Anatomical Examination of the Foramina of the Middle Cranial Fossa. *Int J Morphol* 2014;32(1):43-48.
3. Kulkarni Saurabh P, Nikade Vrushi V, Morphometric Study of Foramen Ovale and Foramen Spinosum in Dried Indian Human Skulls. *Int J Recent Trends Sci Technol* ISSN 2277-2812E-ISSN 2249-8109, 2013;7(2):74-75.
4. Poornima B, Phaniraj S, Mallikarju. Study of incidence of emissary sphenoidal foramen in dry adult human skull bones. *Indian j pharm sci res* 2015;5(4):273-275.
5. Murlimanju BV. Foramen of Vesalius: Prevalence, Morphology, Embryological Basis and Clinical Implications 1, *J Surg Acad* 2015;5(1):24-
6. Tuel, Asymmetry of the ovale and spinous foramina in mediaeval and contemporary skulls in radiological examination. *Folia Morphol* 2002;61(3):147-152.
7. Zdilla MJ, Cyrus LM, Laslo JM and Lambert HW. Bilateral Duplication of the Foramen Spinosum: A Case Report with Clinical and Developmental Implications. *Anatomy & Physiology: Current Research* 2014; 4:157.
8. Lazarus, L.; Naidoo, N. & Satyapal, K. S. An Osteometric Evaluation of the Foramen Spinosum And Venosum. *Int J Morphol* 2015;33(2):452-458.
9. Karishma Ravinthaar, Morphometric Study of Size and Symmetry of Foramen Ovale in Dry Skulls. *J Pharm Sci Res* 2015;7(10):830-833.
10. Girish V Patil. The duplication of the foramen ovale in human skulls of south indian population. *J evol med Dent Sci* 3(41):10249-10253.
11. Neha Gupta. Incidence of Foramen Vesalius in Adult Human North Indian Crania. *IOSR J Dent Med Sci* 2014;13(5):34-38.
12. Siddharth Tewari Morphometric analysis of foramen spinosum in South Indian Population. *Acta Med Iranica* 2018;56(2):113-118.
13. Somesh M. Amorphometric study of foramen Ovale. *Turk Neurosurg* 2011;21(3):378-383.

**How to cite this article:** Mamatha Y, Thilak N YT, Foramina of alisphenoid- A morphological and morphometric study in an adult dry skull of South Indian population. *Indian J Anat Surg Head Neck Brain* 2018;4(4):17-20.