

## Efficacy and safety of synchronous use of the fractional carbon dioxide laser with low, medium or high-dose isotretinoin for treatment of acne and acne scars: A retrospective study of 80 patients from the Indian population

Jagdish Sakhiya<sup>1\*</sup>, Dhruv Sakhiya<sup>2</sup>, Ashish Dedakiya<sup>3</sup>, Mihir Modi<sup>4</sup>, Feral Daruwala<sup>5</sup>

<sup>1</sup>Senior consultant, <sup>2,5</sup>Medical Writer Department, <sup>3,4</sup>Junior consultant, <sup>1,3,4,5</sup>Sakhiya Skin Clinic Pvt Ltd, Surat. Gujarat, <sup>2</sup>B.J. Medical College, New Civil Hospital Asarwa, Ahmedabad, Gujarat, India

\*Corresponding Author: Jagdish Sakhiya

Email: sakhiya.academic@rediffmail.com

### Abstract

**Introduction:** Isotretinoin is an approved drug from the United States (US) Food and Drug Administration (FDA) for the treatment of severe recalcitrant nodular acne. Based on reports of poor wound healing and scarring, many practitioners believe that the majority of cutaneous laser treatments should be delayed at least six to 12 months after a patient discontinues isotretinoin treatment. The purpose of this study was to investigate the safety and the efficacy of fractional carbon dioxide laser combined with the low (6mg/day), medium (18mg/day) or high dose (30mg/day) of isotretinoin for the treatment of acne and acne scars and, investigation of the factor associated with the synchronous use of isotretinoin and fractional CO<sub>2</sub> laser.

**Settings and Design:** The study was retrospective, non-randomized, single-centre, open case series performed in our private clinic. A retrospective chart review was conducted for all patients registered at our private clinic for assessment of acne from April 2016 through March 2018.

**Materials and Methods:** In this study, 80 patients with acne scarring were treated with 10,600nm fractional CO<sub>2</sub> laser. Out of eighty, 60 patients in three experimental groups received different dose of isotretinoin (n=20, low dose: 6mg/day; n=20, medium dose: 18mg/day; n=20, high-dose: 30mg/day) prior to the initial fractional CO<sub>2</sub> laser treatment. 20 patients with acne scarring who was treated only with the fractional CO<sub>2</sub> laser served as control. Acne scars improvement, healing period and presence of keloids formation was taken in account as outcome measured after 6 months follow-up.

**Statistical analysis:** Comparisons of differences in the demographic profile, efficacy and healing period among four groups was done by Kruskal-Wallis test. Multiple comparisons were performed using Kruskal-Wallis test followed by the p-value was adjusted using the Holm-Bonferroni sequential correction "P" to identify independent factors associated with synchronous use.

**Results:** In the fractional CO<sub>2</sub> laser with medium-dose isotretinoin group, all patients demonstrated normal wound healing also satisfactory acne scar improvement. Moreover, no hypertrophic scars or keloids were observed in patients from this group. Grade of acne, doses of isotretinoin, No of the treatment session, % of MTZ applied during the session, level of MTZ and passes per session were an independent factor that significantly correlated synchronous use of with isotretinoin and fractional CO<sub>2</sub> laser.

**Conclusion:** Based on findings the author concluded that synchronous use of a medium dose of isotretinoin and the fractional CO<sub>2</sub> laser was an excellent choice for the future treatment regime.

**Keywords:** Acne, Acne improvement, Healing period, Isotretinoin, Microthermal damage zone, Treatment sessions.

### Introduction

Acne is a natural human skin disease, is defined by areas of skin with seborrhea (scaly red skin), comedones (blackheads and whiteheads), papules (pinheads), pustules (pimples), nodules (large papules) and possibly scarring prevalence of over 90% among adolescents.<sup>1,2</sup> Acne can leave acne scars; it can be psychologically stressful, especially in adolescents and has reported that 1% of the general population having acne scars.<sup>3</sup> Briefly, there are three main types of scars that can arise from acne: atrophic, hypertrophic or keloids, from which atrophic being the most common.<sup>4</sup> Over the past few decades, a wide variety of therapeutic interventions have been developed to treat acne scars, including dermabrasion, subcision, punch techniques, chemical peels, tissue augmentation, and laser.<sup>5</sup>

Isotretinoin (13 cis-retinoic acids) is a non-aromatic retinoid that was approved by the United States (US) Food and Drug Administration (FDA) as an oral capsule formulation in May 1982 with an indication for treatment of severe recalcitrant nodular acne.<sup>6,7</sup> For adults, maximum doses of isotretinoin useful in the treatment of mild to

moderate acne are 2 mg/kg/day.<sup>8</sup> Although it is known that isotretinoin is a very useful drug for acne and acne scarring, some previous articles have reported the development of scars associated with dermabrasion or laser treatment related to isotretinoin use. The interval of time between these treatments and keloids formation was two weeks to six months, and there were increases in peeling and inflammation of existing lesions and development of exuberant granulation tissue.<sup>9,10</sup> Many practitioners believe that the majority of cutaneous laser treatments should be delayed at least six to 12 months after a patient discontinues isotretinoin treatment due to considering that it may lead to scarring and delayed healing.<sup>11</sup>

Heidi et al<sup>12</sup> documented a survey of 220 nationally recognized experts in cutaneous laser surgery to evaluate physician experience and opinion pertaining to laser and light procedures in patients treated with isotretinoin, including perceived risk and actual complications. From his findings, concluded that there was limited literature available to support concerns about poor wound healing, whereas a growing number of studies cite no incidence of

impaired wound healing also safe in association with laser use in isotretinoin-treated patients. In literature, several studies were published in which the patients treated with distinctive kind of laser who already consuming isotretinoin and, the result suggested normal wound healing.<sup>13,18</sup> Yoon et al<sup>14</sup> was evaluated the safety and efficacy of infrared fractional CO<sub>2</sub> laser combined with low-dose isotretinoin (10mg/day) for the treatment of acne and acne scars and, its findings suggested that combined therapy has given a promising result. Still, there is a conflict between the synchronous use of isotretinoin and laser and, further consideration is required in this gray era. However, in literature, no study was reported for the effect of varying dose of isotretinoin when synchronized with the laser, provoked our study. Herein, the study was designed as a retrospective and non-randomized to investigate the safety and the efficacy of fractional carbon dioxide laser combined with the low (6mg/day), medium (18mg/day) or high dose (30mg/day) of isotretinoin for the treatment of acne and acne scars and, also assess the factor associated with the synchronous use of isotretinoin and fractional CO<sub>2</sub> laser.

## Materials and Methods

### Study design and participants

In this retrospective, non-randomized, single-centre, open case series, 80 patients' were enrolled and data were collected from our private skin clinic. The study was conducted in accordance with the Declaration of Helsinki and, patients were also provided written informed consents for the images to be published. A retrospective chart review was conducted for all patients registered at our private clinic for assessment of acne from April 2016 through March 2018. For evidence of acne, the clinical and dermatological examination was done in each patient. After an initial assessment, each patient with acne scarring was treated with 10,600nm fractional CO<sub>2</sub> laser who were already receiving isotretinoin. 20 patients were enrolled in each group. All patients had taken the same dose of isotretinoin in each group with variation in duration of medication (15.42±7.45 months). For comparing the effectiveness, we set up a control group: 20 patients with acne scarring who was treated only with the fractional CO<sub>2</sub> laser.

Control group: Fractional CO<sub>2</sub> laser only (n=20)

Group 1: Fractional CO<sub>2</sub> laser with low-dose (6 mg /day) isotretinoin (n=20)

Group 2: Fractional CO<sub>2</sub> laser with medium-dose (18mg /day) isotretinoin (n=20)

Group 3: Fractional CO<sub>2</sub> laser with high-dose (30mg /day) isotretinoin (n=20)

Age more than 60 years, concurrent pregnancy or lactation, patients with a history of atrophic scars or keloids, human immunodeficiency virus, tuberculosis, porphyria or photosensitivity, immunosuppression, active infection, either laser or cosmetic treatment performed in the past 6 months were exclusion criteria included in the study.

### Laser Treatment

The 10,600nm fractional CO<sub>2</sub> laser was used in the study. For standard and control group, each treatment session was adopted pulse energy of 10–240 mJ per microthermal damage zone (MTZ). The treatment levels of MTZ differed from one to six, and one to three passes per session. Each patient received treatment between two and seven sessions at intervals of 28 to 42 days. The treatment levels of MTZ were categorized as follows: Level 1, 1-10mJ; Level 2, 11-20mJ; Level 3, 21-30mJ; Level 4, 31-40mJ; Level 5, 41-50mJ; Level 6, 51-60mJ.

### Outcome Assessments

After completion of all the treatments, evaluation of a series of photographs at every patient's 6 months follow up visit was done by a dermatologist and, the assessment of the treatment presented. The assessment was categorized as follows: Grade 0, no effect; Grade 1, <25%, mild improvement; Grade 2, 25–49%, moderate improvement; Grade 3, 50–75%, marked improvement; Grade 4, >75%, excellent, fair improvement. Additionally, we evaluated the patient's photograph using the 'Global acne scarring classification' suggested by Goodman given in Table 1.<sup>19</sup>

### Statistical Analysis

Statistical analyses were performed using the SPSS software (SPSS version 21.0, SPSS, Chicago, IL, USA). To compare the difference in the demographic profile among four groups, chi-square and Kruskal–Wallis test was used. Notably, chi-square was used for categorical variable and Kruskal–Wallis test used for the ordinal or continuous variable. To compare differences in efficacy and healing period, between control and three experimental groups, the Kruskal–Wallis test was used. In series to determine the independent factors associated with synchronous use, multiple comparisons were performed using Kruskal–Wallis test followed by the p-value was adjusted using the Holm–Bonferroni sequential correction "P".<sup>20,21</sup> The significance level was set at 0.05.

## Results

### Patients

The demographic details of 80 Acne patients recruited in the present study were provided in Table 2. Findings of chi-square test revealed that the distribution by gender was similar among the four groups. Results from Kruskal–Wallis test suggested, there was no statistically significant difference in age ( $\chi^2 = 5.327$ ,  $df = 3$ ,  $P = .15$ ) and age of onset ( $\chi^2 = 5.295$ ,  $df = 3$ ,  $P = .15$ ) found among the four categories of participants. Furthermore, grade of acne had statistically significant difference ( $\chi^2 = 68.762$ ,  $df = 3$ ,  $P = <.001$ ).

### Fractional photothermolysis sessions and densities

Fractional photothermolysis sessions and densities received by the patient in each group were provided in Table 3 and

the graphical representation of treatment sessions could be seen in Fig. 1.

**Improvements of acne scar lesions after treatment and comparisons of difference in healing period between control and experimental groups**

At the 6-month follow-up visit, fractional CO<sub>2</sub> laser with low-dose isotretinoin group demonstrated that out of 20 patients, three patients (15%) showed fair improvement and, 17 patients (85%) showed marked improvement. A fractional CO<sub>2</sub> laser with medium-dose isotretinoin group showed fair improvement and marked improvement in 18 patients (90%) and two patients. 19 patients (95%) showed fair improvement and, one patient (5%) showed marked improvement in the fractional CO<sub>2</sub> laser with high-dose isotretinoin group. In the control group, 13(65%) patients showed moderate improvement and, 7(35%) patients showed marked improvement. The improvement in acne scarring was shown in Fig. 2b, 3b, 4b, 5b compared to pre-treatment photographs Fig. 2a, 3a, 4a, 5a.

Kruskal-Wallis test was conducted to examine the differences in efficacy and healing period according to the types of treatment taken and the results obtained were given in Table 4. From findings concluded that there was a statistically significant difference in efficacy ( $\chi^2 = 61.72, df = 3, P = <.001,$ ) and healing period ( $\chi^2 = 24.415, df = 3, P$

$= <.001,$ ) found among the four categories of participants (fractional CO<sub>2</sub> laser only group, fractional CO<sub>2</sub> laser with low-dose isotretinoin, fractional CO<sub>2</sub> laser with medium-dose isotretinoin, fractional CO<sub>2</sub> laser with high-dose isotretinoin).

Additionally, we evaluated the incidence of atrophic scarring or keloids. From 60 patients of the standard group, none had atrophic scarring or keloids.

Kruskal-Wallis test was conducted to examine whether the parameters such as age, onset age, gender, grade of acne, skin type, the total period of oral isotretinoin, doses of isotretinoin, No of the treatment session, the interval between respective session, % of MTZ applied during the session, level of MTZ, passes per session, were correlated with the synchronous use of isotretinoin and fractional CO<sub>2</sub> laser. Obtained results are summarized in Table 5 and adjusted using the Holm-Bonferroni correction. The analysis revealed that grade of acne ( $\chi^2=25.391, df=1, P = <.001,$ ), doses of isotretinoin ( $\chi^2=28.320, df=1, P = <.001,$ ), No of the treatment session ( $\chi^2=20.773, df=1, P = <.001,$ ), % of MTZ applied during the session ( $\chi^2=9.618, df=1, P = .01,$ ), level of MTZ ( $\chi^2= 20.515, df=1, P = <.001$ ) and passes per session ( $\chi^2=20.540, df=1, P = <.001$ ) significantly correlated with the synchronous use of isotretinoin and fractional CO<sub>2</sub> laser.

**Table 1:** Qualitative scarring grading system suggested by Goodman<sup>19</sup>

Grades of Post Acne Scarring	Level of disease	Clinical features
1	Macular	These scars can be erythematous, hyper- or hypopigmented flat marks. They do not represent a problem of contour like other scar grades but of colour.
2	Mild	Mild atrophy or hypertrophy scars that may not be obvious at social distances of 50 cm or greater and may be covered adequately by makeup or the normal shadow of shaved beard hair in men or normal body hair if extra facial.
3	Moderate	Moderate atrophic or hypertrophic scarring that is obvious at social distances of 50 cm or greater and is not covered easily by makeup or the normal shadow of shaved beard hair in men or body hair if extra facial but is still able to be flattened by manual stretching of the skin (if atrophic).
4	Severe	Severe atrophic or hypertrophic scarring that is evident at social distances greater than 50 cm and is not covered easily by makeup or the normal shadow of shaved beard hair in men or body hair if extra facial and is not able to be flattened by manual stretching of the skin.

† ‘Global acne scarring classification’ suggested by Goodman, 2006

**Table 2:** The demographic details of 80 acne patients recruited in the study

Particulars	Control (Fractional CO <sub>2</sub> laser only) (n=20)	Fractional CO <sub>2</sub> laser with low-dose isotretinoin (n=20)	Fractional CO <sub>2</sub> laser with medium-dose isotretinoin (n=20)	Fractional CO <sub>2</sub> laser with high-dose isotretinoin (n=20)	Statistical analysis
Age	24.95±7.69	24.20±7.19	22.75±4.06	23.55±6.24	Kruskal-Wallis H $\chi^2=5.327$ $df=3$ $P = .15$
Male: Female	3:17	6:14	11:9	14:6	Kruskal-Wallis H
Male n (%)	3(15%)	6(30%)	11(55%)	14(70%)	$\chi^2=2.26$
Female n (%)	17(85%)	14(70%)	9(45%)	6(30%)	$df=1$

<b>Age of onset (Mean ± SD)</b>	24.15± 7.71 years	23.35±7.03 years	21.75± 4.18 years	22.80±6.16 years	<i>P</i> =.13 Kruskal-Wallis H $\chi^2=5.295$ <i>df</i> =3 <i>P</i> =.15
<b>Median Grade of acne(Range)</b>	1(1-1)	1.50(1-2)	3(2-3)	4(3-4)	Kruskal-Wallis H $\chi^2=68.762$ <i>df</i> =3 <i>P</i> = <.001***
<b>The range of Fitzpatrick skin type</b>	III-IV	III-IV	III-IV	III-IV	
<b>The total period of oral isotretinoin treatment (Mean ± SD)</b>	-	11.45±5.87 months	16.50±7.25 months	18.30±7.66 months	

† Comparison of difference in demographic profile between control and experimental groups using chi-square or Kruskal Willey as appropriate.SD, Standard deviation. \*\*\**P* value <.001 considered being significant.

**Table 3:** Results of fractional photothermolysis treatment sessions and densities received by the patient in control and standard group

<b>Control (Fractional CO<sub>2</sub> laser only)</b> No of laser treatment sessions(Mean± SD)(Range) No of the patient received 1-10% MTZ of conventional densities (%) No of the patient received 11-20% MTZ of conventional densities (%) No of the patient received MTZ treatment level 1(%) No of the patient received MTZ treatment level 2(%)	5.70±1.49(4-8) 2(10%) 18(90%) 2(10%) 18(90%)
<b>Fractional CO<sub>2</sub> laser with low-dose isotretinoin</b> No of laser treatment sessions(Mean± SD)(Range) No of the patient received 1-10% MTZ of conventional densities (%) No of the patient received 11-20% MTZ of conventional densities (%) No of the patient received MTZ treatment level 1(%) No of the patient received MTZ treatment level 2(%)	4.40± 0.82(4-6) 2(10%) 18(90%) 1(5%) 19(95%)
<b>Fractional CO<sub>2</sub> laser with medium-dose isotretinoin</b> No of laser treatment sessions(Mean± SD)(Range) No of the patient received 11-20% MTZ of conventional densities (%) No of the patient received MTZ treatment level 2(%)	6.50±1.28(4-8) 20(100%) 20(100%)
<b>Fractional CO<sub>2</sub> laser with high-dose isotretinoin</b> No of laser treatment sessions(Mean± SD)(Range) No of the patient received 11-20% MTZ of conventional densities (%) No of the patient received MTZ treatment level 2(%) No of the patient received MTZ treatment level 4(%) No of the patient received MTZ treatment level 6(%)	7.10±1.02(6-8) 20(100%) 2(10%) 7(35%) 11(55%)

† SD, Standard deviation; MTZ, microthermal damage zone.

**Table 4:** Comparison of the difference in the efficacy and healing Period of the fractional CO<sub>2</sub> laser with a low, medium and high dose of isotretinoin with a control group using the Kruskal–Wallis test

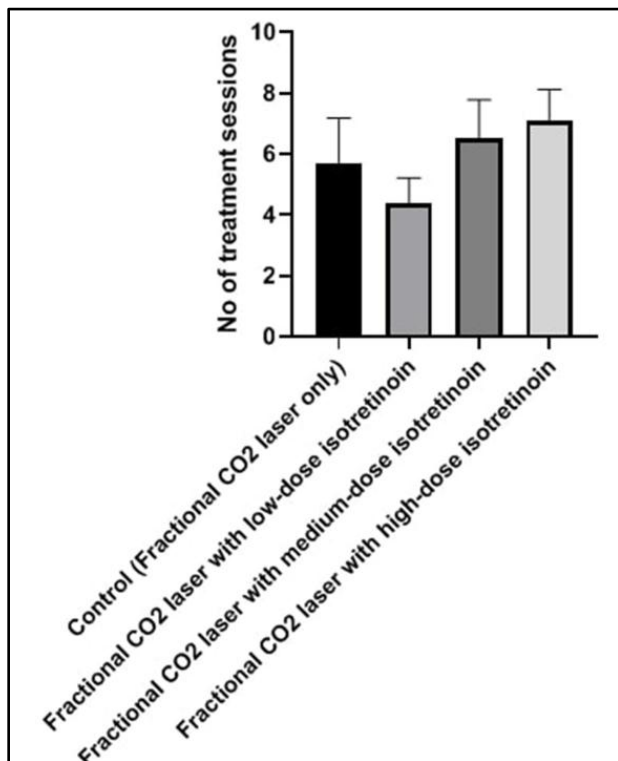
<b>Groups</b>	<b>N</b>	<b>Mean rank for Efficacy</b>	<b>Mean rank for the Healing period (Days)</b>
Control (Fractional CO <sub>2</sub> laser only)	20	14	34
Fractional CO <sub>2</sub> laser with low-dose isotretinoin	20	32.03	34
Fractional CO <sub>2</sub> laser with medium-dose isotretinoin	20	57.15	38
Fractional CO <sub>2</sub> laser with high-dose isotretinoin	20	58.83	56
		Kruskal-Wallis H $\chi^2=61.718$ <i>df</i> =3 <i>P</i> = <.001***	Kruskal-Wallis H $\chi^2=24.415$ <i>df</i> =3 <i>P</i> = <.001***

† \*\*\**p* value <.001 considered being significant.

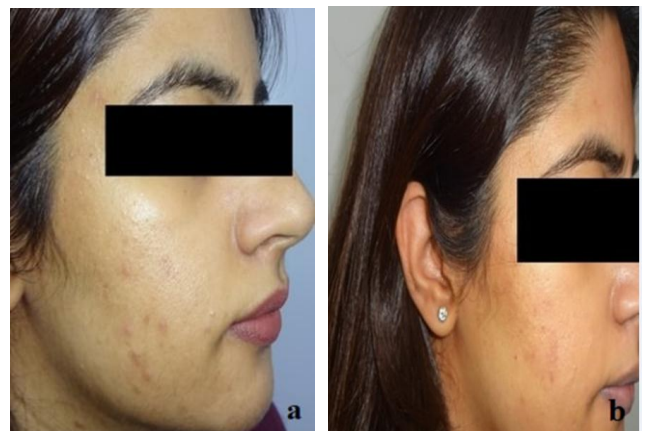**Table 5:** Compilation of independent factors associated with the treatment success using Kruskal-Wallis test and adjusted using the Holm-Bonferroni sequential correction “P”

Independent Variables	Chi-square value	Df	P -value	Bonferroni corrected P -value
Age	0.000	1	.99	1.00
Gender	5.546	1	.02*	.10
Age of onset	0.018	1	.89	1.00
Grade of acne	25.391	1	<.001***	<.001***
Fitzpatrick skin type	0.773	1	.38	1.00
Total period of isotretinoin	6.019	1	.01*	.08
Doses of isotretinoin	28.320	1	<.001***	<.001***
No of the treatment session	20.773	1	<.001***	<.001***
Interval between each session	0.711	1	.40	1.00
% of MTZ applied during the session	9.618	1	.002*	.01*
Level of MTZ	20.515	1	<.001***	<.001***
Passes per session	20.540	1	<.001***	<.001***

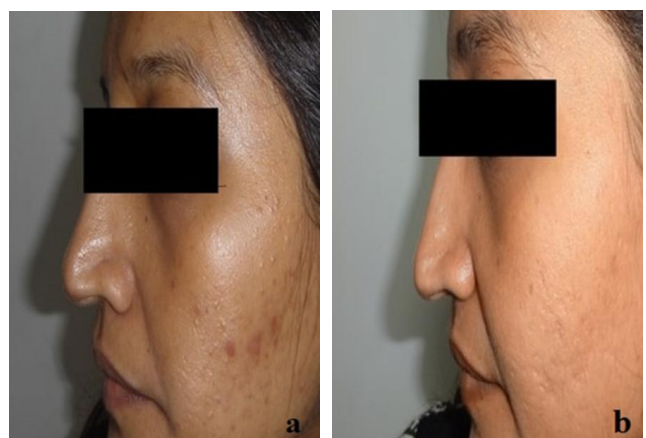
† SD, Standard deviation. df, degree of freedom. \*P value <0.05 considered being significant. \*\*\* P value <.001 considered being significant.



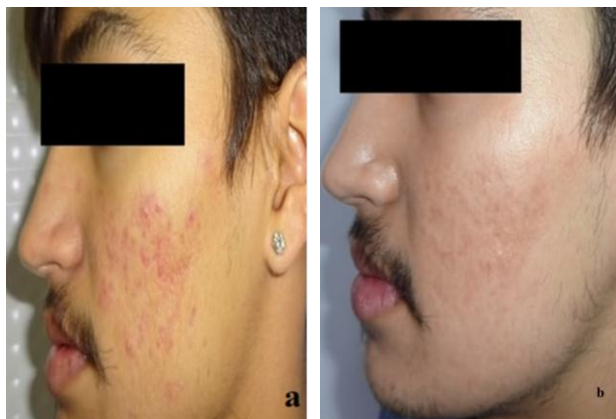**Fig. 1:** Comparison of the number of laser treatment sessions in standard and control groups



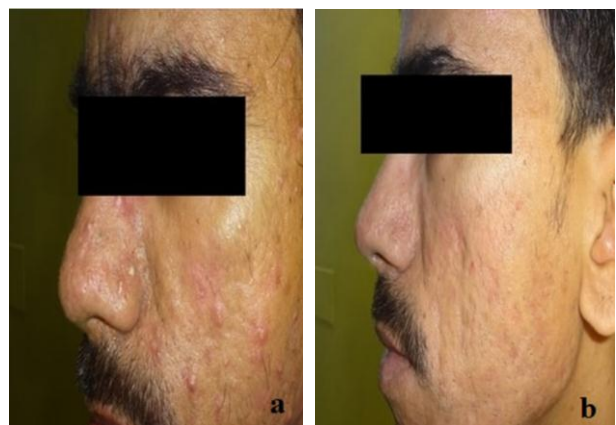**Fig. 2:** Clinical improvement in acne scars following fractional CO<sub>2</sub> laser only group, showing: a) Ere treatment, b) Later treatment



**Fig. 3:** Clinical improvement in acne scars following fractional CO<sub>2</sub> laser treatment with low- dose isotretinoin, showing: a) Ere treatment, b) Later treatment



**Fig. 4:** Clinical improvement in acne scars following fractional CO<sub>2</sub> laser treatment with medium-dose isotretinoin, showing: a) Ere treatment, b) Later treatment



**Fig. 5:** Clinical improvement in acne scars following fractional CO<sub>2</sub> laser treatment with high-dose isotretinoin, showing: a) Ere treatment, b) Later treatment

## Discussion

The pathogenesis of acne currently attributes to varied factors, such as increased sebum production, alteration of the quality of sebum lipids, androgen activity, the proliferation of *Propionibacterium acnes* (*P. acnes*) within the follicle and follicular hyperkeratinization.<sup>22</sup> Inflammations, granulation tissue, and matrix remodelling are the principal three steps involved in the pathogenesis of acne scars. In the matrix remodelling step, fibroblasts and keratinocytes perform a critical role, producing matrix metalloproteinases (MMPs) and tissue inhibitors of MMPs. The imbalance of MMPs to tissue inhibitors of MMPs acts a significant role in scar formation.<sup>23</sup>

The effects of isotretinoin on acne scar formation are controversial because of conflicting opinions about the effects of retinoids on the metabolism of connective tissue. Most authors believe that isotretinoin induces delayed or altered reepithelialization due to the alteration of the pilosebaceous unit and the ability of isotretinoin to inhibit the action of collagenase.<sup>24</sup> Because of these reasons; many dermatologists believe that laser treatments should be delayed at least six to 12 months after discontinuing

isotretinoin. In 1985, Oikarinen and Uitto reported that retinoids are thought to modulate connective tissue metabolism in keloids fibroblast cultures, and suppression of production of collagenase by retinoids may be responsible for the keloids formation. Findings indicated a differential modulation of connective tissue metabolism by retinoids in keloids cell cultures. Specifically, the production of procollagen and the synthesis of activable collagenase were markedly inhibited, while the activity of an elastase-like neutral protease assayed in fibroblast culture medium was enhanced by the retinoids.<sup>25</sup> We think that our study is worthy because it is the first follow-up study of the correlation between acne scars and synchronous use of the fractional CO<sub>2</sub> laser with low, medium and high-dose isotretinoin. This study showed no aggravation of acne scars and better acne scar improvement yet limited by the small sample size. It also showed that a high dose of isotretinoin gave excellent improvement (mean rank 58.83 vs. 32.03) but delay the healing period (mean rank 56 vs. 34). As per patient compliance point of view, it is not a good choice.

The patient had no complained after synchronous use of isotretinoin and fractional CO<sub>2</sub> laser. Some patient encountered dry skin, itching, rash, dry nose, nosebleeds, cracks in the corners of the mouth, dry mouth, dry lips, cracking or peeling skin, inflammation of the whites of the eyes, dry eyes, joint pain, back pain, dizziness, drowsiness, nervousness, or changes in your fingernails or toenails. These effects produced due to the isotretinoin side effect and, they not associated with synchronous use of isotretinoin and fractional CO<sub>2</sub> laser.<sup>7</sup>

The fractional CO<sub>2</sub> laser is a suitable treatment for inflammatory Acne. An effect produces due to various mechanisms on acne production : (i) It makes channels through the epidermis to the dermis diminishing occlusion of the duct gland and producing transepidermal elimination of the sebaceous material (ii) It produces coagulation of the surrounding area of the channels diminishing inflammation and the vascular component<sup>26</sup> (iii) It produces high residual thermal damage on the surrounding tissues which could produce protein denaturation, reducing bacteria in the follicle (*P. acnes*) and could affect the gland, diminishing sebaceous production.<sup>27</sup> A swollen gland full of fluid or any cystic lesion on the skin seems to be a good target for a CO<sub>2</sub> laser whose main chromophore is water and a selective photothermolysis of the surrounding tissue could occur due to the heat diffusion inside the cyst as the theory of extended selective photothermolysis explains for the spherical structures.<sup>28</sup>

The medium dose and high-dose isotretinoin-administered group showed a satisfactory improvement in acne scarring than the fractional CO<sub>2</sub> laser treatment only group. (Mean rank in the medium and high-dose isotretinoin-administered group; 32.03, 57.5 vs. 14). The difference in the effectiveness could be the result of the difference in the laser treatment sessions (more treatment sessions in the medium and high-dose isotretinoin-administered group; 6.50±1.28, 7.10±1.02 vs. 5.70±1.49). For better clarification of this issue, a study with larger sample size is required and

a control group exposed to the same number of treatment sessions is needed. Due to better improvement in acne scarring (mean rank 57.15 vs. 14) and less difference in healing period (mean rank 38 vs. 34) observed in the medium dose (18 mg/day) of isotretinoin with the fractional CO<sub>2</sub> laser compared to fractional CO<sub>2</sub> laser treatment the only group, we suggested that the synchronous use of medium dose of isotretinoin and the fractional CO<sub>2</sub> laser was the excellent choice for the future treatment regime.

Limitations of our study were the small sample size, a difference in treatment session and lack of histological examination to objectively evaluate the wound healing process after laser treatment. Further study required for large sample size, the same number of treatment sessions as well as histopathological evaluation for the valuable evidence.

Our study also identifies independent factors associated with the synchronous use of isotretinoin and fractional CO<sub>2</sub> laser in patients with acne, which may be beneficial as a suggestion for newer acne treatment. However, further controlled clinical trials are needed to confirm these observations.

## Conclusions

In summary, we showed that we could treat acne and acne scars more effectively by synchronous use of the fractional CO<sub>2</sub> laser with the low, medium and high dose of oral isotretinoin. Among all groups, fractional CO<sub>2</sub> laser with medium-dose isotretinoin showed satisfactory improvement in acne scarring, normal wound healing, and neither atrophic scars nor keloids were observed. Grade of acne, doses of isotretinoin, No of the treatment session, % of MTZ applied during the session, level of MTZ and passes per session was the factor associated with synchronous use of isotretinoin and fractional CO<sub>2</sub> laser for acne patients. As a dermatologist, we must reevaluate the traditional belief to wait for at least 6 months for laser therapy after completion of oral isotretinoin treatment for acne scar. This widely accepted recommendation is likely more influenced by medicolegal concerns than actual evidence-based studies, preventing acne scar patients from receiving early and effective laser treatments.

## Acknowledgments

We are heartily thankful to Dr Trusha Gajjar and Dr Jitesh Kalkot for technical support.

**Conflicts of interest:** None.

**Abbreviations:** MJ: Mili Joule, MTZ: Microthermal damage zone

## References

- Thappa D, Adityan B, Kumari R. Scoring systems in acne vulgaris. *Indian J Dermatol Venereol Leprol* 2009;75(3):323-6.
- Zahra Ghodsi SZ, Orawa H, Zouboulis CC. Prevalence, severity, and severity risk factors of acne in high school pupils: a community-based study. *J Invest Dermatol* 2009;129(9):2136-41.
- Cunliffe WJ, Gould DJ. Prevalence of facial acne vulgaris in late adolescence and in adults. *BMJ*. 1979;1(6171):1109-10.
- Levy LL, Zeichner JA. Management of acne scarring, Part II. *Am J Clin Dermatol* 2012;1;13(5):331-40.
- Hession MT, Graber EM. Atrophic acne scarring: a review of treatment options. *J Clin Aesthet Dermatol* 2015;8(1):50-8.
- Driscoll MS, Rothe MJ, Abrahamian L, Grant-Kels JM. Long-term oral antibiotics for acne: is laboratory monitoring necessary? *J Am Acad Dermatol* 1993;28(4):595-02.
- Lucky AW, Henderson TA, Olson WH, Robischb DM, Lebwohl M, et al. Effectiveness of norgestimate and ethinyl estradiol in treating moderate acne vulgaris. *J Am Acad Dermatol* 1997;37(5)(5 Pt 1):746-54.
- Accutane-side-effects-drug-center. <https://www.rxlist.com/accutane-side-effects-drug-center.htm#overview.htm>.
- Goihman-Yahr M, Peteiro C, Toribio J. Keloid formation induced by isotretinoin therapy. *Int J Dermatol* 1999;38(3):228-9.
- Zachariae H. Delayed wound healing and keloid formation following argon laser treatment or dermabrasion during isotretinoin treatment. *Br J Dermatol* 1988;118(5):703-6.
- Osofsky MG, Strauss JS. Isotretinoin. In: Shalita AR, Del Rosso JQ, Webster GF, eds. *Acne Vulgaris*. London: Informa Healthcare; 2011:134-45.
- Prather HB, Alam M, Poon E, Arndt KA, Dover JS. Laser safety in isotretinoin use. *Dermatol Surg* 2017;43(3):357-63.
- Chandrashekar BS, Varsha DV, Vasanth V, Jagadish P, Madura C. Safety of performing invasive acne scar treatment and laser hair removal in patients on oral isotretinoin: a retrospective study of 110 patients. *Int J Dermatol* 2014;53(10):1281-5.
- Yoon JH, Park EJ, Kwon IH, Kim CW, Lee GS. Concomitant use of an infrared fractional laser with low-dose isotretinoin for the treatment of acne and acne scars. *J Dermatol Treat* 2014;25(2):142-6.
- Leal H, Cantu P. Fractionated erbium laser during oral isotretinoin treatment. *J Am Acad Dermatol* 2011;64(2). DOI: 10.1016/j.jaad.2010.09.096. Accessed April 12, 2017.
- Bower KS, Woreta F. Update on contraindications for laser-assisted in situ keratomileusis and photorefractive keratectomy. *Curr Opin Ophthalmol* 2014;25(4):251-7.
- Fekrat S, de Juan E Jr, Campochiaro PA. The effect of oral 13-cis-retinoic acid on retinal redetachment after surgical repair in eyes with proliferative vitreoretinopathy. *Ophthalmol* 1995;102(3):412-8.
- Chang YC, Hu DN, Wu WC. Effect of oral 13-cis-retinoic acid treatment on postoperative clinical outcome of eyes with proliferative vitreoretinopathy. *Am J Ophthalmol* 2008;146(3):440-6.
- Goodman GJ, Baron JA. Post acne scarring: a qualitative global scarring grading system. *Dermatol Surg* 2006. View at Publisher. View at Google Scholar. View at PubMed. View at Scopus;32(12):1458-66.
- Holm S. A simple sequential rejective method procedure. *Scand J Stat* 1979;6:65-70 69.
- Gaetano J. Holm-Bonferroni sequential correction: an Excel calculator (1.3). Microsoft EXCEL Workbook. [https://www.researchgate.net/publication/322568540\\_Holm-BonferronisequentialcorrectionAn\\_Excel\\_calculator\\_13](https://www.researchgate.net/publication/322568540_Holm-BonferronisequentialcorrectionAn_Excel_calculator_13). 2018.
- Kurokawa I, Danby FW, Ju Q, Wang X, Xiang LF. New developments in our understanding of acne pathogenesis and treatment. *Exp Dermatol* 2009;18(10):821-32.
- Fabbrocini G, Annunziata MC, D'Arco V, DeVita V, Lodi G. Acne scars: pathogenesis, classification and treatment. *Dermatol Res Pract* 2010;2010:893080.

24. Baum CL, Arpey CJ. Normal cutaneous wound healing: clinical correlation with cellular and molecular events. *Dermatol Surg* 2005;31(6):674-86; discussion 686.
25. Oikarinen AI, Uitto MD. Retinoid modulation of connective tissue metabolism in keloid fibroblast cultures. *Arch Dermatol* 1985;121:632-5.
26. Hantash BM, Bedi VP, Kapadia B, Rahman Z, Jiang K. In vivo histological evaluation of a novel ablative fractional resurfacing device. *Lasers Surg Med* 2007;39(2):96-07.
27. Sakamoto FH, Doukas AG, Farinelli WA, Tannous Z, Shinn M. Selective photothermolysis to target sebaceous glands: Theoretical estimation of parameters and preliminary results using a free electron laser. *Lasers Surg Med* 2012;44(2):175-83.
28. Altshuler GB, Anderson RR, Manstein D, Zenzie HH, Smirnov MZ. Extended theory of selective photothermolysis. *Lasers Surg Med* 2001;29(5):416-32.

**How to cite this article:** Sakhiya J, Sakhiya D, Dedakiya A, Modi M, Daruwala F, Efficacy and safety of synchronous use of the fractional carbon dioxide. *Indian J Clin Exp Dermatol* 2019;5(2):103-110.