

Comparative study of efficacy of topical amorolfine, luliconazole, sertaconazole, terbinafine in tinea corporis and tinea cruris

Vishal Agrawal¹, Manjunath Shenoy M^{2,*}, Malcolm Pinto³, Amina Asfiya M I⁴, Spandana Hegde⁵

¹Post Graduate IIIrd Year, ²Professor and HOD, ^{3,5}Assistant Professor, ⁴Senior Resident, ¹⁻⁵Dept. of Dermatology, ¹⁻⁵Yenepoya Medical College, Yenepoya (Deemed to be University) Mangalore, Karnataka, India

*Corresponding Author: Manjunath Shenoy M

Email: manjunath576117@yahoo.co.in

Abstract

Introduction: Dermatophytosis is the superficial fungal infection of keratinized tissue. Topical antifungals are exclusively used for localized lesions of dermatophytosis among which amorolfine, luliconazole, sertaconazole and terbinafine are relatively newer molecules.

Aim of the study: To study the therapeutic efficacy and safety of amorolfine, luliconazole, sertaconazole, terbinafine in patients with tinea corporis or cruris.

Materials and Methods: A prospective comparative study of the patients who have been clinically diagnosed to have localized tinea corporis or cruris was carried out. A total of 80 patients were included with 20 patients each were prescribed topical amorolfine, luliconazole, sertaconazole and terbinafine in a serial order. Objective evaluation of improvement based on pruritus, erythema and scaling was performed. Amorolfine and luliconazole was advised to apply once daily while sertaconazole and terbinafine to be applied twice daily.

Results: Out of 20 patients each, 18 patients in Amorolfine group, 19 in Luliconazole group, 15 patients each in Sertaconazole group and Terbinafine group followed up at the end of 3 weeks. Mean age was found to be 34 years with slight male preponderance. Luliconazole showed best improvement of pruritus, erythema and scaling. Terbinafine showed the least improvement. More number of patients on luliconazole (12 out of 19) showed good improvement of clinical parameters and this finding was also statistically significant (*P* value-0.018).

Conclusion: Luliconazole may act like a fungicidal antifungal and scores over other 3 topical antifungals, however studies involving larger number is required to confirm these findings.

Keywords: Tinea corporis, Tinea cruris, Topical antifungal.

Introduction

Dermatophytosis is commonly designated as tinea, is caused by keratinophilic fungi called as dermatophytes. Infection is generally limited to the superficial layers of the epidermis, particularly the stratum corneum and the high keratin concentration containing appendageal structures, namely hair and nails. Dermatophytes are classified in three genera-*Epidermophyton*, *Trichophyton* and *Microsporum*. Tinea corporis and tinea cruris refer to the dermatophytic infections of the glabrous skin of the body (excluding palms and soles) and groins respectively. Topical antifungals are exclusively used for localized lesions of dermatophytosis. Amorolfine, luliconazole, sertaconazole and terbinafine are relatively newer molecules which seem to have certain advantages over the older molecules. Topical daily antifungal therapy is considered generally as the first line therapy for dermatophytosis owing to their high efficacy and low potential for side effects. Terbinafine is a fungicidal allylamine that inhibits squalene epoxidase that results in intracellular accumulation of toxic squalene and causes fungal cell death. Luliconazole and sertaconazole are azoles antifungals that block lanosterol 14- α demethylase which prevents the formation of ergosterol.¹ Luliconazole is a novel imidazole antifungal and is uniquely characterized by its R-enantiomer side chain in addition to one chiral center. The addition of an imidazole moiety into the ketene dithioacetate structure of the compound augments its ability to target filamentous fungi.² Sertaconazole has fungistatic and fungicidal mechanism by indirect inhibition of ergosterol synthesis and direct inhibition of non sterol

component of fungal cell membrane leading to rapid leakage of key intracellular components and immediate cell death. It also mediates its anti-itch effects by increasing prostaglandin D2 levels in mast cells and macrophages through induction of the p38 mitogen-activated protein kinase pathway.^{3,4} Amorolfine, a morpholine derivative, is the first of a new class of antifungal drugs. The mechanism of action is inhibition of ergosterol biosynthesis in the fungal cell membrane by blocking enzymes delta 14 reductase and delta 7-8 isomerase.⁵

Materials and Methods

It was a prospective, randomized, open-labeled, parallel group study. It was a pragmatic study to assess the therapeutic response to certain topical antifungals in the current scenario of dermatophytosis. Clinically diagnosed healthy adult patients with tinea corporis and tinea cruris requiring topical antifungal therapy were selected for the study. Patients aged 18 years or above with localized tinea corporis or cruris without any form of prior treatment for atleast a week were chosen. Recurrent, steroid modified and partly treated tinea infections were also recruited in order to represent the current scenario. A detailed history including the duration of disease, associated medical conditions, treatment history and family history were taken. An arbitrary sample size of 80 was considered with 20 patients in each category of antifungal was considered.

Location of lesion, morphology and symptoms were noted. Scrapings from the edge and/or from the scaly area of the lesions were taken. Potassium hydroxide mount (KOH

Mount) followed by direct microscopy was undertaken at the beginning of treatment to confirm the diagnosis but not repeated at the end of treatment since clinical improvement rather than a cure was the primary objective of the study. Consecutive eligible patients were prescribed topical amorolfine (0.25%), luliconazole (1%), sertaconazole (2%) and terbinafine (1%) in a serial order. Same brand of the topical drug was used throughout the period of study. Amorolfine and luliconazole were advised once daily while sertaconazole and terbinafine was twice daily application. They were asked to apply as a thin layer directly to the lesions and also a small area beyond the lesions. Response to treatment was assessed after 3 weeks with no follow-up visit. We evaluated the improvement in the pruritus, erythema and scaling with score 0 for no improvement, score 1 for partial improvement and score 2 for complete improvement. Therapeutic response was statistically evaluated using Kruskal Wallis test and Fishers exact test.

Clinical images of consented patients were taken at starting of therapy and at 3 weeks with due care that the patient's identity was not revealed. Antihistamine tablet levocetirizine 5 mg at bed time was given for 7 days to all patients as an anti-pruritic medication.

Results

Among the total 80 patients, 67 reported at the 3 week follow up. Among them 30 were treatment naive, 16 were

topical steroid (with or without antifungal) modified cases, 14 were partially treated with antifungals and 7 had used home remedies prior to the study (Table 1). Mean age of these patients was 34 year with youngest being 18 years and oldest 70 years. Male to female (35 versus 32) ratio was 1.1:1. We had 13 drop outs despite telephonically contacting the patients for follow up.

Luliconazole showed best improvement of pruritus (mean-1.47), erythema (mean-1.53) and scaling (mean-1.53). Terbinafine showed the least improvement with mean being 0.73, 0.60, 0.67 for pruritus, erythema and scaling respectively.[Table 2] Difference in the mean values of improvement of luliconazole as compared to the other three drugs was significant for pruritus ($P = 0.020$) and highly significant for erythema and scaling ($P = 0.004$ & 0.007) (calculated using Kruskal Wallis test).

Based on the improvement of all three parameters, we categorized the patients into three groups. [Table 3] Total value of improvement in pruritus, erythema and scaling were calculated and patients were grouped into poor response (total score- 0, 1 & 2), moderate response (total score-3 & 4) and good response (total score- 5 & 6). A total of 12 patients (66%) in luliconazole group showed good response as compared to the other drugs. These differences in the improvement of patients was statistically significant as compared to other drugs ($P = 0.018$, Fisher's exact test).

Table 1: Previous topical treatment

Group	Naive	Steroid	Antifungal	Others
Amorolfine	5	8	3	2
Luliconazole	9	3	6	1
Sertaconazole	8	3	2	2
Terbinafine	8	2	3	2
Total	30	16	14	7

Table 2: Comparison between pruritus, erythema & scaling

Parameters	Group	N	Mean	P value	Sig
Pruritus	Amorolfine	18	1.06	.020	Sig
	Luliconazole	19	1.47		
	Sertaconazole	15	1.13		
	Terbinafine	15	0.73		
Erythema	Amorolfine	18	0.89	.004	Hs
	Luliconazole	19	1.53		
	Sertaconazole	15	1.13		
	Terbinafine	15	0.60		
Scaling	Amorolfine	18	0.83	.007	Hs
	Luliconazole	15	1.53		
	Sertaconazole	19	1.20		
	Terbinafine	18	0.67		
Total	Amorolfine	18	2.78	.009	Hs
	Luliconazole	19	4.53		
	Sertaconazole	15	3.47		
	Terbinafine	15	2.00		

Table 3: Group comparison of drugs

Response	Amorolfine		Luliconazole		Sertaconazole		Terbinafine	
	N	%	N	%	N	%	N	%
Poor	7	38.9	2	10.5	3	20.0	7	46.7
Moderate	7	38.9	5	26.3	7	46.7	7	46.7
Good	4	22.2	12	63.2	5	33.3	1	6.7
Total	18	100.0	19	100.0	15	100.0	15	100.0

N= Number of patients
 Poor = Total scores 0,1,2, Moderate = Total scores 3,4, Good = Total scores 5,6

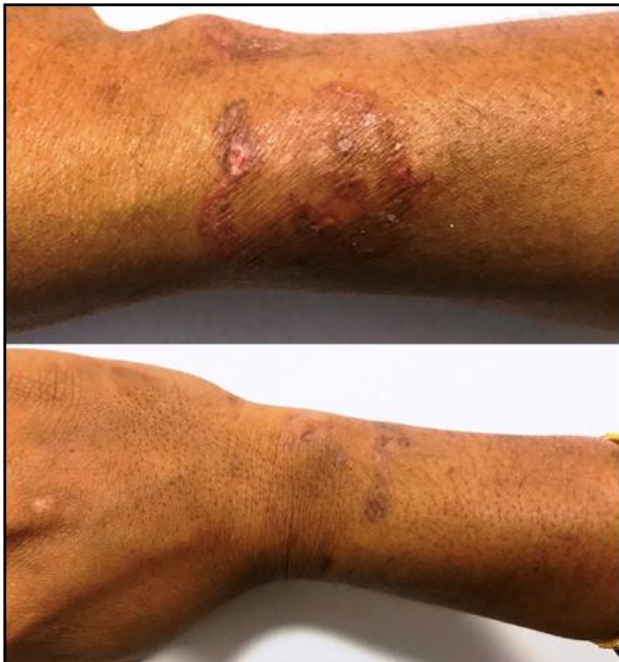

Fig. 1: Amorolfine topical therapy showing improvement at the end of 3 weeks

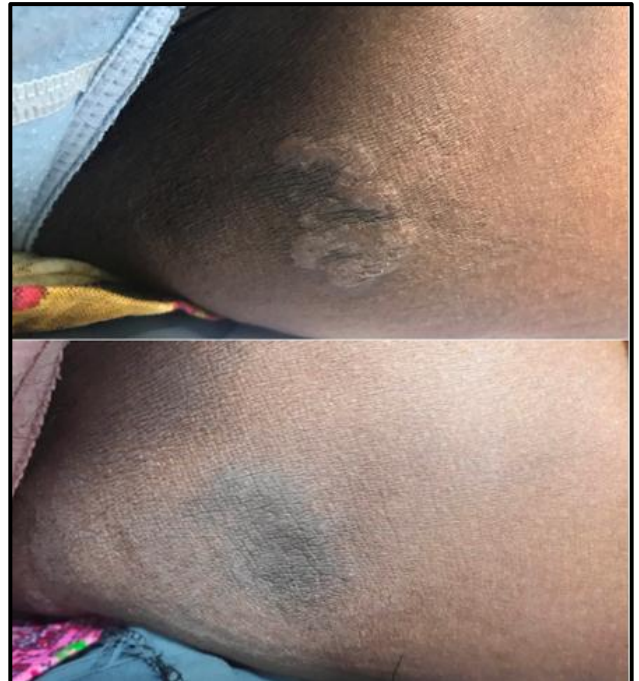

Fig. 3: Sertaconazole topical therapy showing improvement at the end of 3 weeks

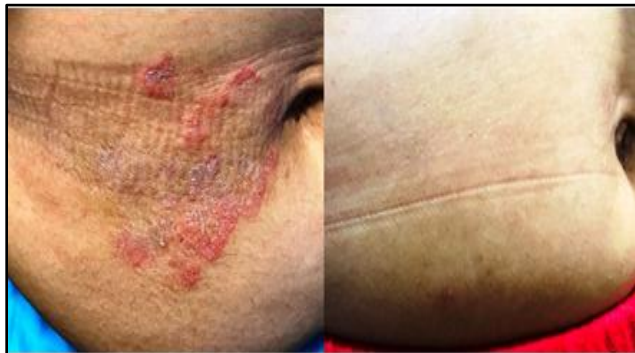

Fig. 2: Luliconazole topical therapy showing improvement at the end of 3 weeks

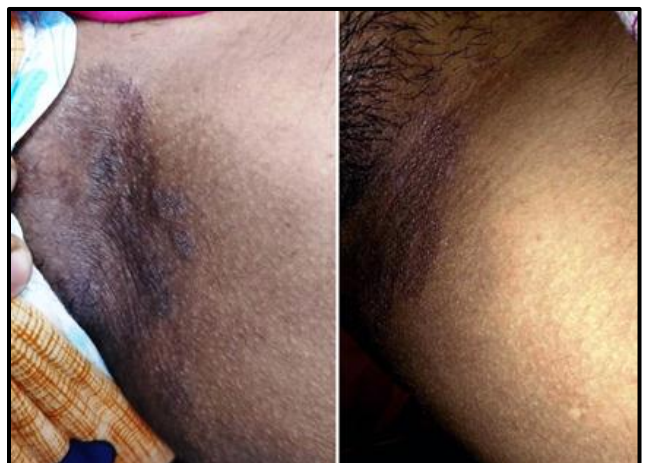


Fig. 4: Terbinafine topical therapy showing improvement at the end of 3 weeks

Discussion

Topical antifungal therapy is the mainstay in the treatment of dermatophytosis; however increased number of extensive infections in the recent times has been a limiting factor. Newer topical antifungals seem to have certain advantages over the older drugs.⁶ Dermatologist treating dermatophytosis has less information about the efficacy of the currently available topical therapies. Current epidemic of dermatophytosis is complicated by an increased number of chronic and recurrent dermatophytosis.⁷ Topical steroid abuse also seems to be a major contributor to the onslaught of extensive and treatment resistant cases.⁸ There has also been a shift in the dominant pathogen responsible for the infections across India from *Trichophyton rubrum* to *Trichophyton mentagrophytes*.⁹ Thus current circumstances are different than a decade ago and we need more information about the response to the therapeutic agents.

We conducted this study in 80 adult patients but only 67 completed the study. There was almost equal number of patients in both genders and the sample represented almost all age groups. Only 30 patients were treatment naive. Others used some form treatment that included topical steroids with or without antifungal (16 patients) or antifungal alone (14) which were bought over the counter (OTC) or prescribed by the local practicing doctors. We found less OTC drug usage in our patients compared to another study but still it was sizable.¹⁰

We found that the topical antifungals were effective in majority of the patients, although variable response was seen. Best response at the end of 3 weeks of topical therapy was shown by luliconazole for all three parameters pruritus, erythema and scaling, and the results were statistically significant. Jerajani et al conducted almost a similar study and found sertaconazole exhibiting better response than luliconazole and terbinafine.³ Another study conducted by Choudhary et al showed equal efficacy between sertaconazole and terbinafine.¹¹

Improvement was assessed on the basis of total score and 3 groups were made. Out of which luliconazole had 12 patients with good response followed by sertaconazole (5), amorolfine (4) and terbinafine (1) least. This indicates that luliconazole could be the most effective topical antifungal as compared to the other three currently available drugs. This high efficacy may be due to its low MIC as compared to certain other antifungals for *T. rubrum* and *T. mentagrophytes*. There seem to be a poor response to the fungicidal drug terbinafine which could be due to various factors that may include drug resistance.¹²

Strength of this study lies in replicating the current scenario of dermatophytosis in the study by including naïve as well as partially treated or mistreated cases. We compared currently available relatively new molecules whose efficacy is less known in the current Indian scenario. Limitation of the study lies in the recruitment of less number of cases. This is primarily due to lesser availability of suitable cases that require only topical treatment despite a large load of dermatophytosis in the daily dermatological practice. Result obtained in the study needed to be validated

with inclusion of large number of cases with a better design that could include blinding of the dispensed drug.

Conclusion

We believe that Luliconazole may score over other 3 topical antifungals, however studies involving larger number is required to confirm these findings. Although it belongs to azole class, it seems to exhibit fungicidal activity.¹³ This study also signifies the role of topical antifungal alone in treating limited tinea corporis and cruris, thus boosting the confidence on topical therapy. Newer topical antifungals are more expensive and hence pharmaco-economical analysis should also be considered while prescribing them.¹⁴ Topical antifungal therapies can also have a synergy or additivism with systemic antifungals.¹⁵ Hence topical antifungals are the integral part of management of the glabrous tinea infections.

Conflict of Interest: None.

References

1. Sumyuktha J, Narasimhan M, Ahamed PB. A comparative trial between the therapeutic efficacy of topical 2% sertaconazole cream and 1% terbinafine cream in the treatment of tinea cruris/tinea corporis. *Int J Res Dermatol* 2017;3:59-63.
2. Gupta AK, Daigle D. A critical appraisal of once-daily topical luliconazole for the treatment of superficial fungal infections. *Infect Drug Resist* 2016;18:1-6.
3. Jerajani HR, Janaki C, Kumar S, Phiske M. Comparative assessment of the efficacy and safety of sertaconazole (2%) cream versus terbinafine cream (1%) versus luliconazole (1%) cream in patients with dermatophytoses: A pilot study. *Indian J Dermatol* 2013;58:34-8.
4. Ständer S, Metz M, Ramos F MH, Maurer M, Schoepke N, Tsianakas A, et al. Anti-pruritic Effect of Sertaconazole 2% Cream in Atopic Dermatitis Subjects: A Prospective, Randomized, Double-blind, Vehicle-controlled, Multi-centre Clinical Trial of Efficacy, Safety and Local Tolerability. *Acta DermVenereol* 2016;96:792-6.
5. Banerjee M, Ghosh AK, Basak S, Das KD, Gangopadhyay DN. Comparative evaluation of effectivity and safety of topical amorolfine and clotrimazole in the treatment of tinea corporis. *Indian J Dermatol* 2011;56:657-62.
6. Sahni K, Singh S, Dogra S. Newer topical treatments in skin and nail dermatophyte infections. *Indian Dermatol Online J* 2018;9:149-58.
7. Dogra S, Uprety S. The menace of chronic and recurrent dermatophytosis in India: Is the problem deeper than we perceive?. *Indian Dermatol Online J* 2016;7:73-6.
8. Verma S, Madhu R. The great Indian epidemic of superficial dermatophytosis: An appraisal. *Indian J Dermatol* 2017;62:227-36.
9. Mala MS. Mellow to the malicious: Could *Trichophyton mentagrophytes* be the malefactor?. *Clin Dermatol Rev* 2017;1(S1):1-2.
10. Dabas R, Janney MS, Subramaniyan R, Arora S, Lal V S, Donaparthi N et al. Use of over-the-counter topical medications in dermatophytosis: A cross-sectional, single-center, pilot study from a tertiary care hospital. *Indian J Drugs Dermatol* 2018;4:13-7.
11. Choudhary SV, Bisati S, Singh AL, Koley S. Efficacy and safety of terbinafine hydrochloride 1% cream vs. sertaconazole nitrate 2% cream in tinea corporis and tinea cruris: A

- comparative therapeutic trial. *Indian J Dermatol* 2013;58:457-60.
12. Rudramurthy SM, Shankarnarayan SA, Dogra S, Shaw D, Mushtaq K, Paul RA, et al. Mutation in the Squalene Epoxidase Gene of *Trichophyton interdigitale* and *Trichophyton rubrum* Associated with Allylamine Resistance. *Antimicrob Agents Chemother* 2018;26:62(5). pii: e02522-17.
 13. Khanna D, Bharti S. Luliconazole for the treatment of fungal infections: an evidence-based review. *Core Evid* 2014;9:113-24.
 14. Rotta I, Ziegelmann PK, Otuki MF, Riveros BS, Bernardo NL, Correr CJ et al. Efficacy of topical antifungals in the treatment of dermatophytosis: a mixed-treatment comparison meta-analysis involving 14 treatments. *JAMA Dermatol* 2013;149(3):341-9.
 15. Gupta AK1, Kohli Y. In vitro susceptibility testing of ciclopirox, terbinafine, ketoconazole and itraconazole against dermatophytes and nondermatophytes, and in vitro evaluation of combination antifungal activity. *Br J Dermatol* 2003;149(2):296-05.

How to cite this article: Agrawal V, M MS, Pinto M, Amina AMI, Hegde S, Comparative study of efficacy of topical amorolfine, luliconazole, sertaconazole, terbinafine in tinea corporis and tinea cruris. *Indian J Clin Exp Dermatol* 2019;5(2):111-115.