

# Human papilloma virus (HPV) infection as an etiological factor in malignant sinonasal neoplasms and nasopharyngeal carcinomas: A pathologist's perspective

Carol Fernandes<sup>1</sup>, Farhana Zakaria<sup>2,\*</sup>

<sup>1,2</sup>Assistant Professor, Dept. of Pathology, <sup>1</sup>Kanachur Institute of Medical Sciences, Mangalore, Karnataka, <sup>2</sup>Srinivas Institute of Medical Sciences, Mangalore, Karnataka, India

\*Corresponding Author: Farhana Zakaria

Email: farhazak@gmail.com

Received: 8<sup>th</sup> October, 2018

Accepted: 10<sup>th</sup> November, 2018

## Abstract

**Introduction:** Role of Epstein-Barr virus (EBV) infection as an etiological agent in nasopharyngeal carcinoma (NPC) of type III and type II is well known. But there are not many studies showing association between NPCs and human papilloma virus (HPV). We undertook this study to identify the relationship between HPV and NPCs by histopathology & immunohistochemistry by using HPV antibodies against HPV types 6, 11 and 18.

**Objectives:** To identify the rate of HPV infection in malignant sinonasal tumours and nasopharyngeal carcinomas (NPCs) by using histopathology and immunohistochemistry (IHC).

**Materials and Methods:** 21 samples from patients with histopathologically confirmed malignant sino nasal tumours and NPCs were studied. Twelve samples were arising from nasopharynx and nine from nasal cavity. Tumours were classified histopathologically according to WHO criteria. Findings of HPV infection like koilocytic changes and HPV antigen positivity by IHC were noted in all the samples.

**Results:** Moderately differentiated squamous cell carcinoma was commonest of the malignant nasopharyngeal tumours which comprised of 38.09% followed by undifferentiated carcinomas 19.04%, poorly differentiating carcinomas 14.2%, inverted papilloma with carcinoma and adenoid cystic carcinoma 9.6% each and 4.8% each of acinic cell carcinoma and sarcomatoid carcinoma. HPV involvement was seen in 47.61% of cases.

**Conclusion:** HPV infection was identified in 75% of moderately differentiated squamous cell carcinomas and 33.3% cases of poorly to undifferentiated cases of NPC.

**Keywords:** Nasopharyngeal carcinoma, Papilloma, Human papilloma virus, Immunohistochemistry.

## Introduction

In 20% to 76% of sinonasal papillomas, Human Papilloma Virus (particularly HPV 6 and 11) have been documented. Studies using techniques of immunopathology and modern molecular biology have detected HPV in 25% of nasopharyngeal keratinising squamous cell carcinoma.<sup>1</sup> Using various molecular techniques, previous studies have demonstrated that HPV 16 was related to malignant change in inverted papillomas of nasal cavity.<sup>2,3</sup> HPV has been classified into more than 60 types by molecular techniques and shown to be implicated in various neoplastic lesions.<sup>4-6</sup>

Nasopharyngeal carcinomas (NPCs) of the non-keratinizing and undifferentiated type are associated with infection of Epstein-Barr virus.<sup>7</sup> The role of HPV in the development of NPC has not been studied in detail.

Hence, this study is undertaken to identify the role of HPV infection as an etiologic agent in malignant neoplasm's of nasal cavity and the nasopharynx by histopathology & immunohistochemistry using cocktail of HPV antibodies against HPV types 6, 11 and 18. The presence of koilocytes in the epithelium in carcinoma and papillomas and presence of HPV antigens in both benign and malignant tumours support the role of HPV virus as an etiologic agent in nasopharyngeal tumours.

This study has a role in the management because it has a clinical implication in the treatment of HPV related benign and malignant sinonasal tract lesions and the knowledge can be applied to treat benign papilloma to prevent its

transformation to malignant tumour. The detection and definition of factors that allow a prognosis of recurrence or malignant transformation of papilloma and detection of papilloma virus in benign and malignant epithelial tumours which gives the extent of risk of malignant transformation is an active field of research.

The objective of this study was to assess the presence of HPV viruses in malignant epithelial tumour cells, to identify the risk of transformation of epithelial cells infected with low risk virus into malignant cells and to estimate the overall risk of malignancy in HPV infection in a south Indian tertiary care hospital.

## Materials and Methods

During the period from May 2006 to April 2013, a total of 38 specimens of nasal papillomas and nasopharyngeal carcinomas were studied. The formalin-fixed tissue biopsies were processed<sup>8</sup> and stained with haematoxylin and eosin stain. Sections were then studied under light microscope and were classified into benign (Schneiderian papillomas) and malignant (carcinomas).<sup>8</sup>

H & E stained slides of 21 malignant samples were studied for categorization of the tumours, for koilocytic and other cytological changes of HPV infection. Then all malignant samples were subjected to immunohistochemistry for HPV antigen detection by using cocktail of Novocastra Lyophilized Mouse Monoclonal Antibody Papilloma virus (Types 6, 11, 18) - [Leica Microsystems]

Information regarding age, sex, site and histological types were recorded.

## Results

When compared between benign and malignant, benign constituted 17 (44.73%) cases and malignant constituted 21 (55.26%) showing the tendencies of HPV infections towards malignancy.

In the current observation of the 21 malignant cases, we found the demographic parameter in which males were 14 (36.84%) and female were 7 (18.42%) showing the incidence and risk in males is twice as compared to females.

Among specific site affected, nasal cavity constituted 6 (15.78%) in males and 3 (7.89%) in females. In terms of nasopharynx, 8 (21.05%) cases were seen in males and 4 (10.52%) cases were seen in females. This indicates the most vulnerable site for both males and females is nasopharynx than nasal cavity which is a matter of concern.


In our study we found, two (5.26%) cases of inverted papilloma with poorly differentiated carcinoma (PDC), 2 cases of poorly differentiated carcinoma of nasopharynx and 2 cases of moderately differentiated squamous cell carcinoma (MDSCC) of nasal cavity in males. There was one (2.63%) case each of undifferentiated carcinoma of nasopharynx, sinonasal undifferentiated carcinoma and adenoid cystic carcinoma in males. MDSCC cases of nasopharynx were 5 (13.15%) in males, showing higher incidence than other malignancies (Table 1).

In case of females, there were 2 (5.26%) cases of undifferentiated carcinoma of nasopharynx and one (2.63%) case each of sarcomatoid carcinoma, acinic cell carcinoma, poorly differentiated carcinoma of nasopharynx, adenoid cystic carcinoma, MDSCC of nasopharynx (Table 2).

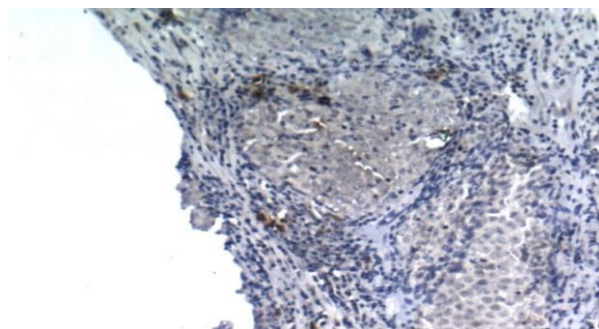
Koilocytes were present in one (2.63%) case of inverted papilloma with PDC with focal positive for HPV antigen (Fig. 1) and in other case (2.63%) of the same, koilocytes was not seen and was negative for HPV antigen. There was absence of koilocytes and HPV antigen was also negative in one (2.63%) case each of undifferentiated carcinoma of nasopharynx and poorly differentiated carcinoma of nasopharynx, but one (2.63%) case of sinonasal undifferentiated carcinoma showed absence of koilocytes but focal positive for HPV antigen (Fig. 2). One (2.63%) case of poorly differentiated carcinoma of nasopharynx, showed absence of koilocytes (no normal epithelium) and negative for HPV antigen. In moderately differentiated squamous cell carcinoma, one (2.63%) case showed focal presence of koilocytes and in other (2.63%) koilocytes were present in mucosa of tumour, but both the cases showed positive (diffuse) for HPV antigen. In the only one case of adenoid cystic carcinoma (2.63%) in males koilocytes were absent but was focal positive for HPV antigen. About 5 (13.15%) cases of MDSCC of nasopharynx (Fig. 3) were seen in males, among which 2 cases (5.26%) did not show koilocytes and were negative for HPV antigen. Of the remaining three, one case of MDSCC of nasopharynx showed presence of koilocytes, one showed focal presence of koilocytes and other didn't show any normal epithelium.

In the first two cases there was diffuse positivity in IHC and in third case there was focal positivity in IHC (Table 3).

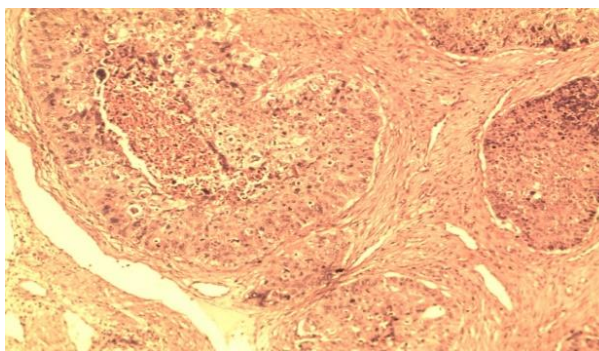
In female cases, koilocytes was not seen in two cases of undifferentiated carcinoma of nasopharynx with diffuse positivity in IHC in one case and negative IHC for HPV antigen in the other. There was one (2.63%) case each of sarcomatoid carcinoma, acinic cell carcinoma and poorly differentiated carcinoma showing absence for koilocytes and negative in IHC for HPV antigen. One (2.63%) case was adenoid cystic carcinoma with koilocytes present (in normal epithelium) and positive (focal) in IHC for HPV antigen and one (2.63%) case of MDSCC of nasopharynx with koilocytes present (in normal epithelium) and negative in IHC for HPV antigen (Table 4).



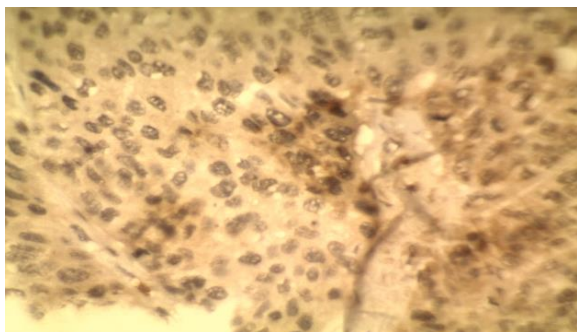
**Fig. 1: Photomicrograph of inverted papilloma with carcinoma showing focal HPV antigen positivity (HPV, 40X)**



**Fig. 2: Photomicrograph of undifferentiating carcinoma showing focal HPV antigen positivity (HPV, 40X)**



**Fig. 3: Microphotograph of moderately differentiating squamous cell carcinoma (H & E, 10X)**



**Fig. 4: Photomicrograph of moderately differentiating squamous cell carcinoma showing focal positivity for HPV antigen (HPV, 40 X)**

### Discussion

Nasopharyngeal carcinoma is the cancer originating in the nasopharynx, most commonly in the postero-lateral nasopharynx. It is endemic in South-East Asia, Middle East, North Africa and Southern China, with annual incidence as high as 1:4000 in some places. In striking contrast, annual incidence is less than 1:100000 in non endemic regions and western countries. It is also a leading cause of death in South-East Asia.<sup>9-11</sup> In Oriental population, cases showing familial aggregates have been reported.<sup>12</sup>

There is strong affirmation to suggest that nasopharyngeal carcinomas result from combination of Epstein- Barr Virus, genetic predisposition and environmental factors.<sup>13-15</sup> Initiation of tumorigenesis requires expression of EBV in the cells. But without critical cellular genes induction and maintenance of tumour cell phenotype is not possible.<sup>16</sup> The role of HPV and EBV in the development of the conventional type of squamous cell carcinoma of the nose and paranasal sinuses remains to be clarified. In the study by Du-Bois Asante et al,<sup>17</sup> DNA of HPV was detected in 19.4% of nasopharyngeal carcinoma.

In our previous study<sup>18</sup> we observed 26 cases, among which there were 14 cases of sinonasal papillomas and 12 cases of nasopharyngeal carcinomas. Of the 14 sinonasal papillomas, seven were of inverted and seven were fungiform types. Histological or immunohistochemical evidence of HPV infection was found in 85.5% of inverted papillomas. Fungiform papillomas showed evidence of HPV infection in 100%. Nasopharyngeal carcinomas showed 50% positivity for HPV infection.

In the present study, keratinizing (moderately differentiated) squamous cell carcinoma were more common than non-keratinizing (poorly differentiating carcinoma). Keratinizing carcinomas were an average of 38.09% of cases compared to non-keratinizing carcinomas (poorly differentiated carcinomas) which were only 14.2%. This correlated with the study of Wenig BM.<sup>19</sup> But in the study of Mirzamani et al<sup>20</sup> the incidence of non-keratinizing (poorly differentiated carcinomas) was higher when compared to the keratinizing squamous cell carcinomas.

Undifferentiated carcinomas were less common in our study as compared to the studies of Wenig BM<sup>19</sup> and

Mirzamani et al<sup>20</sup> who had comparatively higher incidence (Table 5).

According to Gaffey et al,<sup>4</sup> inverted papilloma with carcinoma had a low incidence but in our study it was slightly higher.

Majority of the salivary gland neoplasm of sinonasal tract are malignant, but they are not common. In our study we had only two cases of adenoid cystic carcinoma and only a single case of acinic cell carcinoma which supports the claim that nasal salivary gland carcinomas are rare as per literature reports<sup>21</sup>.

Mirzamani et al<sup>20</sup> used in situ hybridization method to examine the presence of Human Papilloma virus and Epstein-Barr Virus in Nasopharyngeal carcinoma. He found the age incidence of nasopharyngeal carcinoma ranged from 21-75 years with a median of 48.3. In our study, mean age of nasopharyngeal carcinomas was 54.5 years which is correlating well with the study of Lathi et al.<sup>15</sup> Mirzamani et al<sup>20</sup> found a slight lower incidence when compared to our study.

In his study, Singhi et al<sup>22</sup> found that 76% of his cases were positive for HPV and he established that immunohistochemistry for p16 is reliable marker for HPV related malignancies and also HPV is accountable for a subset of nasopharyngeal carcinomas.

In our present study, out of the total 21 cases of nasopharyngeal carcinomas, 8 cases were keratinizing squamous cell carcinomas with non-neoplastic epithelium. Out of these 8 cases, five (62.5%) were positive for HPV antigen. Three cases were negative for HPV antigen even though koilocytes were present in one. That means, since either koilocytes or HPV was present in 6 out of the 8 cases, 75% of keratinizing squamous cell carcinomas of nasopharynx had evidence of HPV infection. Since our study didn't contain antibodies against all the HPV types, it can be assumed that cases which were koilocyte positive and HPV antigen negative, may have been infected with other HPV types.

Seven of the total 21 nasopharyngeal carcinomas had no normal epithelium in biopsy. All these cases were poorly or undifferentiated carcinomas. HPV antigen was present in two cases of undifferentiated carcinomas (28.57%). Poorly differentiated carcinomas didn't show HPV antigen. Furuta et al<sup>2</sup> analysed three cases of undifferentiated carcinomas for HPV 16 and 18 and found that HPV was not present in any of them which is not correlating with our study.

In the study by Hording et al,<sup>23</sup> four of the fifteen cases of keratinizing squamous cell carcinoma (25%) were positive for HPV antigen. He had evaluated 38 cases of NPC. But HPV antigen was not seen in any of the poorly differentiated or undifferentiated NPC. Hence he concluded that HPV might not be implicated in poorly differentiated or undifferentiated malignancies. But, as in our study two cases of undifferentiated carcinomas were positive for HPV antigen, we can deduce that HPV may have some role in undifferentiated carcinomas. Our results are consistent with the study of Singhi et al<sup>22</sup> (Table 6, Fig. 5).

Of the remaining 6 cases of nasopharyngeal

carcinomas, one among the two cases of inverted papilloma with carcinoma showed both koilocytes and HPV antigen positivity and this is in agreement with the study by Gaffey et al<sup>4</sup> and Syrjanen et al<sup>24</sup> who also detected HPV 16 positivity in 50% of inverted papilloma with Squamous cell carcinoma.

Tumour cells were positive for HPV antigen in both cases of adenoid cystic carcinomas. Our study complimented the study of Bishop et al<sup>21</sup> in which, all the cases of adenoid cystic carcinomas were positive for HPV. But Furuta et al<sup>2</sup> couldn't detect either p16 or 18 in any of the adenoid cystic carcinomas in his series of four cases.

Acinic cell carcinoma and sarcomatoid carcinoma were seen in one case each and both were negative for koilocytes and HPV antigen.

To sum up, 47.61% cases of nasopharyngeal carcinomas were positive for HPV antigen in our study. This was less when compared to study by Singhi et al.<sup>22</sup> But our positivity rate was more than the other two studies of Mirzamani et al<sup>20</sup> and Hording et al.<sup>25</sup> Since no normal epithelium was seen in some poorly differentiated and undifferentiated NPC, it was difficult to comment on koilocytes. Also since only cocktail of 6, 11 and 18 HPV antigens were utilised we cannot confirm that HPV infection was absent in negative cases. Hence, 47.61% positivity is a significant finding strongly suggesting HPV as one of the etiological agent in nasopharyngeal carcinoma.

**Table 1: Different malignant cases found in males**

Diagnosis	Number of cases	Percentage (%)
Inverted papilloma with PDC	2	5.26
Poorly differentiated Carcinoma of nasopharynx	2	5.26
Moderately differentiated Squamous cell carcinoma of nasal cavity	2	5.26
Undifferentiated carcinoma of nasopharynx	1	2.63
Sinonasal undifferentiated carcinoma	1	2.63
Adenoid cystic carcinoma	1	2.63
MDSCC of nasopharynx	5	13.15

**Table 2: Different malignant cases found in females**

Diagnosis	Number of cases	Percentage (%)
Undifferentiated carcinoma of nasopharynx	2	5.26
Sarcomatoid carcinoma in females	1	2.63
Acinic cell carcinoma in females	1	2.63
Poorly differentiated Carcinoma of nasopharynx	1	2.63
Adenoid cystic carcinoma	1	2.63
MDSCC of nasopharynx	1	2.63

**Table 3: Histopathological diagnosis of malignant cases, koilocytes, IHC for HPV antigen in males**

Histopathological diagnosis malignant cases	Koilocytes	%	IHC for HPV Antigen	%
Inverted papilloma with PDC	Present	2.63	Positive focal	2.63
Inverted papilloma with PDC	Not seen	2.63	Negative	2.63
Undifferentiated carcinoma of nasopharynx	Not seen	2.63	Negative	2.63
Sinonasal undifferentiated carcinoma	Not seen	2.63	Positive focal	2.63
Poorly differentiated Carcinoma of nasopharynx	Not seen	2.63	Negative	2.63
Poorly differentiated Carcinoma of nasopharynx	Not seen (no normal Epithelium)	2.63	Negative	2.63
Moderately differentiated Squamous cell carcinoma	Present (focal)	2.63	Positive (diffuse)	2.63
Moderately differentiated Squamous cell carcinoma	Present (in mucosa of tumour)	2.63	Positive (diffuse)	2.63
Adenoid cystic carcinoma	Not seen (no normal Epithelium)	2.63	Positive (focal)	2.63
MDSCC of nasopharynx	Present	2.63	Positive (diffuse)	2.63

MDSCC of nasopharynx	Present (focal)	2.63	Positive (diffuse)	2.63
MDSCC of nasopharynx	Not seen	2.63	Negative	2.63
MDSCC of nasopharynx	Not seen	2.63	Negative	2.63
MDSCC of nasopharynx	Not seen (no normal Epithelium)		Positive (focal)	

**Table 4: Histopathological diagnosis of malignant cases, koilocytes, IHC for HPV antigen in females**

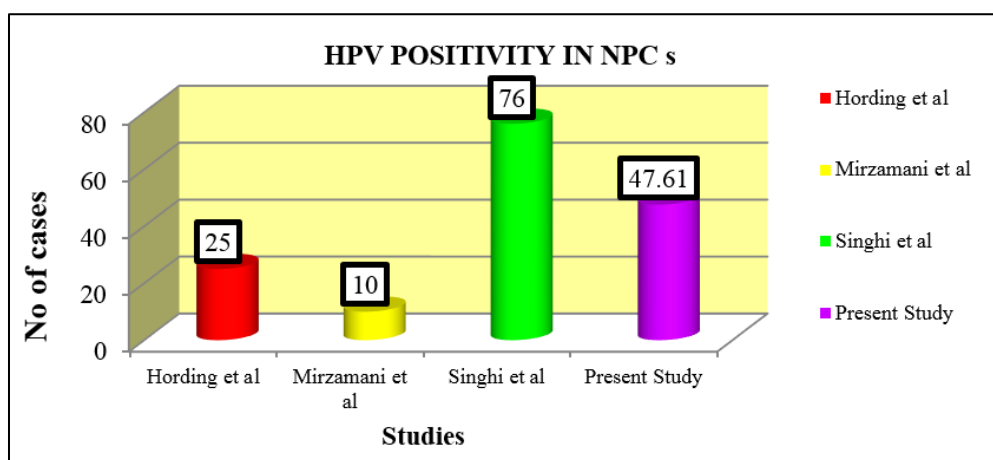
Histopathological diagnosis malignant cases	Koilocytes	%	IHC for HPV Antigen	%
Undifferentiated carcinoma of nasopharynx	Not seen	2.63	Negative	2.63
Undifferentiated carcinoma of nasopharynx	Not seen (no-normal epithelium)	2.63	Positive (diffuse)	2.63
Sarcomatoid carcinoma	Not seen	2.63	Negative	2.63
Acinic cell carcinoma	Not seen	2.63	Negative	2.63
Poorly differentiated Carcinoma of nasopharynx	Not seen	2.63	Negative	2.63
Adenoid cystic carcinoma	Present (in normal Epithelium)	2.63	Positive focal	2.63
MDSCC of nasopharynx	Present (in normal Epithelium)	2.63	Negative	2.63

**Table 5: Comparison of Incidence Nasopharyngeal carcinomas with other studies**

S. No.	Malignant lesions Nasopharyngeal carcinoma	Wenig (2002) <sup>19</sup>	Mirzmani et al (2006) <sup>20</sup>	Present Study %
1	Keratinising SCC	25	5	38.2
2	Non Keratinising Carcinoma	15	20	14.2
3	Undifferentiated Carcinoma	60	75	19.04

**Table 6: Comparison of HPV positive NPCs with other studies**

Authors	Nasopharyngeal Carcinoma HPV positivity
Hording et al (1994) <sup>23</sup>	25%
Mirzamani et al (2006) <sup>20</sup>	10%
Singhi et al (2012) <sup>22</sup>	76%



**Fig. 5: Comparison of HPV positivity of NPCs with other studies**

## Conclusion

We have found higher rate of HPV detection compared to other studies. HPV infection was identified in 75% of moderately differentiated squamous cell carcinomas and 33.3% cases of poorly to undifferentiated cases of NPC.

In the present study even though exact figure of positivity cannot be drawn because of use of antibodies of limited strains of HPV, HPV can be strongly suggested as one of the cause of nasopharyngeal tumours.

**Conflict of Interest:** None.

## References

1. Prat J. Upper respiratory tract. In: Damjanov I, Linder, eds. Anderson's Pathology. 10<sup>th</sup> ed. Missouri: Mosby; 1990:p.1452.
2. Furuta Y, Takasu T., Asai T, Shinohara T, Sawa H, Nagashima K, et al. Detection of Human papilloma virus DNA in carcinoma of the nasal cavities and paranasal sinuses by the polymerase chain reaction. *Cancer* 1992;69:353-7.
3. Barnes L, Tse L.L.Y, Hunt J. L. Nasal cavity and paranasal sinuses. In: Barnes L, Eveson J W, Reichart P, Sidransky D, eds. World Health Organisation Classification of Tumours. Pathology and Genetics of Head and Neck Tumours. Lyon: IARC Press. 2005;9-34
4. Gaffey MJ, Frierson HF, Weiss LM, Barber CM, Baber GB, Stoler MH. Human papilloma virus and Epstein-Barr virus in sinonasal schneiderian papillomas. An in-situ hybridization and polymerase chain reaction study. *Am J Clin Pathol* 1996;106:475-82.
5. Judd R, Zaki SR, Coffield LM, Evatt BL. Sinonasal papillomas and Human papilloma virus. Human papilloma virus 11 detected in Fungi form schneiderian papillomas by in situ hybridization and the polymerase chain reaction. *Human Pathol* 1991;22:550-6.
6. McLachlin CM, Kandel RA, Colgan TJ, Swanson DB, Witteric IJ, Ngan BY. Prevalence of Human papilloma virus in sinonasal papillomas. A study using polymerase chain reaction and in situ hybridization. *Mod Pathol* 1992;5:406-9.
7. Mills SE. The Nose, Paranasal Sinuses and Nasopharynx. In: Mills SE, ed. Sternberg's Diagnostic Surgical Pathology. 5<sup>th</sup>ed. Philadelphia: Lippincott Williams and Wilkins; 2010; p.867-72.
8. Rosai J. Appendix D-Standardized Surgical Pathology Reporting for Major Tumour Types. In: Ackerman Surgical Pathology. 9th ed. Missouri: Mosby 2004;2848-50.
9. Petersson F. Nasopharyngeal carcinoma: a review. *Semin Diagn Pathol* 2015;32:54-73.
10. Mittal KR, Chan W, Demopoulos RI. Sensitivity and specificity of various morphological features of cervical condylomas. An in situ hybridization study. *Arch Pathol Lab Med* 1990;114:1038-41.
11. Colgan TJ, Percy ME, Suri M, Shier RM, Andrews DF, Lickrish GM. Human papilloma virus infection of

morphologically normal cervical epithelium adjacent to squamous dysplasia and invasive carcinoma. *Hum Pathol* 1989;20:316-9.

12. Munoz N, Bosch Z, de Sanjose S. Epidemiologic classification of Human papilloma virus types associated with cervical cancer. *N Engl J Med* 2003; 348:518-27.
13. Zuna RE, Dunn ST, Johnson JJ. HPV genotypes and cervical carcinoma: analysis of 163 cases in a US population. *Lab Invest* 2009;89:243.
14. K.S, M.El. Human Papilloma virus (HPV) Related carcinomas of the upper aerodigestive tract. *Head Neck Pathol* 2007;1:181-5.
15. Lathi A, Syed MMA, Kalakoti P, Qutub D, Kishve SP. Clinico-pathological profile of sinonasal masses: a study from a tertiary care hospital of India. *Acta Otorhinolaryngol Ital* 2011;31:372-7.
16. Eggers G, Muhling J, Hassfeld.S. Inverted papilloma of paranasal sinuses. *J Cranio-Maxillofac Surg* 2007;35:21-9.
17. Asante DB, Asmah RH, Adjei AA, Kyei F, Simpson DL, Brown CA, Gyasi RK. Detection of Human Papilloma virus Genotypes and Epstein-Barr Virus in Nasopharyngeal Carcinomas at the Korle-Bu Teaching Hospital, Ghana. *Sci World J* 2017;1-9.
18. Carol Dsouza, Mah-e-Jabeen, Pushpalatha K. Pai. Human papilloma virus detection by immunohistochemistry on sinonasal papillomas and nasopharyngeal carcinomas: Report on 26 cases. *Arch Med Health Sci* 2013;1(1):10-14.
19. Wenig BM. Squamous cell carcinoma of the Upper Aerodigestive Tract: Precursors and Problematic variants. *Mod Pathol* 2002;15:229-54.
20. Mirzamani N, Salehian P, Farhadi M, Tehran EA. Detection of EBV and HPV in nasopharyngeal carcinoma by in situ hybridization. *Exp Mol Pathol* 2006;81:231-4.
21. Bishop, Justin A, Ogawa. Human Papilloma virus-related Carcinoma with Adenoid Cystic like Adenoid Cystic like Features: A Peculiar variant of Head and Neck Cancer Restricted to the Sinonasal tract. *Am J Surg Pathol* 2013;37:836-44.
22. Singhi AD, Califano J, Westra WH. High risk Human Papilloma virus in nasopharyngeal carcinoma. *Head Neck* 2012;34:213-8.
23. Hording U, Nielsen HW, Daugaard S. Human papilloma-virus types 11 and 16 detected in nasopharyngeal carcinomas by polymerase chain reaction. *Laryngoscope* 1994;204:99-102.
24. Syrjanen KJ. HPV infections in benign and malignant sinonasal lesions. *J Clin Pathol* 2003;56:174-81.

**How to cite this article:** Fernandes C, Zakaria F. Human papilloma virus (HPV) infection as an etiological factor in malignant sinonasal neoplasms and nasopharyngeal carcinomas: A pathologist's perspective. *Indian J Pathol Oncol* 2019;6(2):227-32.