

Metastatic deposits of adenocarcinoma to the vault

Neetu¹, Triveni^{2,*}

¹Senior Resident, ²HOD and Professor, Dept. of Pathology, MNJ Institute of Oncology & Regional Cancer Centre, Hyderabad, Telangana, India

***Corresponding Author: Triveni**

Email: triveni6123@gmail.com

Received: 17th November, 2018

Accepted: 27th November, 2018

Introduction

The majority of metastatic carcinomas to the vagina are from the genital neoplasms followed by extra genital ones.¹ True metastasis to vagina from colonic cancers are rare.² Although rare, few papers have been documented regarding this. We report a case of Metastatic carcinoma of vaginal vault originating from rectal adenocarcinoma that was discovered after a period of 4-6 weeks when the vaginal bleeding became evident.

Case Report

A 60yr old postmenopausal woman was admitted in our hospital for the purpose of evaluation of vaginal bleeding which occurred in 2 episodes in a duration of 3 months. The patient holds a past medical history of (H/O) Rectal adenocarcinoma and a uterine fibroid which was operated upon in February, 2018. CT scan abdomen done preoperatively (without contrast) showed a large, well defined, lobulated, isodense lesion with hyperdense area in left lateral aspect approximately measuring 7x8x7 cm seen in pelvis posterior to uterus and anterior to anterior wall of rectum with rectum and uterus causing significant focus rectal luminal narrowing and anterior compression of uterus suggestive of large exophytic subserosal posterior fibroid

and anterior rectal wall lesion. The patient had undergone hysterectomy and bilateral salpingoophorectomy and segmental resection of intestine. During follow-up of the current admission work up, she was found to have elevated levels of tumour markers CEA (Carcinoembryonic antigen)-9.3ng/ml and CA19.⁹ was measured and found to be within normal limits. Complete blood picture, liver functions tests and renal function tests were performed and found to be within normal limits. HIV and Hepatitis serologic tests were done and seen as non-reactive. Chest X ray was a normal study. CT scan of abdomen showed a growth in vault measuring 5 x 3.8cm. Histopathological examination (HPE) of vault biopsy found a Papillary Adenocarcinoma. That was immunopositive for CD20 & CDX2 and immunonegative for CK7 & p63. HPE slides of intestine were reviewed & found to be well differentiated Adenocarcinoma of Rectum beyond the muscularis propria into perirectal tissues. Uterus, ovaries and fallopian tubes were nil remarkable and free from tumour. Final HPE diagnosis given was Rectal Adenocarcinoma metastatic to the vault. The patient is currently receiving adjuvant chemotherapy.

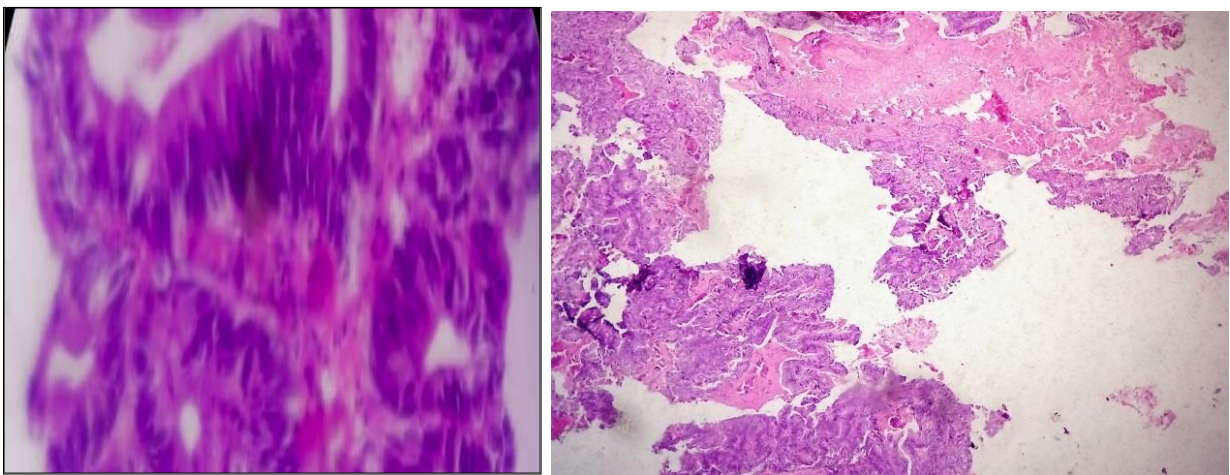


Fig. 1: Metastatic deposits of well differentiated adenocarcinoma with colonic primary to vault-H&E (Scanner view)

Section shows multiple fragments of tumor tissue (ARROW) with extensive necrosis, regular glandular papillary structures with fibrovascular core lined by atypical stratified columnar epithelium (Inset in high power view).

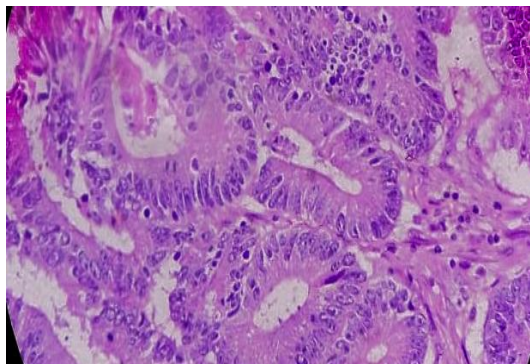


Fig. 2: Well differentiated adenocarcinoma of rectum (High power view)

Section shows tumor tissue arranged in varying histomorphology with regular and irregular sized glands (Arrow in White) lined by atypical columnar epithelium with extensive inflammatory cells (Arrow in Black)

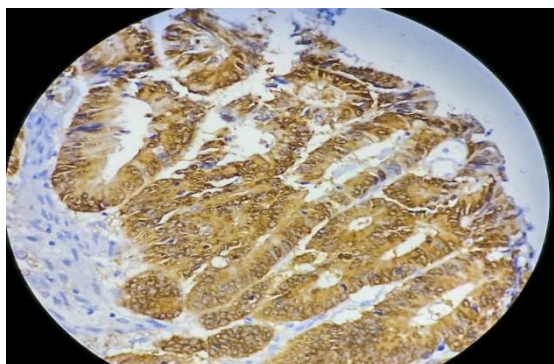


Fig. 3: Diffuse CDX-2 positivity in tumor cells-Low power view (Vault biopsy)

CDX-2 is transcription factor involved in proliferation of intestinal epithelial cells.

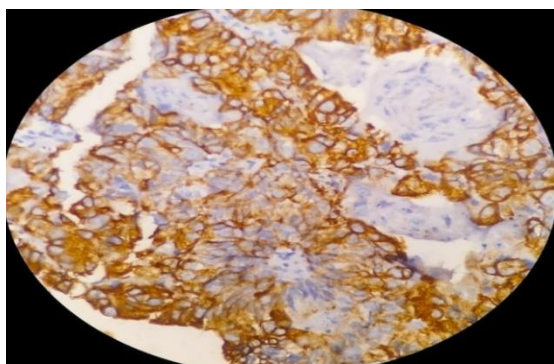


Fig. 4: Diffuse CK 20 positivity in tumor cells-High power view (Vault biopsy)

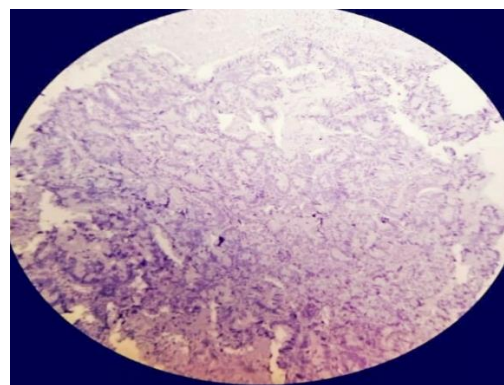


Fig. 5: Lack of expression of CK 7 in tumor cells-scanner view (vault biopsy)

Discussion

It was Whitelaw who documented first in our literatures way back in 1956 that the vaginal lesion if found to be Adenocarcinoma was a metastatic lesion of colorectal cancers.³ Vaginal metastasis is a form of disseminated disease. Primary vaginal malignancies are not common. It constitutes only 2% of all malignant lesions. Vaginal metastasis are majority of vaginal malignancies.⁴ One of the most common clinical symptoms is vaginal bleeding, while other symptoms which can be observed are pelvic pain and presence of vaginal mass.⁵ The origin of vaginal metastasis is based on immunohistochemistry (IHC). Occult carcinomas lead to vaginal bleeding and discharge which are the first clinical manifestations and signs of disseminated metastatic disease⁶ The lower 1/3rd and posterior wall vaginal metastasis arise from gastrointestinal tract (CD7-ve,CD20+ve,CDX2+ve.⁷ Colorectal cancers metastasizes commonly to liver, lung and lymph nodes.⁸⁻¹⁰ Methods of spread are local invasion, transcoelomic, lymphatic & hematogenous.^{4,11} The hematogenous route of spread gives us a better understanding of metastasis to vagina from colorectal cancerous areas due to the venous channels drainage. In the studies conducted earlier, it has been documented for a limited survival rate. Death occurred in the reported cases due to brain metastasis. Control of metastasis is achieved by tumorectomy+administration of adjuvant therapy. As per Ng HJ and Aly EH's study, adjuvant therapy and its effectiveness on survival outcomes is still underway.¹² Usually vagina is a site for metastasis from other female genitourinary tract areas.¹³ The other tumors seen spreading to vagina are Pancreatic Adenocarcinoma, trophoblastic neoplasms and tumors from urinary tract in a study published in 1974 by Weitzner S and Dressner SA.¹⁴

Conclusion

1. Vaginal metastasis from colorectal cancer indicates a poor prognosis.
2. Our report highlights the importance of vaginal bleeding in patients with H/O colorectal cancer, a thorough gynaecologic assessment in such cases.

3. It helps the clinicians to be aware of treatment options for better insight and prognosis.
4. It encourages the reporting of similar cases due to the paucity of evidence in literature.

Conflict of Interest: None.

References

1. Rosai and Ackerman's surgical pathology. 9th ed. New, pg 1431 Delhi:Elsevier;2004 .
2. Chagpar A, Kanthan SC. Vaginal Metastasis of colon cancer. *Am Surg* 2001;67(2);171-2.
3. Yagci G, Cetiner S, Dede M, Gunhan O. True vaginal metastasis of rectal cancer. *Indian J Surg* 2005;67:270-2.
4. Ceccaroni M, Paglia A, Ruffo G. Symptomatic vaginal bleeding in post-menopausal woman revealing Colon Adenocarcinoma metastasizing exclusively to the vagina. *J Minim Invasive Gynecol* 2010;17(6);779-81.
5. Whitelaw GP LSPLSRP. Carcinoma of large bowel with metastasis to genitalia: Report of 2 cases. *AMA Arch Surg* 1965;73;171-8.
6. Hwei Jene Ng, E.H Aly. Vaginal metastasis from colorectal cancer. *Int J Surg* 2013;11(10):1048-55.
7. Hannah H. Wong, Peigno Chu. Immunohistochemical features of GI Tract tumors. *J Gastrointest Oncol* 2012;3(3):262-84.
8. Katsunao Nagami. Uterine cervix metastasis from rectal carcinoma: a case report and a review of the literature. *Jpn J Clin Oncol* 1999;29(12)640-2.
9. William P, Abraham M. Adenocarcinoma of the cervix. *Am J Obstet Gynecol* 1962;84;367-74.
10. Korhonen M, Stenback F. Adenocarcinoma metastatic to the uterus cervix. *Gynecol Obstet Invest* 1984;17:57-65.
11. Parikh JH, Barton DP, Ind TE, Sohaib SA. MR imaging features of vaginal malignancies. *Radiographics* 2008;28:49-63.
12. Ng HJ, Aly EH. Vaginal metastases from colorectal cancer. *Int J Surg* 2013;11:1048-55.
13. In: Fu YS, Reagan JW, editors. Pathology of the uterine cervix, vagina and vulva. Philadelphia: Saunders;1989.
14. Weitzner S, Dressner SA. Vaginal metastasis from Adenocarcinoma of pancreas. *Am Surg* 1974;40:256-8.

How to cite this article: Neetu, Triveni. Metastatic deposits of adenocarcinoma to the vault. *Indian J Pathol Oncol* 2019;6(2):315-7.