

Fibroblastic reticular cell tumour in axilla- A rare entity

Mridu Manjari¹, Manisha Sharma², Gurupriya Anand^{3*}

¹Professor and Head, ²Professor, ³Junior Resident, Dept. of Pathology, Sri Guru Ram Das Institute of Medical Sciences and Research, Amritsar, Punjab, India

***Corresponding Author: Gurupriya Anand**

Email: gurupriyaanand@hotmail.com

Received: 19th October, 2018

Accepted: 30th October, 2018

Abstract

Primary sarcomas arising in lymph node are few and far between. They are believed to arise from either follicular dendritic cells, indeterminate dendritic cells, interdigitating dendritic cells and seldom from fibroblastic reticular cells which are said to have mesenchymal origin and are involved in cytokine transport.

A 37-year-old female patient reported with painless mass in axilla without any breast lump. On histopathology a diagnosis of NHL was made which on immunohistochemistry with CK8, CK18 and SMA positivity was diagnosed as fibroblastic reticulum cell tumour. The case is being reported because of its rarity.

Keywords: Fibroblastic reticular cells, Immunohistochemistry, Lymph node, Stromal cells, Sarcoma.

Introduction

Lymph node consists of heterogenous population of stromal cells. Among these the follicular dendritic cells (FDCs) and fibroblastic reticular cells (FRCs) are mesenchymal in origin. The FRCs are concerned with the shipping of cytokines and ensheath the post capillary venules. Other members in this group are interdigitating dendritic cells (IDCs) and Langerhan's cells (and their postulated precursors the Indeterminate dendritic cells).^{1,2} The IDCs stem from hematopoietic stem cells. Lymph node sarcomas can arise from any of these cells but those arising from fibroblastic reticular cells are extremely rare.³ Only nineteen archived cases until now.

Case Report

A 37-year-old female presented with a mass in left axilla in the surgery OPD of a tertiary care center. Breast examination did not reveal any lump. On ultrasonomammography both breasts were normal. Multiple enlarged hypoechoic lymph nodes, the largest measuring 40X20mm were present in the left axillary region.

FNAC from an outside laboratory reported the presence of atypical suspicious cells. Thus excision biopsy of the same was done for histopathological evaluation.

Grossly it was nodular grey white and firm tissue piece measuring 4 X 2 cm in size and the cut surface was homogenous grey white. Histopathological examination showed cells having round to oval shape, vesicular chromatin with prominent nucleoli accompanied by scattered mature lymphocytes. Interspersed amongst these were seen elongated tumour cells arranged in fascicles and sheets. The cells had moderate content of eosinophilic cytoplasm [Fig. 1].

Histopathologically a diagnosis of Lymphoproliferative disorder- Non-Hodgkin's Lymphoma was made and Immunohistochemistry (IHC) was advised.

On IHC CD45 showed positive staining for lymphocytes with negative staining of other population of cells. Lymphomas were ruled out by negative staining for both B- cell markers (CD20 and PAX 5) and T-cell markers (CD2, CD3, CD4 and CD8) [Fig. 2].

MPO stain, CD15, CD30 negativity counted out myeloid origin of the tumor as well as Hodgkin and Anaplastic Large Cell Lymphoma [Fig. 3]. CD1a, CD34 and Desmin negativity dismissed Langerhans Cell Histiocytosis and sarcoma, Angiosarcoma and Rhabdomyosarcoma as the diagnosis. Neuroendocrinal markers CD56 and CD57 were also negative [Fig. 4].

As CD1a was negative with focal CD68 positivity possibility of interdigitating dendritic cell sarcoma (IDCS) was ruled out. CD21, the most sensitive marker for Follicular Dendritic cells, came out negative but Pancytokeratin showed very strong positivity, proving epithelial origin of neoplastic cells. CK8 and CK18 were also positive. Smooth muscle actin (SMA) showed focal positivity thus showing fibroblastic nature of the tumor [Fig. 1].

Thus fibroblastic reticular cell tumour (FRCT) was given as the final diagnosis. Therefore we conclude that the mesenchymal stem cells displaying differentiation towards both epithelioid and myoid/myofibroblastic cells give birth to cytokeratin-positive interstitial reticulum cell sarcomas (CIRCs).

Discussion

Lymph node sarcomas are very uncommon tumors that can arise either from IDCs residing in the paracortical region or from FDCs and rarely from FRCs ensheathing post capillary venules in lymph nodes. IDCs arise from hematopoietic progenitors expressing MHC II and showing strong immunoreactivity for S100. Whereas FDCs originate from mesenchymal stem cells and are present in the follicles in the lymph node. They present antigen to B lymphocytes

and are positive for CD 21, CD23 and CD35 but negative for CD45. Fibroblastic reticular cells are also mesenchymal in origin. Their main function is to maintain the integrity of lymph nodes and help in the cytokine trafficking.¹

These interstitial reticulum cells were first discovered in 1987 and subsequently labelled as being cytokeratin-positive. These aboriginal cells of lymph node are also seen in medulla, extra-follicular and inter-follicular compartment of spleen and tonsils. Ultra-structurally, they have long slender cytoplasmic processes that extend between lymphocytes.²

Immunohistochemically they are negative for dendritic cell markers and express cytokeratin 8 and 18. A small percentage of them also express Smooth muscle actin (SMA) (20-60%) and Desmin (1-10%).³

IDC sarcomas typically lose cell junctions and retain branching and interdigitating processes.^{4,5} In their study, Toyota et al found out that FDC sarcomas are made up of

spindle shaped cells with well-developed desmosomes and a paucity of cytoplasmic filaments.⁶ On the other hand, according to Tykocinski the FRC sarcomas which are keratin-positive can seemingly show both desmosomes and tonofilaments along with variable myofibroblastic features and dense bodies.⁷

On immunophenotyping almost all reported cases of FDC sarcomas show intense uniform positivity for CD21, CD23 and CD35 as noted in two separate studies by Chan et al and Perez-Ordóñez et al.^{8,9} Some studies have revealed effete expression of CD45 and B cell markers (CD19, CD20, CD22), along with EMA or CD4 in cases of FDC sarcoma.

Nodal FRC display fixed immunopositivity for vimentin with subsets positive for actin, desmin, CD68 and keratin with focal SMA positivity as shown by Doglioni et al.¹⁰ The case is being reported for its rarity.

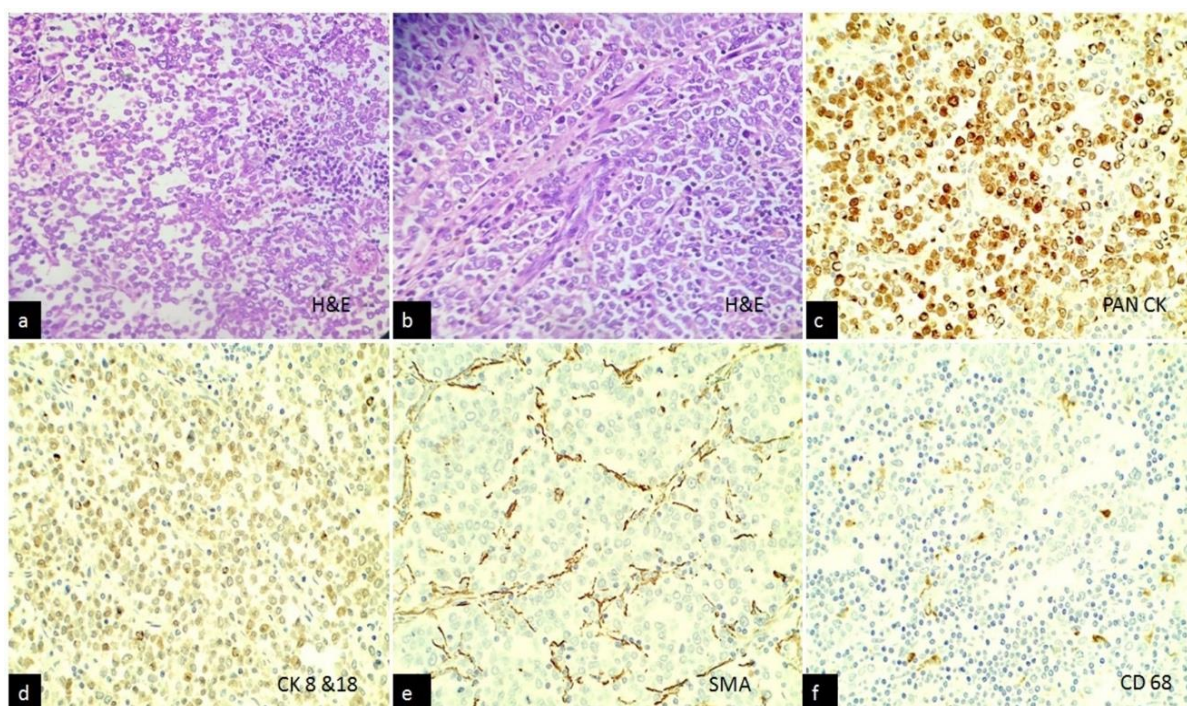


Fig. 1 a,b: H and E slides showing sheets and fascicles of round to oval and spindle cells with lymphocytes in between [100x, 400x respectively]; **c-f:** Pan cytokeratin, CK8, CK18, SMA with focal CD68 positivity confirmed diagnosis of FRCT. [IHC- 100x].

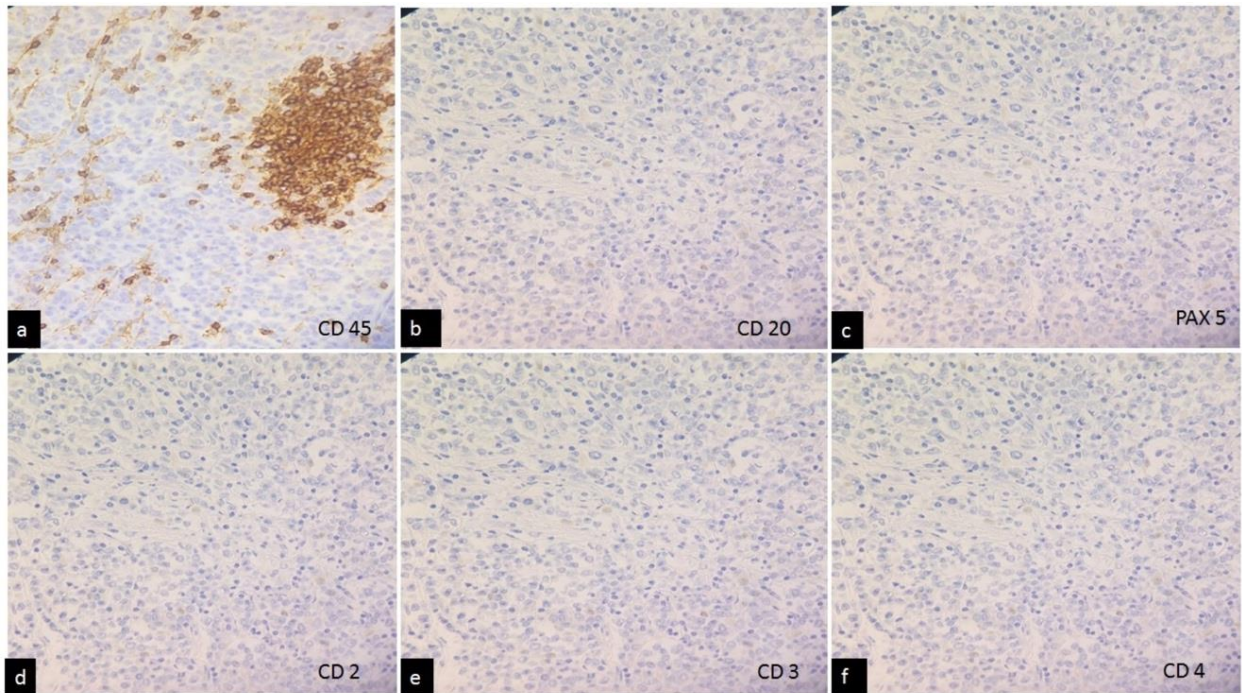


Fig. 2 a:- CD45 showing focal positivity for lymphocytes; b-f: CD20, PAX 5, CD2, CD3 and CD 4 negativity ruled out lymphomas [IHC- 100x].

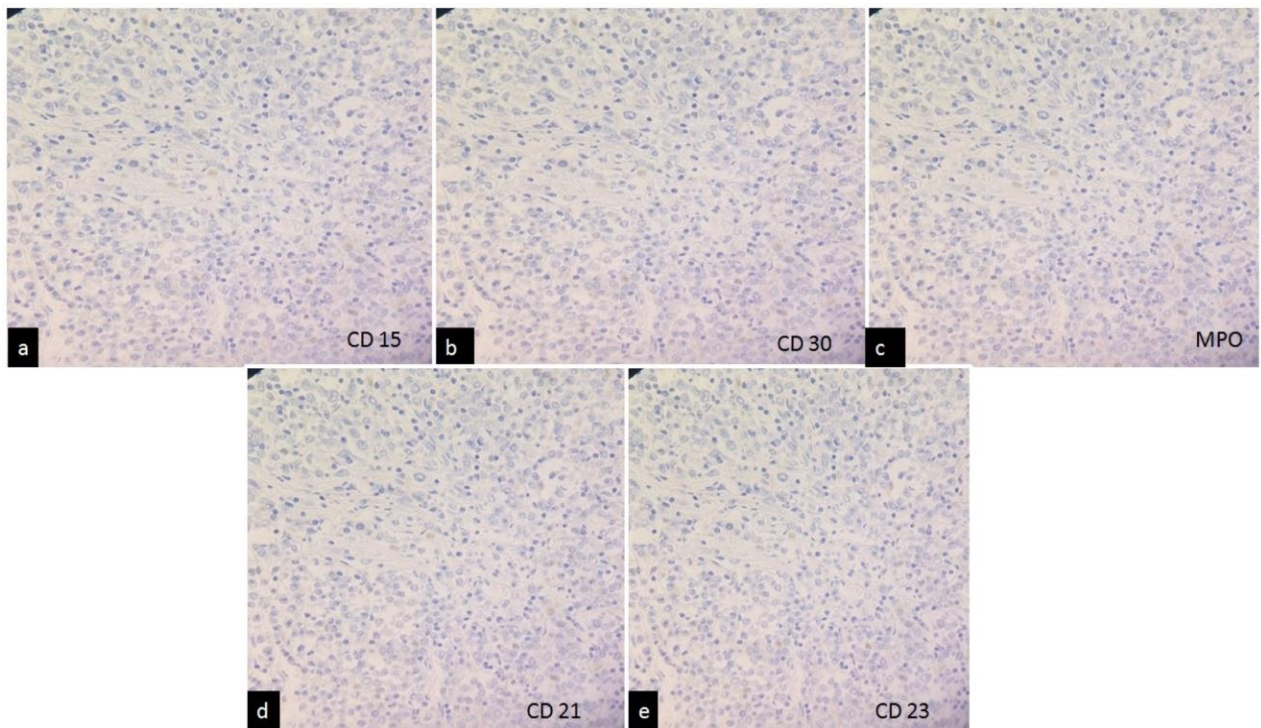


Fig. 3 a-e: CD15, CD30, MPO, CD21 and CD23 negative to rule out Hodgkin's lymphoma, Myeloid neoplasm, Anaplastic Large Cell Lymphoma and FDCL [IHC- 100x]

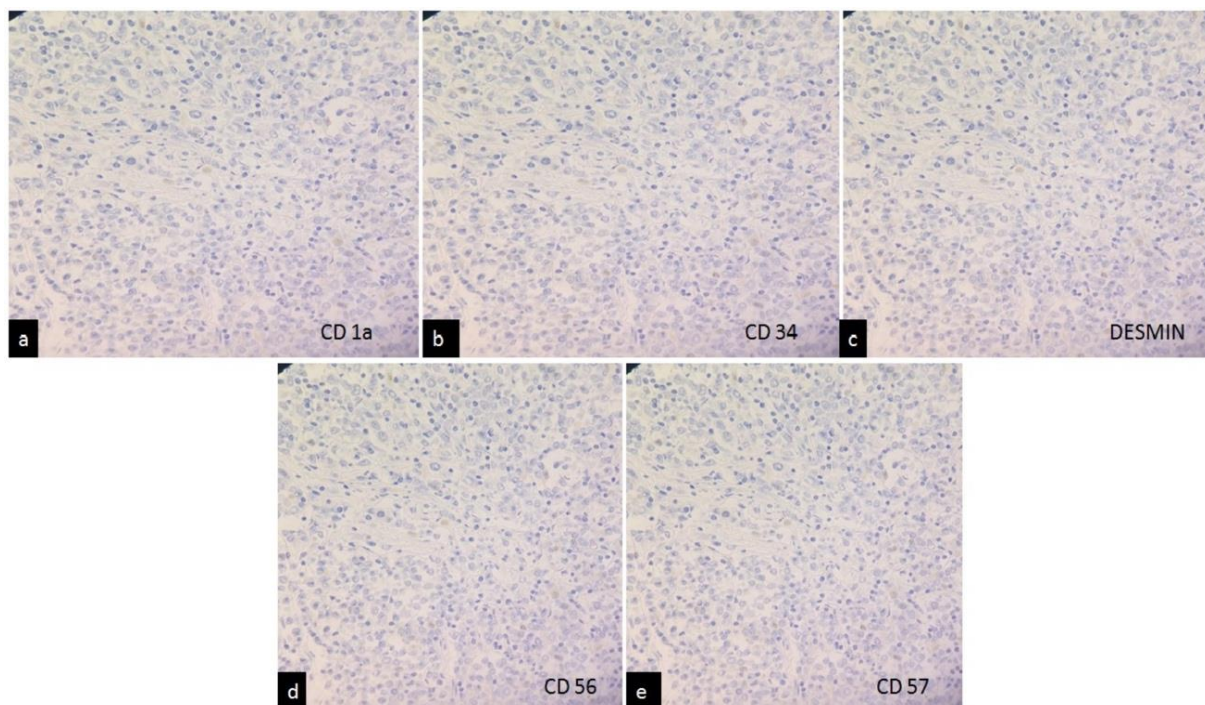


Fig. 4 a-c: CD1a, CD34, Desmin negativity ruled out Langerhans cell histiocytosis and sarcoma, angiosarcoma and rhabdomyosarcoma; d,e: CD56 and CD57 negativity ruled out Neuroendocrine tumors [IHC- 100x]

Conclusion

FRCT is an extremely uncommon neoplasm that affects the lymph nodes, spleen or soft tissues. Here, we presented a rare case of FRCS in the axilla. Although the incidence of FRCS is extremely low, our case suggests that it should be considered in the differential diagnosis of axillary masses, especially ones with no accompanying lump in the breast. Immunohistochemistry helps in confirmation of diagnosis.

Source(s) of Support: Nil.

Conflict of Interest: None.

References

- Jaffe R, Pileri SA, Facchetti F, Jones DM, Jaffe ES. Histiocytic and dendritic cell neoplasms, Introduction. In: Swerdlow SH, Campo E, Harris NL, et al, editors. WHO Classification of Tumours of Haematopoietic and Lymphoid Tissues. Lyon: IARC Press; 2008. p.354-5.
- Franke WW, Moll R. Cytoskeletal components of lymphoid organs. I. Synthesis of cytokeratins 8 and 18 and desmin in subpopulations of extrafollicular reticulum cells of human lymph nodes, tonsils, and spleen. *Differ* 1987;36:145-6.
- Lee EJ, Hyun DW, Cho HJ, Lee JG. A Rare Case of Interdigitating Dendritic Cell Sarcoma in the Nasal Cavity. *Case Rep Otolaryngol* 2013;2013:1-4.
- Rousselet MC, Francois S, Croue A, Maigre M, Saint-Andre JP, Ifrah N. A lymph node interdigitating reticulum cell sarcoma. *Arch Pathol Lab Med* 1994;118:183-8.
- Rabkin MS, Kjeldsberg CR, Hammond ME, Wittwer CT, Nathwani B. Clinical, ultrastructural immunohistochemical and DNA content analysis of lymphomas having features of interdigitating reticulum cells. *Cancer* 1988;61:1594-601.
- Toyoda K, Taniguchi J, Kikawa K. Follicular dendritic cell sarcoma: ultrastructural and immunohistochemical studies. *Intern Med* 2000;39:950-5.
- Tykocinski M, Schinella RA, Greco MA. Fibroblastic reticulum cells in human lymph nodes. An ultrastructural study. *Arch Pathol Lab Med* 1983;107:418-22.
- Chan JK, Fletcher CD, Nayler SJ, Cooper K. Follicular dendritic cell sarcoma. Clinicopathologic analysis of 17 cases suggesting a malignant potential higher than currently recognized. *Cancer* 1997;79:294-313.
- Perez-Ordóñez B, Erlandson RA, Rosai J. Follicular dendritic cell tumor: report of 13 additional cases of a distinctive entity. *Am J Surg Pathol* 1996;20:944-55.
- Dogliani C, Dell'Orto P, Zanetti G, Iuzzolino P, Coggi G, Viale G. Cytokeratin- immunoreactive cells of human lymph nodes and spleen in normal and pathological conditions. An immunocytochemical study. *Virchows Arch A Pathol Anat Histopathol* 1990;416:479-90.

How to cite this article: Manjari M, Sharma M, Anand G. Fibroblastic reticular cell tumour in axilla- A rare entity. *Indian J Pathol Oncol* 2019;6(2):318-21.