

Primary biphasic pulmonary synovial sarcoma of lung: A rare presentation in a young female

Mayanka Seth¹, Vidhish Lohiya^{2,*}, Devendra Kumar Jain³, Manish Seth⁴

^{1,2}Consultant Pathologist, ³Onco Surgeon, ⁴Radiologist, ^{1,2}Dept. of Pathology, ³Dept. of Surgical Oncology, ^{1,2,4}Medicentre Sonography and Clinical Laboratory, Udaipur, Rajasthan, ³Ananta Institute of Medical Sciences and Research Centre, Rajasthan, India

*Corresponding Author: Vidhish Lohiya

Email: vidhish87lohiya@gmail.com

Received: 8th October, 2018

Accepted: 4th February, 2019

Abstract

Pulmonary synovial sarcoma of lung is an extraordinarily rare tumor among the primary malignancies of lung. The establishment of diagnosis of primary pulmonary synovial sarcoma entails clinical, radiological and pathological investigations for confirmation and exclusion of alternative primary tumours and metastatic sarcomas of lung. Our case, a 18 year old female, showed spindle cell tumour on trucut biopsy and stained positive for B- cell lymphoma- 2 (BCL-2), Epithelial Membrane Antigen (EMA), calponin and vimentin whereas it stained negative for CD34 and cytokeratin 7. So, the diagnosis of primary pulmonary synovial sarcoma was endorsed.

Keywords: Primary pulmonary synovial sarcoma, Immunohistochemistry, Tru-cut biopsy, Rare, BCL-2, EMA.

Case Report

An 18 year old female was admitted for evaluation of chest pain and progressively increasing dyspnoea since 3 months. She had no history of hemoptysis or smoking. No peripheral lymphadenopathy was detected. Chest X ray revealed large mass on right side with pleural effusion which was further confirmed on CT scan as 16×12×8 cm pleura based oval peripheral mass invading whole of right hemithorax. The pleural fluid obtained by aspiration was reddish and cloudy. A coagulum was present. Pleural fluid analysis revealed predominantly lymphocytes (50%) followed by reactive mesothelial cells (30%) with ADA level 14.5 U/l. However, the pleural fluid cytology was found to be negative for malignant cells.

Our case is interesting due to tricky morphology of tumour cells on H&E staining. The histopathology of tissue obtained by trucut biopsy revealed sheets of malignant cells showing intertwining fascicles of densely packed spindle cells with variation in morphology mixed with hypocellular areas and these cells were separated by slit like spaces infiltrating deep into the tissue. (Fig. 1)

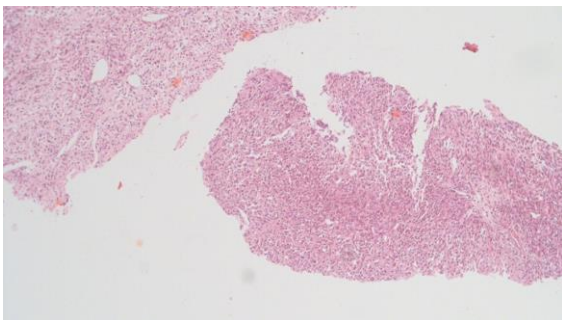


Fig. 1: Histopathologic findings. (original magnification, ×100; hematoxylin and eosin staining) biopsy showing intertwining fascicles of densely packed spindle cells

with variation in morphology mixed with hypocellular areas and these cells were separated by slit like spaces

On immunohistochemistry (IHC), the tumor cells stained positive for B- cell lymphoma 2 (BCL-2), Epithelial Membrane Antigen (EMA), calponin and vimentin whereas they were negative for CD34 and cytokeratin 7 (Ck7). Hence, final impression drawn from IHC was primary synovial sarcoma of lung. (Fig. 2-5).

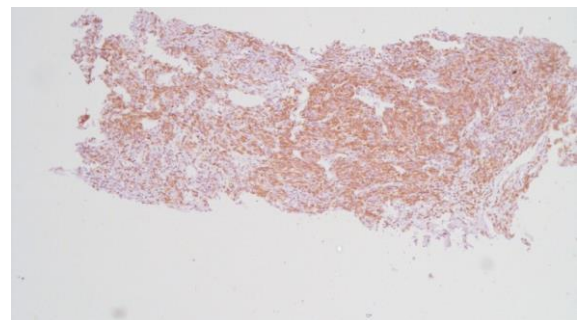


Fig. 2: Tumor cells showing positivity for bcl2

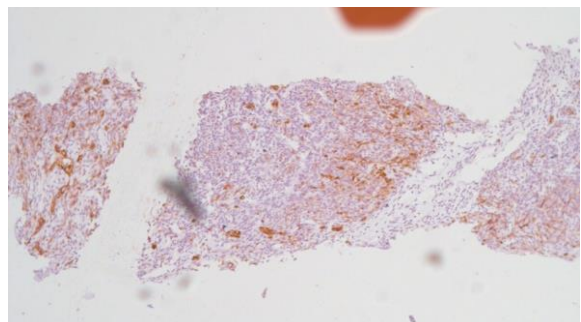


Fig. 3: Tumor cells stained positive for EMA

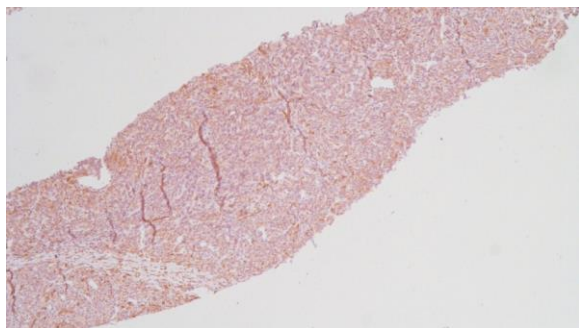


Fig. 4: Tumor cells showing positivity for calponin

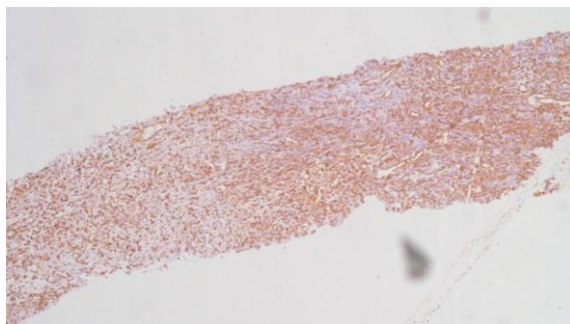


Fig. 5: Tumor cells showing positivity for vimentin

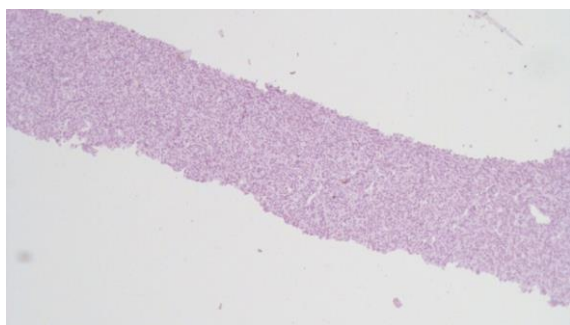


Fig. 6: Tumor cells showing negativity for cytokeratin 7

Discussion

Synovial sarcomas are rare malignant neoplasms accounting for approximately 5-14% of soft tissue sarcomas. Primary pulmonary synovial sarcoma is even rarer accounting for less than 0.5% of all primary lung tumours.¹ It occurs most commonly in adolescents and young adults.¹ Commonly arising in extremities, it can also be found in head and neck, esophagus, retroperitoneum, mediastinum, lung, pleura or pericardium. It is a highly aggressive malignant neoplasm. It is not closely related to cigarette smoking.

The term 'Synovial sarcoma' is actually a misnomer because the tumor does not originate from the synovium; it only resembles synovial tissue in light microscopy.² Normal synovial tissues do not stain for epithelial markers such as cytokeratin or epithelial membrane antigen (EMA), whereas synovial sarcoma stains for these markers with high frequency. The tumor is a mesenchymal spindle cell tumor with variable epithelial differentiation. The location of pulmonary synovial sarcomas is mostly peripheral

pulmonary parenchyma. These tumors are broadly well circumscribed but non-encapsulated solid tumors. Sporadically, the tumor may diffusely infiltrate chest wall or mediastinal structures. The patient generally presents with chest pain, cough, shortness of breath, and hemoptysis. Low-grade fever and weight loss are less frequent presentations. Like other soft tissue sarcomas, synovial sarcoma's diagnosis is also difficult to establish purely on the basis of histological appearance.

The diagnosis of primary pulmonary synovial sarcoma requires clinical, radiological, pathological, and immunohistochemical investigations to exclude alternative primary tumours and metastatic sarcoma.³ The differential diagnoses of pulmonary synovial sarcoma include sarcomatoid carcinoma, sarcomatoid variants of pleural mesothelioma, leiomyosarcoma, hemangiopericytoma, malignant peripheral nerve sheath tumor, fibrosarcoma, and spindle cell thymoma.⁴ Immunohistochemical studies often supplement histology to reach the diagnosis. Epithelial membrane antigen tends to be expressed more often and universally than cytokeratin. Vimentin, Bcl-2 and CD99 are frequently positive, while S-100 protein, desmin, smooth muscle actin and vascular tumor markers are generally negative. There are four subtypes commonly reported: monophasic fibrous, monophasic epithelial, biphasic, and poorly differentiated subtypes, monophasic subtype being most common.⁵ Histological subtypes are differentiated on the basis of immunohistochemical markers, such as vimentin, desmin, actin, CD99, and epithelial membrane antigen. Metastasis from extrapulmonary sarcomas is more common than primary pulmonary sarcomas. Our case was found to be positive for BCL-2, EMA, calponin and vimentin whereas negative for CD34 and cytokeratin 7.

In recent past, molecular testing has emerged as newer modality for differentiating carcinoma and its subtypes adding to the currently available techniques of histology and immunohistochemistry.

Recently, histology and immunohistochemistry have also been supplemented by molecular testing. Cytogenetic study by reverse transcriptase-polymerase chain reaction (RT-PCR) has proved to be beneficial in differentiating monophasic and biphasic form. Synovial sarcoma is characterized by a reciprocal chromosomal translocation (X;18) (p11; q11) which results from fusion of SYT gene on chromosome 18 to either of two genes, SSX 1 and SSX 2 on chromosome X.^{6,7} Generally, the presence of SYT-SSX 1 gene has been linked to biphasic subtype indicating a bad prognosis, whereas appearance of SYT-SSX 2 gene has been affiliated to monophasic morphology. If the diagnosis of synovial sarcoma is almost ascertained or probable on the basis of clinical, histological, and immunohistochemical evaluations, molecular testing is not regularly required, despite of its high sensitivity.

Although no standard therapy is defined, surgery along with adjunctive radiotherapy with or without adjunctive chemotherapy is usually recommended. Unfortunately, we lost our patient within 10 days of diagnosis and after extensive surgery.

Conflict of Interest: None.

References

1. Mankin HJ, Hornicek FJ. Diagnosis, classification, and management of soft tissue sarcomas. *Cancer Control* 2005;12:5–21.
2. Braham E, Aloui S, Aouadi S, Drira I, Kilani T, El Mezni F. Synovial sarcoma of the chest wall: a case report and literature review. *Ann Transl Med* 2013;1(1):9. doi:10.3978/j.issn.2305-5839.2013.01.09.
3. Roy P, Das A, Sarkar A, Dwari A, Datta S. A Primary Synovial Sarcoma of Lung. *North Am J Med Sci* 2012;4(5):241-3. doi:10.4103/1947-2714.95911.
4. Chen HH, Huang WT, Kang WY, Huang HY, Chai CY. Primary Pulmonary Synovial Sarcoma: A Case Report. *Kaohsiung J Med Sci* 2006;22:590–4.
5. Okamoto S, Hisaoka M, Daa T, Hatakeyama K, Iwamasa T, Hashimoto Ha, et al. Primary pulmonary synovial sarcoma: A clinicopathologic, immunohistochemical, and molecular study of 11 cases. *Hum Pathol* 2004;35:850–6.
6. Hosono T, Hironaka M, Kobayashi A. Primary pulmonary synovial sarcoma confirmed by molecular detection of SYT-SSX1 fusion gene transcripts: a case report and review of the literature. *Jpn J Clin Oncol.* 2005;35:274–9.
7. Kawai A, Woodruff J, Healey JH, Brennan MF, Antonescu CR, Ladanyi M. SYT-SSX gene fusion as a determinant of morphology and prognosis in synovial sarcoma. *N Engl J Med* 1998;338:153–60.

How to cite this article: Seth M, Lohiya V, Jain DK, Seth M. Primary biphasic pulmonary synovial sarcoma of lung: A rare presentation in a young female. *Indian J Pathol Oncol* 2019;6(2):322-4.