

## Ischemic optic neuropathy in internal carotid artery dissection – A rare clinical presentation

Kirti Nath Jha<sup>1</sup>, Muthu Krishnan Vallinayagam<sup>2\*</sup>, Rajalakhmi A. R<sup>3</sup>, Juhi Sahu<sup>4</sup>

<sup>1</sup>Professor, <sup>2,3</sup>Associate Professor, <sup>4</sup>Junior Resident, Dept. of Ophthalmology, Mahatma Gandhi Medical College and Research Institute, Puducherry, India

\*Corresponding Author: Muthu Krishnan Vallinayagam

Email: [muthu2308@yahoo.co.in](mailto:muthu2308@yahoo.co.in)

### Abstract

Ischaemic optic neuropathy is defined as an infarction of the retrolaminar part of optic nerve. This is caused due to hypoperfusion of optic disc leading to short posterior artery occlusion. Giant cell arteritis assumes first and foremost importance as a prominent cause of anterior ischaemic optic neuropathy. Carotid artery dissection is an uncommon aetiological factor. Carotid artery dissection presents with a constellation of ocular features like Horner's syndrome, amaurosis fugax, hemianopia, sixth cranial nerve palsy and ischaemic optic neuropathy. Ischaemic optic neuropathy has been reported in patients who suffered from dissection of carotid artery and it could be a preliminary manifestation. Suspicion of internal carotid artery (ICA) dissection should be raised in cases of anterior ischaemic optic neuropathy (AION) associated with severe unilateral cephalic pain. Dissection of carotid artery can cause cerebral and retinal ischaemia, especially in young adults, resulting in ischaemic symptoms. An array of investigations were performed to eliminate other triggers of optic neuropathy. Carotid Doppler helps to confirm the diagnosis. This article highlights a patient with a rare presentation of anterior ischaemic optic neuropathy resulting from dissection of internal carotid artery. A high index of suspicion should be entertained by symptoms like severe unilateral headache followed by diminution of vision. Prompt diagnosis and management can prevent visual loss in the fellow eye as well as life threatening complications of ICA dissection such as stroke.

**Keywords:** Anterior ischaemic optic neuropathy, Dissection of internal carotid artery.

### Introduction

Ischaemic optic neuropathy is described as infarction of the optic nerve.<sup>1</sup> It is characterized by sudden loss of vision with associated swelling of the optic disc initially. In subsequent stages it evolves to optic atrophy.<sup>1</sup> It results from hindrance of blood supply of the posterior ciliary artery producing a retrolaminar infarct.<sup>1</sup> Giant cell arteritis assumes first and foremost importance as a cause of anterior ischaemic optic neuropathy.<sup>1</sup> One of the infrequent cause of optic neuropathy is dissection of internal carotid artery (ICA).<sup>2</sup> A case of spontaneous dissection of internal carotid artery heading to anterior ischemic optic neuropathy (AION) is discussed here.

### Case Report

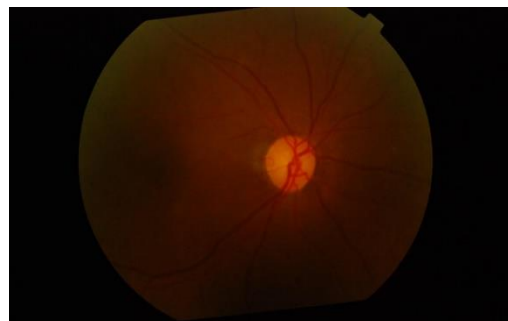
A 55 year old male presented with sudden painless loss of vision in his right eye one month back. The patient had severe right sided headache three days before the onset of diminution of vision.

The patient did not give any history of transient attacks of visual blackouts in the past or any history of trauma. He denied experiencing similar episodes in the past. He did not complain of focal neurological deficits, jaw claudication or painful extra ocular movements. The visual acuity in the right eye was only perception of light with inaccurate projection of rays. Marcus Gunn pupil was observed. Color vision and visual field could not be assessed due to very poor visual acuity. The superficial temporal artery was normal and pulsatile. There were no systemic features of multiple sclerosis. Disc pallor with well-defined margins and arteriolar attenuation was detected in the right eye. [Fig. 1]

On ophthalmoscopic examination left eye fundus was observed to be normal. [Fig. 2]

Systemic examination was unremarkable. Other investigations like blood sugars, C-reactive protein, Rapid plasma reagin test and erythrocyte sedimentation rate (ESR), were within normal limits. Serology for syphilis and retrovirus were normal. ECG revealed normal sinus rhythm and echocardiography was normal. There was no intracranial mass lesion detected on Computed Tomography and magnetic resonance of the brain and orbit failed to disclose any abnormalities. There were no demyelinating lesions or optic nerve enhancement suggestive of optic neuritis. Carotid Doppler revealed a flap like structure in proximal internal carotid artery, disclosing a dissection of the right internal carotid. [Fig. 3-4]

A diagnosis of anterior ischemic optic neuropathy (AION), secondary to internal carotid artery dissection on the right side was deliberated. Neurologist consultation was pursued and prophylactic antiplatelet medication was advised.



**Fig. 1: Right eye fundus showing optic disc pallor**

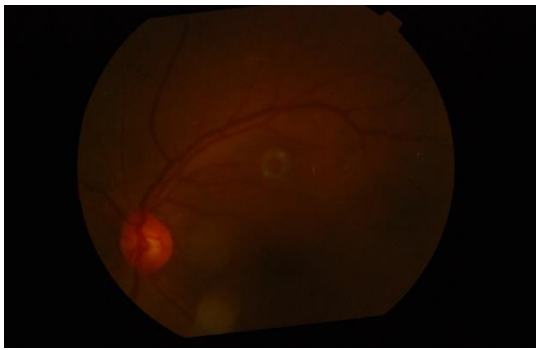

Fig. 2: Left eye fundus showing normal optic disc

**Discussion**

Dissection of internal carotid artery is a common source leading to embolic stroke.<sup>3</sup> Carotid artery dissection could be either traumatic or spontaneous.<sup>3</sup> Dissection of carotid artery is associated with systemic hypertension, Marfan’s syndrome, Ehlers Danlos, fibromuscular dysplasia, cystic

medial necrosis, atheroma and pheochromocytoma.<sup>3</sup> ICA dissection presents with a constellation of ocular features like Horner’s syndrome, amaurosis fugax, hemianopia, sixth cranial nerve palsy and ischaemic optic neuropathy.<sup>3</sup> Ischaemic optic neuropathy has been previously reported in patients with carotid artery stenosis or dissection and it could be an initial manifestation.<sup>1,2,4,5</sup>

The postulated mechanism of ischaemic optic neuropathy in ICAD is reduction of ocular blood flow caused by reduction in calibre of true lumen of ICA.<sup>1</sup> The mean age for occurrence of ICA dissection ranges from 35 to 51 years. Severe unilateral orbital pain is a pre-eminent symptom of ICA dissection and usually precedes AION by 3-5 days.<sup>1</sup> This patient gave a similar history of unilateral right sided headache three days before the onset of loss of vision. Ipsilateral cephalic pain is often the prodromal symptom of ICA dissection and occurs in about 95% patients.<sup>1</sup> AION associated with severe unilateral cephalic pain should raise suspicion of ICA dissection.<sup>1</sup> However, giant cell arteritis should be ruled out as an utmost priority.

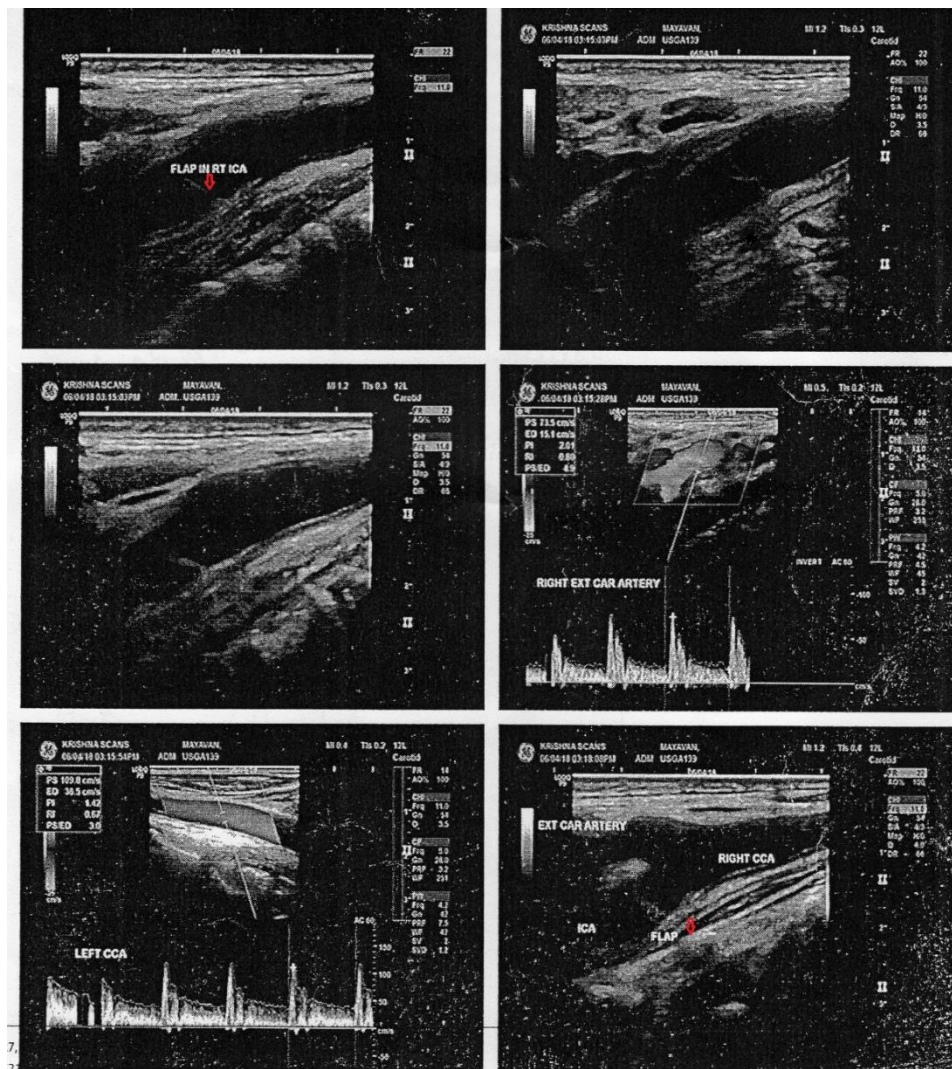
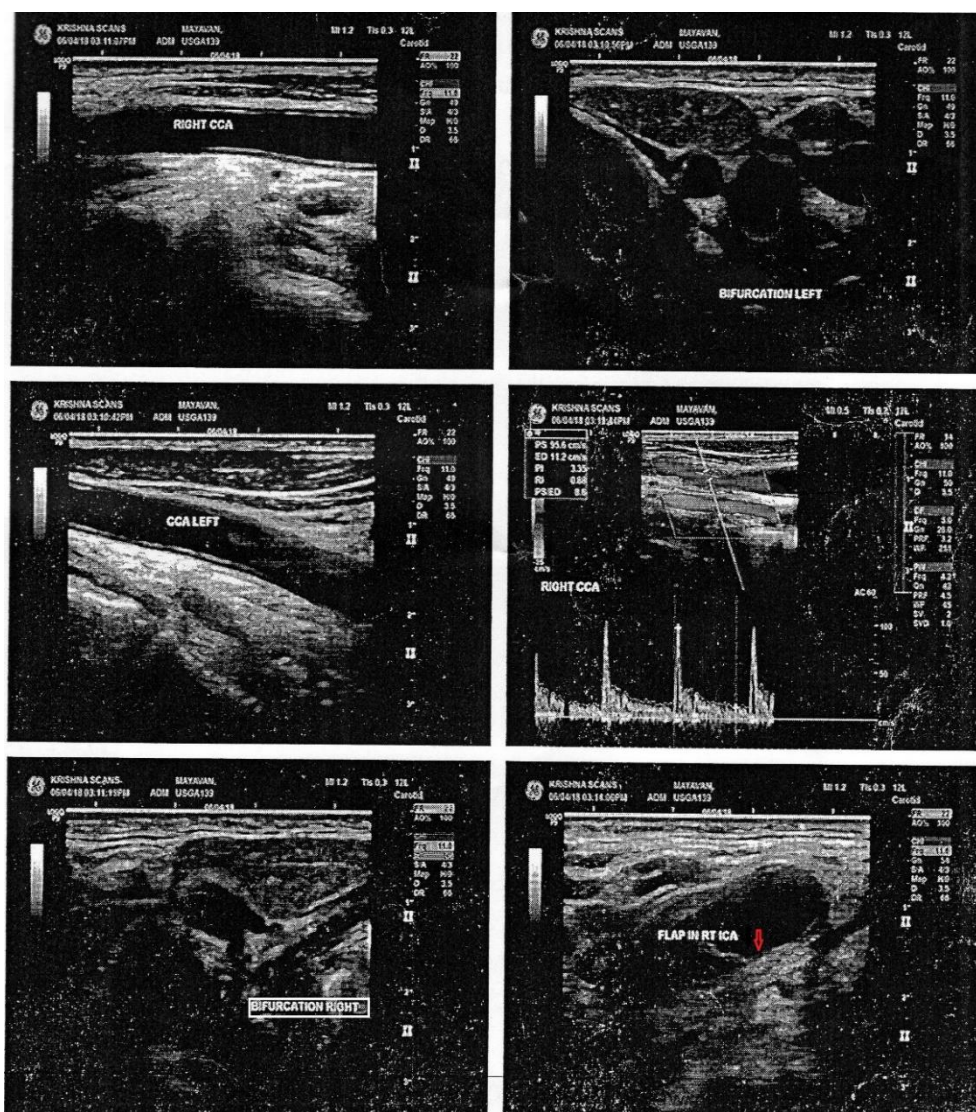


Fig. 3: Carotid artery doppler showing flap of ICA dissection



**Fig. 4: Carotid artery Doppler showing flap of ICA dissection**

Our patient presented with sudden loss of vision and RAPD. This is caused due to optic nerve head hypoperfusion resulting from occlusion of short posterior ciliary arteries. Ischaemia of the ciliary ganglion and iris leads to clinical manifestations suggesting prolonged ocular hypoperfusion.<sup>1,3</sup> The fundus picture of our patient was suggestive of ischaemic optic atrophy. In ischaemic optic neuropathies (both anterior and posterior), optic disc manifests pallor in about one month following loss of vision.<sup>1</sup> All other investigations to exclude causes of optic atrophy were normal. CRP, ESR, RPR, VDRL and MRI brain and orbit were normal. Carotid artery Doppler showed features suggestive of right internal carotid artery dissection. In the absence of any other contributory cause, we conclude that ICA dissection is the cause of ischaemic optic neuropathy in this case. It remains a diagnosis of exclusion.

ICA dissection as a cause of anterior ischaemic optic neuropathy has not been recognised frequently. Early recognition of ocular symptoms is crucial in spontaneous ICA dissection since delayed diagnosis can multiply the risk

of secondary cerebral or retinal ischaemia.<sup>6</sup> Early diagnosis could prevent a similar catastrophe in the fellow eye.

Internal carotid artery dissection could present with isolated ischemic optic neuropathy. It is imperative that the diagnosis is entertained early in the course of the disease, so as to prevent disastrous consequences. Further research is called for studying the varied ocular manifestations of internal carotid artery dissection for early diagnosis and hence prevent life threatening complications.

### Conclusion

Delayed diagnosis of internal carotid artery dissection can increase the risk of stroke and retinal ischaemia. In the majority of the cases, ophthalmologists are the first contact to the patient. Prompt diagnosis and management can prevent visual loss in the fellow eye and life threatening complications of ICA dissection such as stroke. A high index of suspicion should be entertained by symptoms like severe unilateral headache followed by diminution of vision. Carotid Doppler clinches the diagnosis.

**Conflict of Interest:** None.

## References

1. Biousse V, Schaison M, Touboul P-J, D'Anglejan-Chatillon J, Bousser M-G. Ischemic Optic Neuropathy Associated With Internal Carotid Artery Dissection. *Arch Neurol* 1998;55(5):715–9.
2. Waybright EA, Selhorst JB, Combs J. Anterior ischemic optic neuropathy with internal carotid artery occlusion. *Am J Ophthalmol* 1982;93(1):42–7.
3. Kerty E. The ophthalmology of internal carotid artery dissection. *Acta Ophthalmol Scand* 1999;77(4):418–21.
4. Brown GC. Anterior ischemic optic neuropathy occurring in association with carotid artery obstruction. *J Clin Neuroophthalmol* 1986;6(1):39–42.
5. Sawle GV, Sarkies NJC. Posterior ischaemic optic neuropathy due to internal carotid artery occlusion. *Neuro-Ophthalmol* 1987;7(6):349–53.
6. Barros A, Soares R, Almeida I, Fontão L, Chibante-Pedro J. Horner Syndrome Secondary to Bilateral Spontaneous Internal Carotid Artery Dissection – First Manifestation of Fibromuscular Dysplasia. 2018;4.

**How to cite this article:** Jha KN, Vallinayagam MK, Rajalakhmi AR, Sahu J. Ischemic optic neuropathy in internal carotid artery dissection– A rare clinical presentation. *Indian J Clin Exp Ophthalmol* 2019;5(2):262-5.