

Tumor budding in invasive carcinoma of breast of No Special Type (NST): Value as a prognostic factor

Inuganti Venkata Renuka^{1*}, K. Madhavi², P. Premalatha³, PAV Krishnamacharyulu⁴, R.Vaishnavi⁵

^{1,4}Professor, ^{2,5}Post Graduate, ³Professor and HOD, ¹⁻⁵Dept. of Pathology, NRI Medical College Chinakakani, Andhra Pradesh, India

*Corresponding Author: Inuganti Venkata Renuka

Email: repriya56@gmail.com

Abstract

Context: Tumor budding refers to single or small cluster of tumor cells detached from the main tumor mass in histological sections. In colon cancer high tumor budding is associated with worse prognosis, correlates with metastatic lymph nodes and is included in the protocol for reporting colectomy specimens. We studied tumor budding in mastectomy specimens of cases of breast carcinoma of no special type (NST) to evaluate its utility as a prognostic factor by correlating tumor budding, both intratumoral and peripheral tumoral, with other known prognostic markers of breast cancer like lymph nodal metastasis, tumor size, lymphovascular emboli and grading.

Aims: To evaluate tumor budding in invasive ductal carcinoma (IDC) NST with: 1.lymph node metastasis; 2.lymphovascular invasion (LVI); 3.Grading by Nottingham modification of Bloom-Richardson (NBR) and other prognostic parameters like age, tumor size, and ER status.

Methods and Material: The present study is a prospective study of all Modified Radical Mastectomy (MRM) specimens received and examined from 1st January 2018 to 30th July 2018. Along with tumor budding various prognostic parameters were evaluated. Immunohistochemical marker Pancytokeratin was utilized for counting the tumor buds, wherever necessary.

Statistical Analysis: Chi Square test was utilized to study significant differences between variables. A p value < 0.05 was considered statistically significant.

Results: A greater number of tumor buds both intratumoral (ITB) and peritumoral (PTB) were associated with lymph node metastasis and lymphatic invasion whereas ITB also correlated with NBR grading.

Conclusion: In our study we detected the association of high tumor budding, both ITB and PTB in invasive ductal carcinoma (NST) and also noted association with known poor prognostic markers. Hence our results highlight the importance of tumor budding as a prognostic factor and submit that this histological feature could be included in diagnostic protocols just as in carcinoma of the colon.

Keywords: Breast cancer, No special type, Tumor budding, Prognosis, Lymphatic invasion.

Introduction

Invasive breast cancer is the most common carcinoma in women accounting for 23% of all cancers in women globally.² Metastatic potential is the most important factor in cases of patients being treated for breast carcinoma. Many prognostic factors, clinicopathological and molecular factors, have been evaluated and utilized in the clinical assessment of breast cancer. New markers are still in research for breast carcinoma one of them being tumor budding.³

Tumor budding refers to single or small cluster of tumor cells detached from the main tumor mass.¹ A bud is defined as a single tumor cell or a cluster of upto 5 tumor cells.¹ In our study, of Modified Radical Mastectomy specimens, the total number of intratumoral (ITB) and peripheral tumor buds (PTB) in ten high-power fields (HPF) were counted.

In Normal ducts and ductal carcinoma in situ the ductal epithelium is separated from the surrounding stroma and vascular structures by a basement membrane and a row of myoepithelial cells.⁴ Absence of these myoepithelial cells is of importance in diagnosis of invasive ductal carcinoma of the breast. Over the last few years, numerous studies have shown the importance of tumor budding as an independent predictor of lymph node positivity, local and distant relapse, lymphatic invasion, and poor prognosis among patients with Colorectal Cancer of all pathological stages.⁶ Whether tumor budding can be considered a relevant factor in the prognosis of breast carcinomas is to be determined. The purpose of

this study is to evaluate the potential value of tumor budding in breast cancer of no special type (NST) as a predictor of prognosis, by correlating with lymph nodal metastasis and also to correlate tumor budding with other known breast carcinoma prognostic markers.

Materials and Methods

The present study is a prospective study of all Modified Radical Mastectomy (MRM) specimens (n=50) examined from 1st January 2018 to 30th July 2018. Various parameters were evaluated along with tumor budding like age, tumor size, lymphovascular invasion, lymph node metastasis, NBR grading and ER status. Immunohistochemical marker pancytokeratin antibody (AE1/AE3) staining was done in some cases.

Scoring of Tumor Buds

Tumor budding was counted as per the procedure proposed by the ITBCC 2016 for reporting tumor budding in colorectal cancer in daily diagnostic practice.⁷

Peripheral tumor budding was assessed in one hotspot (in a field measuring) at the invasive front and budding category was based on absolute bud count per 0.785mm.²

We used the 2 tier system with

High tumor budding equated to absolute bud scores >4 tumor buds across 0.785 mm²

Low tumor budding equated to absolute bud scores ≤4 tumor buds across 0.785 mm²

Chi Square test was utilized to study significant differences between variables. A p value < 0.05 was considered statistically significant.

Results

A total of 50 MRM specimens were evaluated for all the prognostic parameters.

Association of ITB in Mastectomy Specimens

High ITB scoring results showed a significant association with lymphovascular invasion (p= 0.002), lymph nodal metastasis (p= 0.000) and tumor grade (p = 0.048). The scoring results with significant associations are depicted in Table 1.

Association of PTB in Mastectomy Specimens

High PTB scoring results showed a significant association with lymphovascular invasion (p= 0.000) and lymph nodal metastasis (p= 0.000). The scoring results with significant associations are summarized in Table 2. No other significant associations were found with other pathological parameters like age, tumor size, ER & grade in PTB.

Discussion

Tumor budding is best described as a histologic pattern associated with poor prognosis in early-stage colorectal adenocarcinoma and a predictor of nodal metastasis in T1 colorectal adenocarcinoma.⁸ Recently, some of these associations were also found in esophageal carcinoma and pancreatic cancer.^{9,10} Hence, we investigated the significance of tumor budding and its relationship to clinicopathological features of breast carcinoma such as age, lymphovascular invasion, tumor grade, tumor size, lymph nodal metastasis and ER status. There are very few studies in literature relating to budding in breast cancer.¹¹ In this

prospective study, we used a histologic scoring system to study 50 surgically resected, primary invasive breast carcinomas (NST) for the extent of both ITB and PTB. Invasive ductal breast carcinoma NST was selected because it is the most common histological subtype we encountered.

We compared our statistics (p value) with other studies which are depicted in Table 3.

We confirmed a significant association of tumor budding with lymphovascular invasion (ITB- p=0.002, PTB-p=0.000) and Lymph node metastasis (ITB- p=0.000, PTB- p=0.000) and correlated with our results with other studies by Salhia et al³ (n=148), Liang et al¹² (n=160), Niputu Sriwidyani et al² (n=70), Zahra MA et al¹³ (n=160), and F.JA Gujan et al (n=474).^{14,15} Salhia et al³ studied PTB with lymph node positivity and LVI parameters and their p values were significant, and the ITB correlated well with grade and ER status. In our study ITB values correlated only with grade and not ER status. All the other studies were done only on PTB. Liang et al¹² showed a significant association of PTB with LVI, positive lymph nodes and tumor size whereas in our study tumor size was not significant either in ITB or PTB. In studies by Zahra MA et al¹³ and Niputu Sriwidyani et al² PTB was significant with LVI, lymph node positivity, grade and size. FJA Gujan et al¹⁴ demonstrated significant association between PTB and LVI, lymph node positivity like in our study but also with ER status.

Long term follow up was not possible with our patients since the study was done prospectively. However the association of high tumor budding with positive lymph nodes and lymphovascular invasion suggests that it can be considered as a poor prognostic factor.

In our study we considered LVI and metastatic lymph nodes as prognostic factors and did not do a survival study.

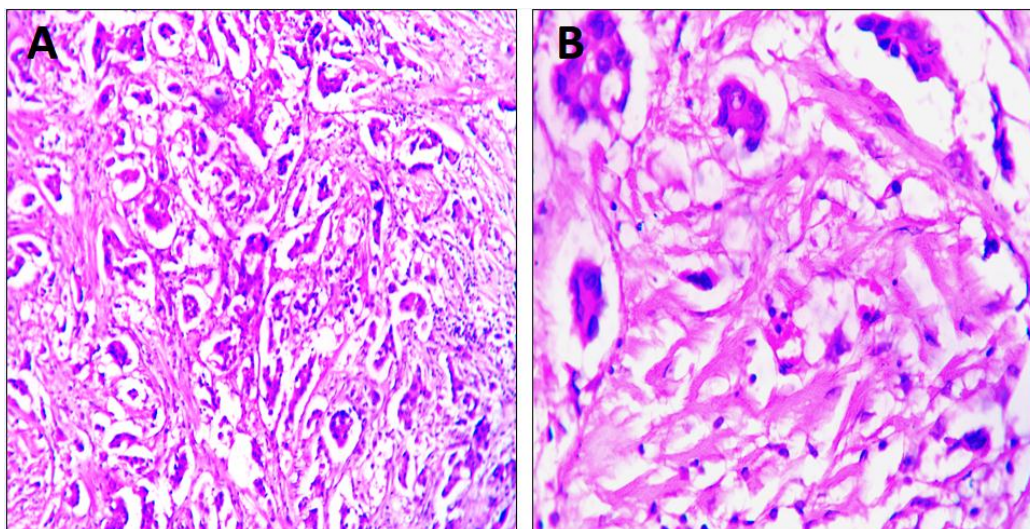


Fig. 1: A. High intratumoral Budding (H&E,x100); B. High intratumoral Budding (H&E,x400)

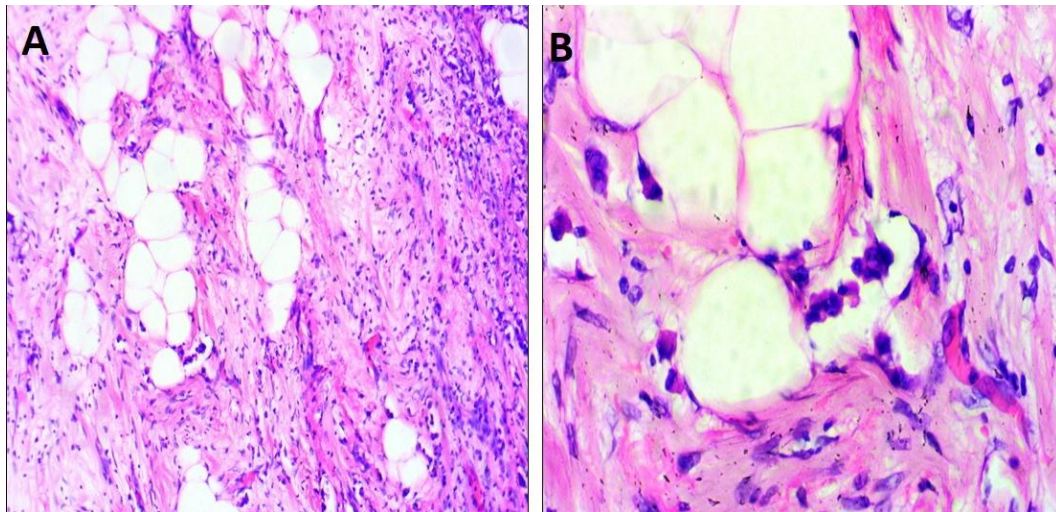


Fig. 2: A. High peripheral tumoral budding (H&E,x100); B. High peripheral tumoral budding (H&E,x400)

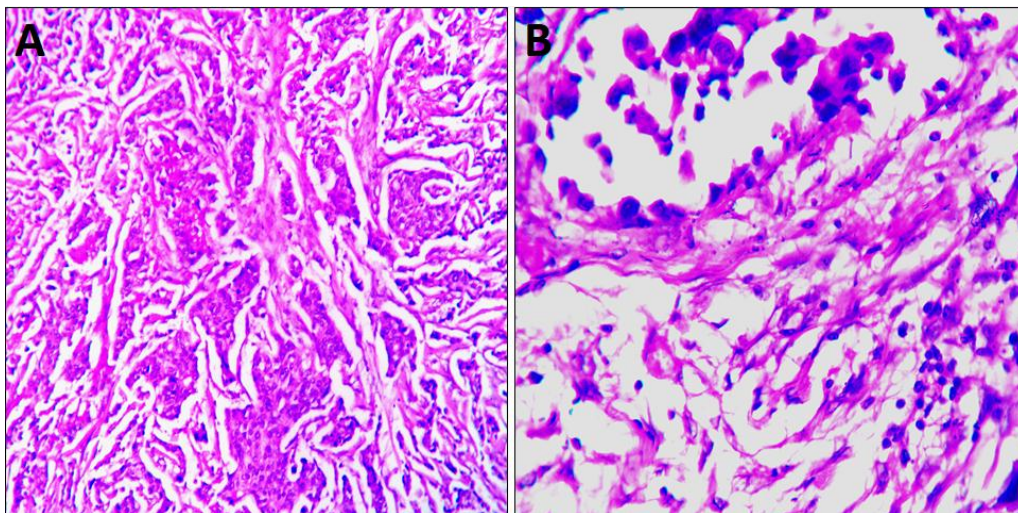


Fig. 3: A. Low intratumoral budding (H&E,x100); B. Low peripheral tumoral budding (H&E,x100)

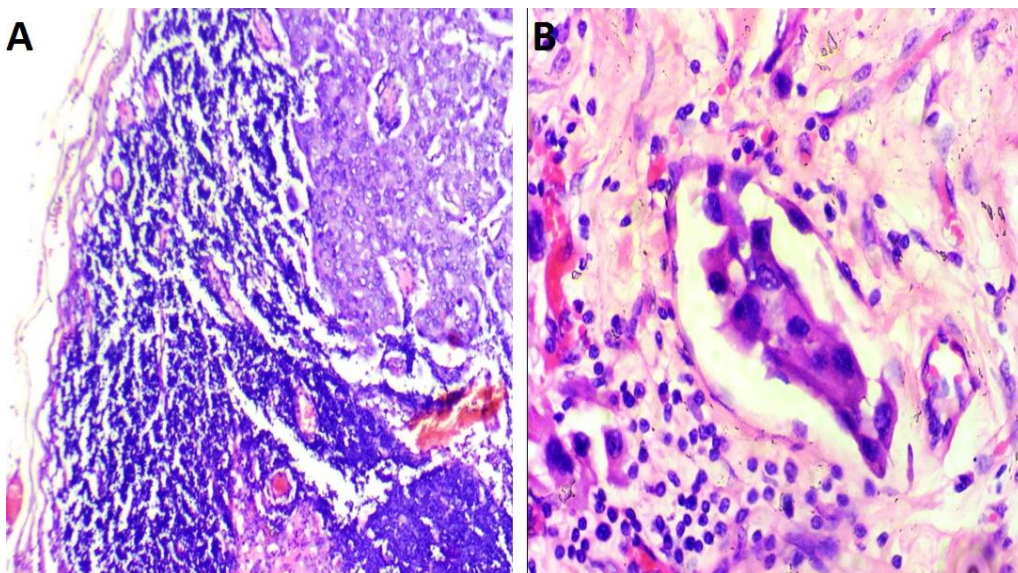


Fig. 4: A. Lymph node metastases in a case of high ITB (H&E,x100); B. Lymphovascular invasion in a case of high ITB (H&E,x400)

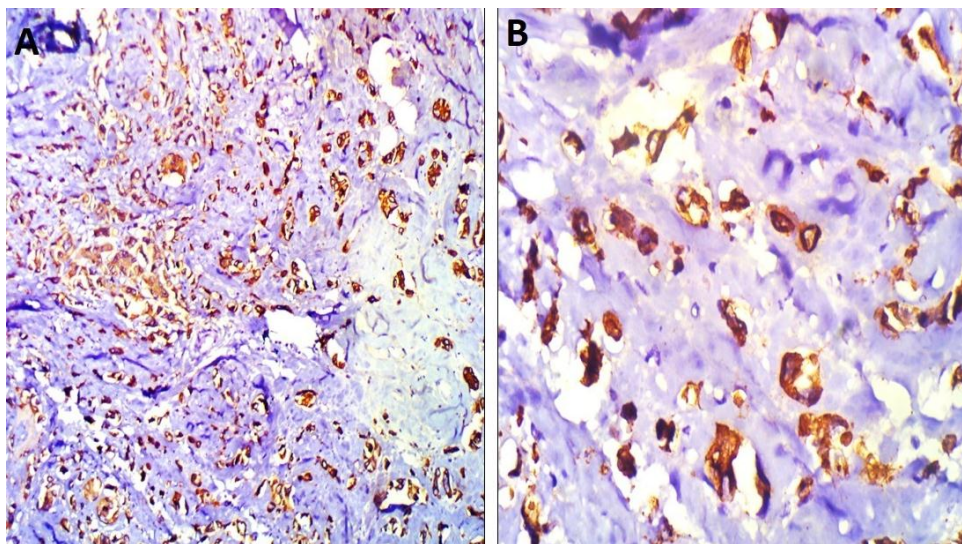


Fig. 5: A tumor buds using IHC marker (IHC Pan-cytokeratin, x100); B. Tumor buds using IHC marker (IHC Cytokeratin, x400)

Conclusion

In our study we noted a significant association of tumor budding, both ITB and PTB in invasive ductal carcinoma (NST) and tumor budding also correlated with known poor prognostic indicators such as lymphovascular invasion and metastatic deposits in lymph nodes. ITB also correlated with NBR grading. Our results show that both high ITB & PTB are associated with regional lymph node metastasis and lymphovascular invasion. Hence high tumor budding can be considered as an indicator of poor prognosis in cases of breast carcinoma along with metastatic deposits in lymph nodes and lymphovascular invasion. This feature may help in therapy and decision making and could be included in the tumor reporting protocol of breast carcinomas just as in carcinoma of the colon.

Institutional Ethics Committee approval was taken for this study.

Acknowledgements: None.

Funding: None.

Conflicts of interest: None.

Ethical Clearance: None.

References

- Salhia B, Trippel M, Pfaltz K, Cihoric N, Grogg A, La "drach C et al. High tumour budding stratify breast cancer with metastatic properties. *Breast Cancer Res Treat* 2015;150: 363-71.
- Sriwidyani N, Manuaba I, Alit-Artha I, Mantik-Astawa I. Tumor budding in breast carcinoma: relation to E-Cadherin, MMP-9 expression, and metastasis risk. *Bali Med J* 2016;5(3):497-501.
- G. Colditz, K.S. Chia. Invasive breast carcinoma: Introduction and general features. In: Sunil R. Lakhani, Ian O. Ellis, Stuart j. Schnitt, PuayHoon Tan, Marc J. van de Vijver, editors. WHO Classification of Tumors of the Breast, 4th ed. Lyon, France: IARC; 2012.p.14.
- Polyak K, Hu M. Do myoepithelial cells hold the key for breast tumor progression? *J Mammary Gland Biol Neoplasia* 2005;10(3):231-47.
- Wessels LF, Van Welsem T, Hart AA, Van't Veer LJ, Reinders MJ, Nederlof PM et al. Molecular classification of breast carcinomas by comparative genomic hybridization: a specific somatic genetic profile for BRCA1 tumors. *Cancer Res* 2002;62:7110-17.
- Lugli A, Karamitopoulou E, Zlobec I. Tumour budding: a promising parameter in colorectal cancer. *Br J Cancer* 2012;106:1713-17.
- Lugli A. Recommendations for reporting tumor budding in colorectal cancer based on the International Tumor Budding Consensus Conference (ITBCC) 2016. *Modern Pathol* 2017;30(9):1299-1311.
- Guzinska-Ustymowicz K. The role of tumour budding at the front of invasion and recurrence of rectal carcinoma. *Anticancer Res* 2005;25(2B):1269-72.
- Niwa Y, Yamada S, Koike M, Kanda M, Fujii T, Nakayama G et al. Epithelial to mesenchymal transition correlates with tumor budding and predicts prognosis in esophageal squamous cell carcinoma. *J Surg Oncol* 2014;110(6):764-69.
- Karamitopoulou E, Zlobec I, Born D, Kondi-Pafiti A, Lykoudis P, Mellou A et al. Tumour budding is a strong and independent prognostic factor in pancreatic cancer. *Eur J Cancer* 2013;49(5):1032-39.
- Ellis O, Collins L, Ichihara S, Mac Grogan G. Invasive carcinoma of no special type In: Lakhani SR, Ellis IO, Schnitt SJ, Tan PH, van de Vijver MJ (eds) WHO classification of tumours of the breast, 4th ed. IARC Press, Lyon; 2012.p.34.
- Liang F, Cao W, Wang Y, Li L, Zhang G, Wang Z. The prognostic value of tumor budding in invasive breast cancer. *Pathol Res Pract* 2013;209(5):269-75.
- Zahra MA, Donald CM, Joanne E, Elizabeth M, Julie CD, Clare O et al. The relationship between lymphovascular invasion and angiogenesis, hormone receptors, cell proliferation and survival in patients with primary operable invasive ductal breast cancer. *BMC Clin Pathol* 2013;13:31
- Gujam FJA, Going JJ, Mohammed ZM, Orange C, Edwards J, McMillan DC. Immunohistochemical detection improves the

- prognostic value of lymphatic and blood vessel invasion in primary ductal breast cancer. *BMC Cancer* 2014b;14:676.
15. Gujam FJA, Edwards J, Mohammed ZMA, Going JJ, McMillan DC. The relationship between the tumourstroma percentage, clinicopathological characteristics and outcome in patients with operable ductal breast cancer. *Br J Cancer* 2014a;111:157-65.

How to cite this article: Renuka IV, Madhavi K, Premalatha P, Krishnamacharyulu PAV, Vaishnavi R. Tumor budding in invasive carcinoma of breast of No Special Type (NST): Value as a prognostic factor. *J Diagn Pathol Oncol* 2019;4(2):125-129.