

Evaluation of efficacy of commercially available decalcifying agents

Raihan Hariz¹, Maji Jose², Soniya Adyanthaya^{3*}

¹General Dental Practitioner, ²Professor and HOD, ³Reader, ^{2,3}Dept. of Oral Pathology and Microbiology, Yenepoya Dental College Nithyananda Nagar, Derlakette, Mangalore, Karnataka, India

*Corresponding Author: Soniya Adyanthaya

Email: drsoniya1978@gmail.com

Abstract

Aims and Objective: Decalcification of hard tissues specimens for the purpose of histopathological examination is often a time-consuming process and lead to undue delay in diagnosis. As a part of search for an ideal decalcifying agent, we designed the present study to compare two commercial decalcifying agents with 5% nitric acid

Materials and Methods: Size matched bone specimens from human mandible were decalcified, using 5% Nitric acid, commercial decalcifying agents: Product A and Product B (n=22 each). Decalcified specimens were processed, sectioned, stained with H&E stain and evaluated for different parameters such as microtomy, staining quality, structural integrity, preservation of cellularity and cellular and nuclear details. The results were compared between the groups using Kruskal Wallis test and Mann-Whitney U test.

Results: 5% Nitric acid is found to be significantly better in terms of microtomy, staining characteristics and structural integrity with p-value being 0.002, 0.005 and 0.004 respectively when compared to Product A. Similarly microtomy, staining characteristics and preservation of cellularity were noted to be superior with 5% Nitric acid in comparison with Product B, with p-value of 0.004, 0.001 and 0.019 respectively. None of the assessed parameters showed significant difference between Product A and Product B groups.

Conclusion: We found 5% nitric acid to be a better decalcifying agent compared to the commercial decalcifying agents used in this study. When time is a constrain, Product A i.e Osteomoll is a good choice, as the process of decalcification is faster without compromising the quality to a great extent.

Keywords: Decalcification, 5% Nitric acid, Commercial decalcifying agents.

Introduction

Preparation of bone specimens for microscopic examination is an integral part of every histopathology laboratory, for the diagnosis of bone pathologies and evaluation of the extent of bone involvement in other disease process. Bone decalcification is a time consuming process, and often cause delay in diagnosis. The quality of decalcified sections depends greatly on velocity of the demineralization process and therefore it requires weeks for preparation of sections with adequate preservation of the tissue structure. Although, strong acids accelerate the process of decalcification, they adversely affect tissue stability and stainability. On the contrary, with weak acids or chelating agents such as EDTA, preservation of tissue architecture is good. However, the process is very slow resulting in delay in completion of decalcification. Therefore, histopathologists are always in the search of a choice of decalcification to strike the balance between speed of decalcification and maintenance of tissue morphology and quality of staining.

There are a number of studies available in the literature where the researchers carried out studies comparing efficacy of different decalcifying agents.⁵⁻⁹ Many researchers have also tried changing physical conditions to accelerate decalcification process such as altering the temperature, use of agitation, sonification and use of microwave. Studies have proved that that the speed of decalcification with most of the agents increases when used with microwave, without compromising the quality of sections.¹⁰⁻¹⁷

Most of the histopathology labs use strong acids like Nitric acid routinely as a decalcifying agent. Handling of these strong acid for preparation of appropriate concentration can be troublesome for inexperienced people

and increases the possibility of chemical accidents. Our search to identify an efficient ready to use decalcifying agents, probably one that can minimize handling of dangerous acids and therefore improving the lab safety, led us to commercial preparations. A number of commercial decalcifying agents have been marketed, claiming rapidity of process with less interference with subsequent staining and minimum tissue distortion and structure loss. From different commercially available decalcifying agents, in the present study two agents from reputed companies were chosen and compared with 5% Nitric acid.

Materials and Methods

Bone sections of 1x1cm in size, from human mandible samples submitted to Department of Oral & Maxillofacial Pathology, as part of mandibulectomy specimens for histopathological examination and diagnosis were used for the study. Only samples with intact cortical plates were included and those with thinning of the cortical plate or perforations were excluded.

After adequate fixation, the specimens were assigned identification numbers A, B and C and were placed in three different decalcifying agents namely 5% Nitric acid, Product A and Product B respectively. For decalcification process, the manufacturer's instructions (protocol) were followed. The reagents were periodically replaced and specimens were checked for decalcification using physical methods. Once the specimen was sufficiently soft, decalcification end point was tested by using radiographic and also using chemical method. The number of days required for complete decalcification was noted and this was recorded as speed of decalcification. Decalcified sections

were subjected to routine tissue processing, sectioned and stained with haematoxylin and eosin and examined under binocular light microscope (XSZ-N107T NO-002363).

In order to compare the efficacy of decalcifying agents, the tissue specimens decalcified in three different agents were analyzed for different parameters such as speed of decalcification process, gross nature of specimen and ease of microtomy, staining quality and microscopic characteristics. During microtomy, ease of sectioning, ribbon formation and sectioning artefacts were assessed and graded from 1–4 [Score 1-Poor, Score 2-Fair/ Satisfactory, Score 3-Good, and Score 4-Excellent]. The staining of tissues was evaluated as poor, fair/satisfactory, good or excellent with scores 1,2,3 or 4 respectively. Poor was score 1 which indicated that the tissue failed to take up the stain adequately and stained unevenly. ‘Satisfactory’ pointed toward relatively better but not visualized up to the mark (Score 2). ‘Good’/ score 3 designated good contrast between the nucleus and cytoplasm and visibility of details and excellent indicate that brilliant staining with very good contrast (Score 4).

Structural integrity was assessed by examining the architecture of the tissue. Fragmented disrupted tissue sections were scored as poor (Score 1), Sections with few disruption but able to appreciate the structural details were given as Fair/satisfactory (Score 2) and ones with minimum or no disruptions were scored as good (Score 3) and excellent (Score 4) respectively.

Preservation of cellular components was examined for presence of osteoblastic lining and osteocyte within the lacunae and graded from Score 1 to Score 4 according to the extent of preservation of these cellular components. The sections with disrupted osteoblastic lining and most of the lacunae being empty were scored 1, while the sections with most of the lacunae showing intact osteocytes and osteoblasts lining the bone margins were scored 4. The sections exhibiting intermediate findings i.e slightly better than score 1 got the score 2 while ones more closer to score 4 got score 3.

Preservation of cellular and nuclear details was evaluated similar to that of cellular components. Each section was examined for preservation cellular details of osteoblasts and osteocytes and graded from Score 1 to Score 4 according to the extent of preservation of these cellular details. The sections with no distinct cellular and nuclear morphology and indistinct outlines were scored 1, while the sections with most of the cells showing distinct cellular and nuclear morphology of osteocytes and osteoblasts were scored 4. The sections exhibiting intermediate findings i.e slightly better than those scored 1 were assigned score 2 while ones with findings more closer to score 4 got score 3.

As most of the evaluative criteria were subjective, the scoring and assessment was carried out by two different observers, who were detailed about the scoring criteria prior to the evaluation process. Observers were blinded from the details of the decalcification process each section has gone through and each observer was asked to do the scoring twice at two different time intervals. The mean scoring was

considered to prevent inter-observer bias and intra-observer bias.

The obtained data was subjected to statistical analysis using the one way ANOVA test for determining the speed of decalcification. For the purpose of comparing efficacy of three agents, different parameters such as microtomy, staining quality, structural integrity, preservation of cellularity, and cellular and nuclear details were compared between the groups. The results were statistically analyzed using Kruskal Wallis test and Mann-Whitney U test.

Results

Days taken to complete the decalcification process with respect to 5% Nitric acid, Product A and Product B were 25.73 ± 0.93 , 5.77 ± 1.20 , 19.45 ± 1.26 days respectively. In the present study, there was significant difference observed when the ease of sectioning and quality of sections of the bone tissue decalcified in three different ways was compared. In 5% Nitric acid, 45.5% of specimens scored 3 and remaining 31.8% scored 4 and 22.7% scored 2. In Product A and Product B, 59.1% and 50.0% of specimens scored 2 whereas 40.9% and 45.5% of specimens scored 3 respectively. (Fig. 1)

When comparing the staining quality of tissue, 54.5% of specimens from 5% Nitric acid group exhibited good staining quality with score 3, while 40.9% sections scored 4 and only one section scored 2. In Product A and Product B, majority of specimens scored 3 while 27.3% and 22.7% of specimens scored 2 respectively.

When the structural integrity was evaluated, 18(81.89%) of sections from 5% Nitric acid and 14(63.6%) sections of Product B retained good structural integrity with score 3 while remaining 13.6% of 5% Nitric acid and 36.4% of Product B respectively scored 2. It is significant to note that although small percentage (4.5%), one section of 5% Nitric acid group retained excellent structural integrity. In Product A, 54.5% and 45.5% of the sections exhibited score 2 and 3 respectively.

While assessing preservation of cellular components, the sections from 5% Nitric acid scored 31.8%, 54.5% and 13.6% satisfactory, good and excellent respectively. In Product A, equal distribution of sections in satisfactory and good score was noted. In contrast, 63.9% sections from Product B demonstrated score 2 and remaining 36.4% showed score 3. (Table 1)

When preservation of cellular and nuclear details were evaluated, 50% of the specimens decalcified in 5% Nitric acid showed score 2 whereas 36.4% and 13.6% of the sections scored 3 and 4 respectively. Similarly 63.6% of Product A and 59.1% of Product B scored 2 and 36.4% and 40.9% exhibited score 3 respectively.

When the results obtained were subjected to Kruskal Wallis test, to compare between 3 groups, microtomy, staining quality and structural integrity showed statistically significant difference between the groups with p-value 0.002, 0.001 and 0.012 respectively. However, no significant difference in cellularity & cellular nuclear details were noted between the groups. Mann-Whitney U test was

used to compare between the 2 groups. When the multiple group comparison or post hoc test was done between 5% Nitric acid and Product A group, microtomy, staining quality & structural integrity showed significant difference between the groups with p-value 0.002,0.005 and 0.004 respectively. Cellularity and cellular & nuclear details were not significantly different in 5% Nitric acid & Product A. When 5% Nitric acid and product B groups were compared, microtomy, staining quality and structural integrity of 5% Nitric acid group was found to be significantly superior to Product B group with p-value 0.002,0.005 and 0.004

respectively. Preservation of cellularity and cellular & nuclear details were not significantly different between these two groups. When the Product A and Product B groups were compared, there was no significant difference noted in any of the parameters tested with p values for microtomy, staining quality and structural integrity, preservation of cellularity and cellular & nuclear details being 0.903, 0.860, 0.231, 0.367 and 0.760 respectively (Table 2).

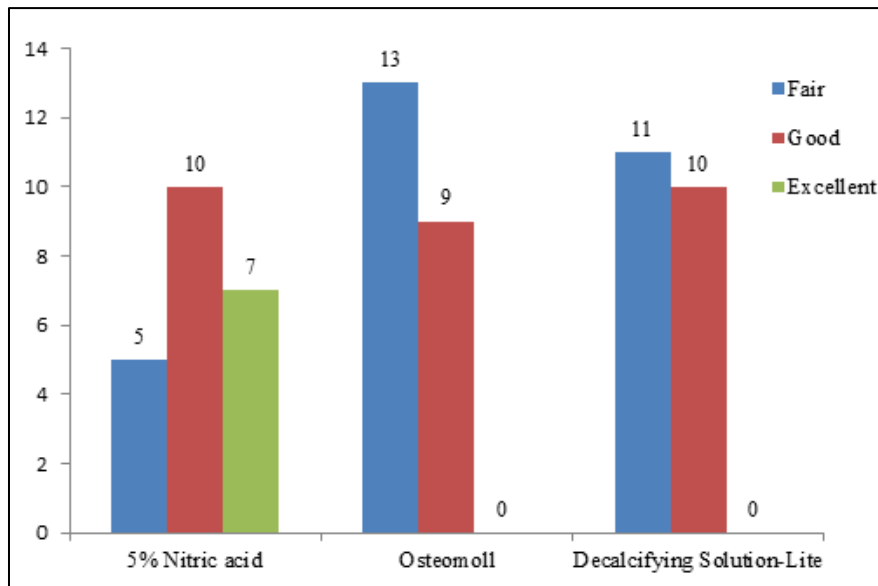


Fig. 1: Showing effect of different decalcifying agents on microtomy

Table 1: Preservation of cellular components with different decalcifying agents

Group	Fair	Good	Excellent
5% Nitric acid	(7)31.8%	(12)54.5%	(3)13.6%
Product A	(11)50.0%	(11)50.0%	(0)0.0%
Product B	(14)63.6%	(8)36.4%	(0)0.0%

Table 2: Comparison of various parameters in different groups

	G1 (Nitric acid)		G2 (Product A)		G3 (decal)		P. Value
	Median	IQR (Q1-Q3)	Median	IQR (Q1-Q3)	Median	IQR (Q1-Q3)	
Sectioning	3	2.75-4	2	2-3	2	2-3	.002*
Staining	3	3-4	3	2-3	3	2.75-3	.001*
Structure	3	3-3	2	2-3	3	2-3	.012*
Cellularity	2	2-3	2.50	2-3	2	2-3	.050
Cellular & Nuclear details	2.50	2-3	2	2-3	2	2-3	.434

Discussion

As a part of the study, efficacy of two selected commercially available decalcifying agents were compared with with 5% Nitric acid, which is the routinely used in most of the histopathology laboratories. As per the manufacturers product information sheet, Product A contains hydrochloric acid (>= 10% - < 20%) and formaldehyde (>= 1% - < 5%). The second product (Product

B) is an aqueous solution of hydrochloric acid and proprietary compounds, the details of which is not revealed.

It was noted that the commercial Product A decalcified the specimens significantly faster than the other two agents with time taken for completion of process is only 4 to 7 days. On the contrary other commercial agent Product B and 5% nitric acid took on an average 25.73 day and 19.45 days

respectively. Our results with respect to 5% Nitric acid is comparable to that of *Jimson et al.* who reported the end point of decalcification for 5% nitric acid was 25 days.⁹ There were no studies available on other products to make a comparison, however we could not achieve decalcification within the time period claimed by the manufacturers. From the observation it was inferred that, for rapid decalcification, Product A can be used as the decalcifying agent.

When the ease of sectioning and quality of sections of the bone tissue decalcified in three different ways was compared, both Product B and Product A group showed nearly similar findings with majority scored only satisfactory and the rest good. On the contrary, majority of specimens decalcified in 5% nitric acid scored good and 31% of specimens from 5% Nitric acid group scored excellent, while none of the specimens from the other groups scored excellent (Fig. 1). Comparison of these three agents showed that 5% Nitric acid is significantly superior in terms of microtomy compared to Product A and Product B with p values 0.002 and 0.004 respectively.

With regards to staining quality of tissue, 40.9% sections from 5% nitric acid group showed excellent staining while 54.5% exhibited good staining quality with good contrast between the nucleus and cytoplasm and visibility of details. In contrast, most of the sections from other two groups staining quality graded as satisfactory or good. The comparison between groups showed a significantly superior staining quality with 5% Nitric acid compared to Product A and Product B with p values being 0.005 and 0.001 respectively while no significant difference between commercial agents. Thus it can be interpreted that the interference with staining was least with 5% Nitric acid than other agents used in which the major component was hydrochloric acid. Our results are consistent with those of *Srinivasyiah et al.*, and *Rehan et al.*, who reported 5% Nitric acid to be better with respect to time taken and staining characteristics.^{16,23} We also agree with *Rolls et al.*, who reported that strong acids such as hydrochloric at concentrations up to 10% are the most rapid in action but may cause a loss of nuclear staining and can macerate tissues.⁸ Problems with staining quality is one point highlighted by many researchers who carried out studies on acid decalcifiers and they have attributed this to different factors. Some have described eosinophilia in decalcified tissue to the low pH of the tissue following acid treatment that enhances the staining by acidic dyes.⁴ Haematoxylin staining is generally poorer after acid-decalcification as nucleic acids are particularly intolerant to acid decalcification resulting in poor nuclear-cytoplasmic contrast and poor visualisation of chromatin.^{2,4}

When the structural integrity was graded, 18(81.89%) of sections from 5% Nitric acid group and 14(63.6%) sections of Product B group retained good structural integrity with minimal disruptions, while remaining 13.6% of these groups respectively satisfactory i.e. few disruptions but able to appreciate the structural details. Although the sections of Product A group scored satisfactory to good in terms of structural integrity, more than 50% scored only

satisfactory. The statistical comparison revealed that 5% nitric acid to be better in terms of preserving structural integrity with p value 0.004 compared to Product A. But no significant difference was noted with Decalcifying Solution-Lite. This observation can be interpreted, correlating with the speed. It has been reported earlier that as the speed of decalcification increases the chances of disruption of the tissue also increases. It is interesting to note that 5% nitric acid, though a strong acid was comparatively gentle to the specimens than the commercial products tested in this study. During decalcification a steady process apatite dissolution in aqueous acidic media happens in the following simultaneous processes or steps: (1) diffusion of chemical reagents (H⁺ and anions of acid An⁻) from bulk solution to the solid/liquid interface; (2) adsorption of the chemicals onto the surface of apatite; (3) chemical transformations on the surface; (4) desorption of products (ions of fluoride, calcium and orthophosphate) from the crystal surface; and (5) their diffusion into the bulk solution.²⁴ The organic components such as collagen fibrils and other extra fibrillar material in the bone are the nucleating sites of mineral deposition during the process of mineralization and therefore both these components are strongly integrated with each other. Therefore any processes that attempt to dissociate the mineral compound adversely affect integrity of even the organic components. The extent of disruption depends on swiftness of the process. This explains the relation between speed of decalcification process and disturbance in structural integrity of decalcified tissue¹. Thus, during decalcification process the solubilisation and extraction of organic substances especially proteoglycans accompanies the inorganic substance. The loss of organic substances can drastically change the structure and histochemistry of decalcified tissue.²⁵

While assessing the preservation of cellular components from 5% Nitric acid group, majority of sections showed good preservation of cellular components. In both Product A and Product B groups sections showed satisfactory to good preservation of cells with majority of sections from group three showed only satisfactory score (63.9%) and remaining 36.4% scored good. (Table 2). Our observations support the opinion of *Prasad et al.*, and *Fernandes et al.*, who noted that acids adversely affect the preservation of cellular and nuclear details and cause morphological alterations such as oedema, shrinkage, vacuolation, disruption and fraying not attributable to the pathologic condition.⁴

In a study conducted by *Sudha Jimson et al.*, to evaluate the efficacy of different decalcifying agent used to decalcify bone and concluded that the bone treated with 5% nitric acid decalcified quickly.⁹⁻¹⁰ Despite the slow speed of decalcification, with respect to the quality of sections 5% Nitric acid was superior to other two commercial agents. Our findings support the observations of *Jimson et al.*⁹, and *Gupta et al.*²⁸ who suggested 5% Nitric acid to be suitable decalcifying agent for routine histopathological diagnosis, provided sufficient time is available. The speed of decalcification was excellent in case of Product A, but this was achieved at the expense of quality of sections, structural

integrity and cellular preservation. In situations when time available is a real constrain, Product A is a better choice because decalcification can be done in relatively short period of time; though quality of sections are reduced, adequate for histologic assessment. Decalcification process was relatively slower in case of Product B. In spite of the slow speed of decalcification process, the preservation of structural integrity, staining quality, preservation of cellular components and cellular details were not significantly different compared to Product A.

One of the major limitations of our study was that, sections only of cortical plates were used. The results obtained may not be the directly relatable to the effect of these decalcifying agents on cancellous bone with variable amounts of soft tissue in the marrow space. Further studies are recommended on effect of these agents specimen containing both types of bone tissues under different physical conditions.

Conclusion

In this study, we found 5% nitric acid to be a better decalcifying agent compared to the commercial decalcifying agents used in this study. When time is the major constrain, the Product A i.e. Osteomoll can be a good choice, as the process of decalcification is quite faster without compromising the quality to a great extent.

References

1. Stevens A, Lowe J, Bancroft JD. Theory and practice of histological techniques. 4th ed. New York: Churchill Livingstone; 1996.
2. Culling CF, Allison RT, Barr WT. Cellular Pathology Technique 4th ed. London: Butterworth pub; 1985.
3. Kang QK, LaBreck JC, Gruber HE, An YH. Histological techniques for decalcified bone and cartilage. In Handbook of histology methods for bone and cartilage. 2003;209-19.
4. Prasad P, Donoghue M. A comparative study of various decalcification techniques. *Indian J Dent Res* 2013;24(3):302-08.
5. Mathai AM, Naik R, Pai MR, Rai S, Baliga P. Microwave histoprocessing versus conventional histoprocessing. *Indian J Pathol Microbiol* 2008;51(1):12-16.
6. Feldman AT, Wolfe D. Tissue processing and hematoxylin and eosin staining. *Histopathology. Methods Protoc* 2014;31-43.
7. Boivin G, Anthoine-Terrier C, Obrant KJ. Transmission electron microscopy of bone tissue: a review. *Acta Orthop Scand* 1990;61(2):170-80.
8. Rolls GO. Difficult Blocks and Reprocessing. Wetzlar: Leica Microsystems. 2011.
9. Jimson S, Balachander N, Masthan KM, Elumalai R. A comparative study in bone decalcification using different decalcifying agents. *Int J Sci and Res* 2014;3(8):1226-9.
10. Sangeetha R, Uma K, Chandavarkar V. Comparison of routine decalcification methods with microwave decalcification of bone and teeth. *J Oral Maxillofac Pathol* 2013;17(3):386-91.
11. Cho A, Suzuki S, Hatakeyama J, Haruyama N, Kulkarni AB. A method for rapid demineralization of teeth and bones. *Open Dent J* 2010;10(4):223-9.
12. Hatta H, Tsuneyama K, Nomoto K, Hayashi S, Miwa, S, Nakajima T et al. A simple and rapid decalcification procedure of skeletal tissues for pathology using an ultrasonic cleaner with D-mannitol and formic acid. *Acta Histochemical* 2014;116(5):753-7.
13. Kapila SN, Natarajan S, Boaz K, Pandya JA, Yinti SR. Driving the Mineral out Faster: Simple Modifications of the Decalcification Technique. *J Clin Diagn Res JCDR* 2015;9(9):ZC93-ZC97.
14. Waerhaug J. Decalcification of bone and teeth under vacuum-a rapid method for producing hard tissue preparations. *J Dent Res* 1949;28(5):525-6.
15. Gruntz SL, English V, Sterling VA. Expedited bone throughput using microwave decalcification. *Technical Bull Histology* 2011;44(1).
16. Srinivasyaiah A, Nitin P, Hegde U. Comparison of microwave versus conventional decalcification of teeth using three different decalcifying solutions. *J Lab Physicians* 2016;8(2):106-11.
17. Pitol DL, Caetano FH, Lunardi LO. Microwave-induced fast decalcification of rat bone for electron microscopic analysis: an ultrastructural and cytochemical study. *Braz Dent J* 2007;18(2):153-7.
18. Boon ME, Wals-Paap CH, Visinoni FA, Kok LP. The two-step vacuum-microwave method for histoprocessing. *Eur J Morphology* 1995;33(4):349-58.
19. Mayers CP. Histological fixation by microwave heating. *J Clin Pathol* 1970;23(3):273.
20. Bezahler GH. Microwave fixation of biopsy specimens. *Am J Dermatopathology* 1989;11(3):295.
21. Suri V, Chaturvedi S, Pant I, Dua R, Dua S. Application of domestic microwave for urgent histopathology reporting: an evaluation. *Indian J Pathol Microbiol* 2006;49(3):348-51.
22. Kumar H, Kalkal P, Buch A, Chandanwale SS, Bamanikar S, Jain A. Role of microwaves in rapid processing of tissue for histopathology. *Med J* 2014;7(4):458-62.
23. Chaudhari K, Chattopadhyay A, Dutta SK. Microwave technique in histopathology and its comparison with the conventional technique. *Indian J Pathol Microbiol* 2000;43(4):387-94.
24. Bonucci E, Reurink J. The fine structure of decalcified cartilage and bone: a comparison between decalcification procedures performed before and after embedding. *Calcified Tissue Int* 1978;25(1):179-90.
25. Ojha S, Haritwal A, Patel R, Meenai F, Chaurasia R, Gupta S et al. Rapid decalcification technique using tissue floatation bath (TFB) in a tertiary care oncology centre. *Indian J Pathol Oncol* 2016;3(2):226-30.
26. Gupta S, Agnihotri A, Chandra A, Gupta OP. Contemporary practice in forensic odontology. *J Oral Maxillofac Pathol* 2014;18(2):244-80.

How to cite this article: Hariz R, Jose M, Adyanthaya S. Evaluation of efficacy of commercially available decalcifying agents. *Arch Cytol Histopathol Res* 2019;4(2):168-72.