

Observational study of morphometric parameters of the medial meniscus of the knee joint in 30 adult cadavers

Amandeep Kaur¹, Preeti Chaudhary², Gurdeep Singh Kalyan³, Gurwinder Singh Bal^{4*}

¹Assistant Professor, ²Professor and HOD, ³Professor, ⁴Junior Resident, ¹⁻³Dept. of Anatomy, ⁴Dept. of Orthopaedics, ^{1,2}Guru Gobind Singh Medical College, Faridkot, Punjab, ³Government Medical College, Patiala, Punjab, ⁴Maharishi Markandeshwar Institute of Medical Sciences and Research, Mullana, Ambala, Haryana, India

*Corresponding Author: Gurwinder Singh Bal

Email: drgurwin@live.com

Received: 26th November, 2018

Accepted: 30th January, 2019

Abstract

Introduction: The objective of the study was to observe the morphometric variations in the anatomy of human left and right medial menisci. The relevant data for medial meniscus anatomical variation is rather unexplored thus emphasizing the importance of the study.

Materials and Methods: Dissection of 30 adult knees was performed. The menisci were compared for weight, inner and outer circumference along with width of the menisci.

Conclusion: Although the menisci may show subtle anatomic variations in their morphology within the same species, the left and right side medial meniscus in the same individual are morphologically equivalent.

Keywords: Morphology, Medial meniscus, Knee anatomy, Cadaveric study.

Introduction

The medial meniscus is C shaped, has an anterior and a posterior horn. The anterior horn is narrower than the posterior while the Lateral meniscus as a whole is smaller in radius than the medial. The anterior insertion is attached anterior to the intercondylar eminence at the tibia, is fan shape and to the anterior cruciate ligament. Posteriorly, it is attached over the intercondylar area between the lateral meniscus's posterior insertion and anterior to the posterior cruciate ligament. The peripheral border is inserted to the medial capsule and through the coronary ligament to the upper border of tibia in its entirety.¹

According to Calliet,² medial meniscus width on an average is about 10mm. Hayashi et al,³ described that the normal meniscus shows thickness and width of 6-8mm and 12-13mm respectively.⁴

In a study conducted by Almieda et al,⁵ 22 adult male corpses were studied and their medial meniscus morphometric variations analyzed. The study revealed that the medium third of the meniscus had the least thickness followed by posterior and anterior. The average width being 5.71 mm.

Changes in the knee joint after meniscectomy include ridge formation, narrowing of joint space and flattening of the femoral condyle.⁶

Medial meniscectomy decreases contact area decreases contact area by 50% to 70% and increases contact stress by 100%.⁷

The menisci act as a joint filler, compensating for gross incongruity between femoral and tibial articulating surfaces.⁸

The menisci are important component parts of the load-bearing articular surfaces of the knee.⁹

The blood supply of the menisci was discovered to be by the medial, lateral and middle genicular arteries. The peripheral 10-25% of the menisci are supplied by a peri-

meniscal capillary plexus¹⁰ which takes its origin from the capsular and synovial tissues.

When a load is transmitted across the knee joint, the circumferentially oriented collagen fibres within the menisci generate a hoop stress, which resists extrusion of the menisci from between the femoral condyle and tibial plateau.¹¹

It was also reported that the width of the medial meniscus anterior 9.02 ± 1.59 mm, middle third was 12.16 ± 2.58 and posterior third was 17.37 ± 2.22 mm respectively.

Another study conducted on 40 menisci from 20 knees (Braz and Silva)¹² concluded that the anterior third to be the narrowest followed by middle and the posterior third being the widest part of the meniscus.

The thickness when measured at 3 points revealed the posterior 3rd to be least (5.18mm), the middle third at 6.31mm and the anterior at 6.17mm with the final average at 5.88mm.

Materials and Methods

Adult male cadavers were dissected to procure Medial menisci from both sides of each cadaver. The Menisci showing any altered gross appearance, were dried and not in fresh state were excluded. 60 medial menisci (from 30 cadavers) were procured in this manner. Following were the parameters taken into account:

1. Weight
2. Inner circumference
3. Outer circumference
4. Width

Weight

Using a well calibrated electronic balance, weight was taken in grams and mean of 3 readings was calculated as final value.

For the measurements of the other parameters three points were marked, them being:

- a. Anterior apical point
- b. Posterior apical point of outer circumference.
- c. Posterior apical point of inner circumference¹³⁻¹⁵

Inner Circumference

The concave length of the inner circumference was measured using non-stretchable silk thread. The landmarks taken were from the anterior to the posterior apical point on the inner circumference. They were divided into 4 equal parts by 3 points A, B, C.

Outer Circumference

Similarly, the convex length from anterior to posterior apical point on the outer circumference was recorded and was separated into 3 points A', B', C'^{16,17} Fig. 1¹⁸

Points were moved from inner to outer circumference. The width of the meniscus at these points was measured i.e. A-A', B-B', C-C'.

Average width was derived and recorded. To determine the thickness of the meniscus the same width points were used and then thread was placed in the outer circumference between the top and bottom edge. All data was organized, recorded tabulated and analysed.¹⁹

Results

In our study, the weight mean of left knee medial meniscus was found to be 1.87 (range of 1.44-2.49). The weight mean of right knee medial meniscus was 1.84(range being 1.40 – 2.21)

The paired t test when applied indicated no statistical difference between weight of left and right knee medial menisci with a p value of > 0.05.

The study showed the average inner circumference of medial menisci of the right knee was 6.2cm (range being 4.6-8.8cm).

No significant difference was found on applying the paired t test between the inner circumferences of both left and right knee medial menisci confirmed by a p value of >0.05.²⁰

The average outer circumference of the medial menisci of left knee was obtained to be 9.7mm (the range being 6.08- 11.06 cm).

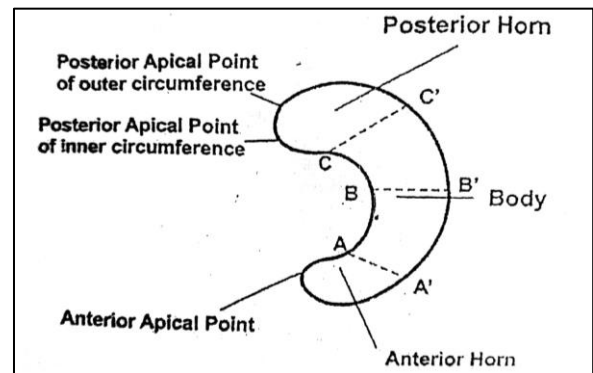


Fig. 1: Medical meniscus

In our study, the average right knee outer circumference of the medial menisci was recorded at 9.2cm (the range being 6.5- 11.5cm).

Paired t test revealed a p value of >0.05 signifying no statistical difference between the outer diameters of the left and right medial menisci.²¹

In this study the average width of the right knee anterior segment of medial menisci was 0.9cm (the range being 0.5 to 1.5cm) on applying the statistical analysis (paired t) between the two, p value was found to be >0.05, signifying no statistical difference between them.

The middle segment ranged from 0.7-1.6cm, the mean being 1.0cm. paired t test gave a value of >0.05, signifying no difference between them.

The left knee posterior segment width of the medial meniscus averaged at 1.5cm (range being 1.0-2.0 cm, whereas the right medial meniscus posterior segment mean obtained was 1.40cm (the range being 1.1 to 1.8cm).

No significant statistical difference was found between left and right medial meniscus widths as the p value obtained was >0.05.

Table 1: Weight (Range and mean) of left and right medial meniscus

S No.	Medial Meniscus	Range weight (g)	Mean wt (g)	T value	p- value
1	Left side	1.44-2.49	1.87±0.24	0.45	0.33
2	Right side	1.40-2.21	1.84±0.24		(>0.05)
	Combined	1.40-2.49	1.86±0.24		

Table 2: Inner circumference (Range and mean) of left and right medial meniscus

S. No.	Medial Meniscus	Range inner c (cm)	Mean inner c (cm)	T value	p- value
1	Left side	4.2-9.8	6.4±1.2	1.21	0.12
2	Right side	4.6-8.8	6.2±0.9		(>0.05)
	Combined	4.20-9.80	6.28±1.07		

Table 3: Outer circumference (Range and mean) of left and right medial meniscus (22)

S No	Medial Meniscus	Range outer c (g)	Mean outer c (g)	T value	p- value
1	Left side	6.8-11.6	9.7±1.2	1.70	0.055
2	Right side	6.5-11.5	9.2±1.3		(>0.05)
	Combined	6.5-11.6	9.46±1.26		

Table 4: Width (Range and mean) of different segments of left and right medial meniscus

S. No.	Parts of Medial Meniscus	Range outer c (cm)	Mean (in cm)
1	Ant segment	0.5-1.5	0.95+0.25
2	Middle segment	0.7-1.6	1.02+0.25
3	Posterior segment	1.0-2.0	1.46+0.26
	Combined	0.83-1.67	1.12+0.21

Conclusion

In this study, no significant difference between the various parameters of left and right medial menisci was obtained on the application of the statistical test (paired t test) with a p value of >0.05. This data can be of significance to the health care professionals involved in managing the meniscus injuries.

Bilateral meniscus tears are common in athletes especially the football players. Meniscus morphological equivalence on both sides guides in placing the sutures for meniscus repair saving the time required to measure the circumference of Menisci at various levels.

Health professionals that work with meniscal injuries should have knowledge of the possible anatomical variation that may be present in the meniscus to help with rehabilitation protocol.²³

Conflict of Interest: None.

References

- Canale. Knee Injuries. Campbell's Operative Orthopaedics. 11th edition 2008;3:2417-31.
- Calliet. Mechanical changes in the knee after meniscectomy. *J Bone Joint Surgery Am* 1976;58-9.
- Hayashi. Arthroscopic Meniscectomy for discoid lateral meniscus in children. *J Bone Joint Surg* 1989;70A(10):1495-1500.
- Soames RW. Skeletal system. In: Gray's Anatomy. The anatomical basis of Medicine and Surgery. 38th edition. 1999;697.
- Almeida S. K. S., Demoraes, A. S. R., Tashiro T, Neves S. E, Toscano, A. E. & Deabreu, R. R. M. Morphometric study of menisci of the knee joint. *Int J Morpho*, 2004;22:181-4.
- Fairbank TJ. Knee joint changes after meniscectomy. *J Bone Joint Surg* 1948;30B:664.
- Crenshaw AH. Knee Injuries. In: Campbell's Operative Orthopaedics, Vol III 13th Edition; 2017;2140-2143.
- Crenshaw AH. Knee Injuries. In: Campbell's Operative Orthopaedics, Vol III 13th Edition; 2017;2140-2143.
- Shrive N. Weight bearing role of the menisci of the knee. *J Bone Joint Surg* 1974;56B:381.
- Arnoczky SP, Warren RF, microvasculature of the human meniscus. *Am J Sports Med* 1982;10:90.
- Turek S. The knee. In: Orthopaedics- Principles and their application, Vol II, 6th edition; 2005:589-90.
- Braz, P.R.P. and Silva, W.G. Meniscus morphometry study in humans. *J Morpho Sci* 2010;27(2):62-6.
- DeHaven DE, Arnoczky SP. Meniscal repair. *J bone Joint Surg Am* 1994;76-140.
- Mow VC, Holmes MH, Lai WM. Fluid transport and mechanical properties of articular cartilage: A review. *J Biomech* 1984;377-94.
- Messner K, Gao J. The menisci of the knee joint. Anatomical and functional characteristics and a rationale for clinical treatment. *J Anat* 1998;161-78.
- Brain Day, Sunhick. The vascular and nerve supply of the human meniscus. *J Arthrosc Related Surg* 1985;1(1):58-62.
- Arnoczky SP, Warren RF. Microvasculature of the human meniscus. *Am J Sports Med* 1982;10:90-95.
- Chen FS, Rokito AS, Pitman MI. Acute and chronic posterolateral rotatory instability of the knee. *J Am Acad Orthop Surg* 2000;8:97-100.
- Miller MD. The knee I: Review of Orthopedics 5th edition. 2008;253-57.
- Henning CE, Lynch MA, Clark JR. Vascularity for healing of meniscus repair. *Arthrosc J Anat* 1987;3:13.
- Murlimanju BV. Morphometric Analysis of the menisci of the knee joint in south Indian human foetuses. *J. Morphol* 2010;28(4):1167-71.
- Andrish J. Meniscal injuries in children and adolescents: Diagnosis and management. *J Am Acad Orthop Surg* 1996;4:231-71.
- Ramachandran M. The meniscus. In: Basic Orthopaedic Sciences. 6th edition. 2007;81-83.

How to cite this article: Kaur A, Chaudhary P, Kalyan GS, Bal GS. Observational study of morphometric parameters of the medial meniscus of the knee joint in 30 Adult cadavers. *Indian J Clin Anat Physiol* 2019;6(2):130-2.