

Anatomical study of size variability of temporal and occipital horns of lateral ventricles of human brain: MRI study

Archana G. Kalyankar¹, Dope Santoshkumar A^{2*}, Shivaji B. Sukre³, Pravin H. Shingare⁴

^{1,2}Associate Professor, ³Professor and Head, ⁴Director, Dept. of Anatomy, ^{1,3}Government Medical College, Aurangabad, Maharashtra, ²Government Medical College, Latur, Maharashtra, ⁴DMER Office, Mumbai, Maharashtra, India

***Corresponding Author: Dope Santoshkumar A**

Email: drdopesantosh@yahoo.co.in

Received: 11th November, 2018

Accepted: 23rd February, 2019

Abstract

Introduction and Aims: The lateral ventricles lies in each cerebral hemisphere with its three horns and body. The study of normal and variant anatomy of ventricles of brain is very useful for clinicians and neurosurgeons in their routine practice. This study is directed to look for the changes in size of occipital and temporal horn of lateral ventricle as per age and sex of brain by MRI study.

Materials and Methods: MRI scan of 55 patients (25 females and 30 males) with age ranging from 1yr to 90 years were studied and the diameter of occipital and temporal horns were measured. Data was analyzed with respect to age and sex of individuals.

Results: It was observed that mean diameter of both horns decreases from 1yr to 10yr age group and increases from then to advancing age. No significant gender difference in dimensions of both the horns of lateral ventricle was observed.

Conclusion: The present study showed that the age factor is responsible for change in the size of occipital and temporal horns of lateral ventricle. The present study will be helpful to radiologist and neurosurgeons to differentiate the enlarged size of occipital and temporal horns by aging from that of other pathological conditions.

Keywords: Lateral ventricle, Occipital horn, Temporal horn.

Introduction

The ventricular system is set of four interconnected cavities in the brain, where cerebrospinal fluid is produced and circulated. Among the all ventricles of ventricular system lateral ventricles are largest one. Each lateral ventricle has three horns, frontal horn in frontal lobe, occipital horn in occipital lobe, temporal horn in temporal lobe and body in parietal lobe.

The utility of normal and variant anatomy of ventricles of brain for clinicians and neurosurgeons in their routine practice is very important.¹ The development of lateral ventricles itself is a forecaster for whole brain development and remains as unique marker for the same.² Neurosurgeons as well as radiologist faced challenges regarding size of lateral ventricles are within normal limit or due to aging of individuals.

The cortical atrophy in neurodegenerative conditions, hippocampal size alternation in Alzheimer's disease shows ultimate affection over the lateral ventricle size especially temporal horn of lateral ventricles. The other pathological conditions such as Balint's syndrome, Gestermann's syndrome also finds cortical atrophy.^{1,3}

5-12% of population in the world shows asymmetry in size of lateral ventricle. Similarly handedness of particularly individual also determines the size of lateral ventricle in the sense that of left handed person have longer occipital horn of lateral ventricle in comparison with right handed person.⁴

The goal of the study is to look for the changes in size of temporal and occipital horn of both lateral ventricles as per age and sex of individual. This MRI study is comparatively useful for surgeons as temporal and occipital horns are surrounded by important functional areas.

The present study is based on MRI scan of 55 patients (25 Female and 30 Male) of known patient taken retrospectively over the period of 3 years from May 2015 to 2018.

Aims and Objectives

1. To measure and analyze variable parameters of temporal and occipital horn in the MRI scan image.
2. To compare and contrast the available finding of present study with that of previous study.

Anatomy and Development of Lateral Ventricle

Each lateral ventricle is C-shaped cavity structure begins at temporal horn in temporal lobe of cerebral hemisphere then travels as body in parietal lobe and terminates at interventricular foramina of Monro into 3rd ventricle. Each lateral ventricle has extension in occipital lobe as posterior horn and in frontal lobe as frontal horn.^{4,5}

The lateral ventricles develops from the central canal of neural tube. The portion of tube in developing prosencephalon during three months of prenatal life gives origin to lateral ventricle by expansion of central canal. Later the choroid plexus appears which produce cerebrospinal fluid.⁶

Materials and Methods

Present study was acquired on MRI images of 55 patients (25 Female and 30 Male of known age) this retrospective study conducted on the patients who were referred for MRI scanning of brain from the clinicians as optional investigation.

Mostly patients referred were of road accident victims. The MRI suggested for something else as grey or white

matter disruption, internal vascular accidents, any internal injury. Their proper consent was taken for the same.

The radial width of temporal horn and occipital horn of lateral ventricle were measured with precision caliper at the tip of the horn on high quality MRI image.

So in this way both highest horizontal and vertical diameters were measured in centimeters. The measurement obtained as per age and sex were tabulated for further study.

Magnetic resonance image gives better soft tissue contrast. So essentially T2 weighted sequence taken to examine ventricular system.

Observation and Result

The mean horizontal and vertical diameters of temporal and occipital horns of both right and left side was calculated as per age group 1-10, 11-20, 21-30, 31-40, 41-50, 51-60, 61-70, 71-80, 81-90. Also the findings were grouped under male and female category.

Table 1: Illustrate mean diameters (cm) of bilateral temporal and occipital horn as per age group

Age group	No of patient studied	Temporal Horn				Occipital Horn			
		Right		Left		Right		Left	
		Horizontal (cm)	Vertical (cm)	Horizontal (cm)	Vertical (cm)	Horizontal (cm)	Vertical (cm)	Horizontal (cm)	Vertical (cm)
1-10	7	0.64	0.42	0.56	0.44	0.96	1.10	1.12	1.00
11-20	5	0.60	0.46	0.63	0.44	0.87	0.91	0.98	1.07
21-30	7	0.72	0.35	0.76	0.34	0.89	1.14	1.03	2.05
0.71	4		0.39	0.73	0.44	0.74	1.19	1.00	1.34
0.58	4		0.43	0.58	0.35	1.00	1.49	0.97	1.27
0.76	13		0.55	0.75	0.48	1.25	1.57	1.25	1.42
0.72	8		0.57	0.83	0.96	1.26	1.44	1.54	1.71
0.73	6		0.63	0.79	0.61	1.56	1.76	1.57	1.77
81-90	1	0.93	0.46	0.96	0.53	1.62	2.13	2.14	1.87

Table 2: Illustrate mean diameter (cm) of bilateral temporal and occipital horn as per age group in male

Age group	No of patient studied	Temporal Horn				Occipital Horn			
		Right		Left		Right		Left	
		Horizontal (cm)	Vertical (cm)	Horizontal (cm)	Vertical (cm)	Horizontal (cm)	Vertical (cm)	Horizontal (cm)	Vertical (cm)
1-10	5	0.51	0.38	0.58	0.34	0.82	0.99	1.01	0.93
11-20	2	0.47	0.37	0.63	0.39	0.93	0.75	0.88	0.83
21-30	3	0.75	0.28	0.83	0.35	0.83	0.94	0.78	1.03
31-40	2	0.73	0.43	0.64	0.53	0.64	1.32	1.08	1.56
41-50	3	0.66	0.50	0.62	1.61	0.97	1.61	0.98	1.4
51-60	7	0.48	0.63	0.73	0.53	1.36	1.81	1.38	1.54
61-70	4	0.51	0.38	0.48	0.42	1.19	1.16	1.16	1.41
71-80	3	0.56	0.46	0.61	0.46	1.33	1.65	1.42	1.85
81-90	1	0.93	0.46	0.96	0.53	1.62	2.13	2.14	1.87

Table 3: Illustrate mean diameter (cm) of bilateral temporal and occipital horn as per age group in female

Age group	No of patient studied	Temporal Horn				Occipital Horn			
		Right		Left		Right		Left	
		Horizontal (cm)	Vertical (cm)	Horizontal (cm)	Vertical (cm)	Horizontal (cm)	Vertical (cm)	Horizontal (cm)	Vertical (cm)
1-10	2	0.72	0.52	0.51	0.69	1.29	1.38	1.39	1.16
11-20	3	0.62	0.52	0.62	0.46	0.82	1.02	1.03	0.84
21-30	4	0.69	0.39	0.70	0.34	0.93	1.29	1.21	1.31
31-40	2	0.69	0.35	0.81	0.35	0.84	1.08	0.91	1.11
41-50	1	0.35	0.21	0.44	0.20	1.09	1.11	0.96	0.86
51-60	6	0.73	0.45	0.77	0.41	1.13	1.29	1.09	1.28
61-70	4	0.92	0.75	1.18	1.48	1.33	1.71	1.91	2.00
71-80	3	0.89	1.79	0.97	0.76	1.71	1.85	1.71	1.69

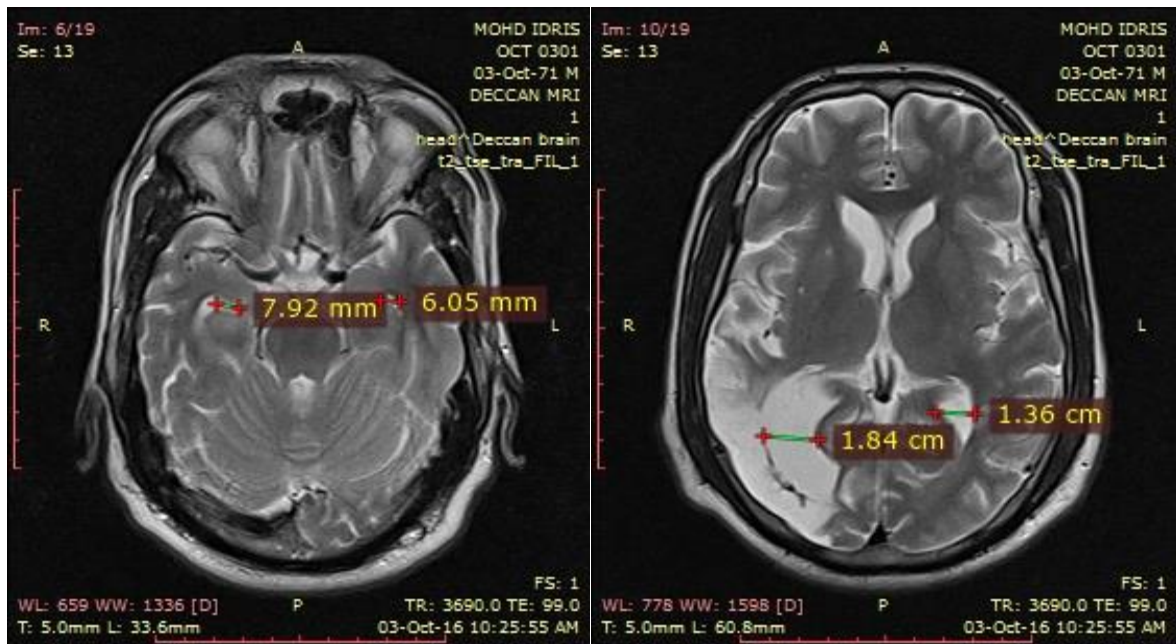


Fig. 1: MRI image of 45yr old male showing temporal and occipital horn horizontal diameter

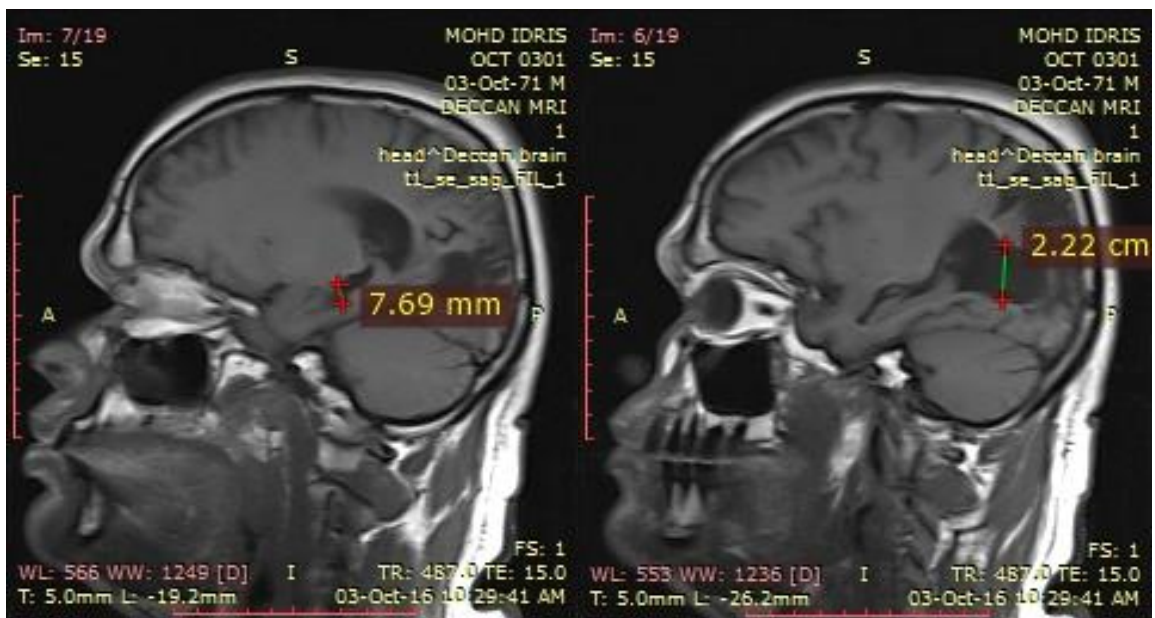


Fig. 2: MRI image of 45yr old male showing temporal and occipital horn vertical diameter

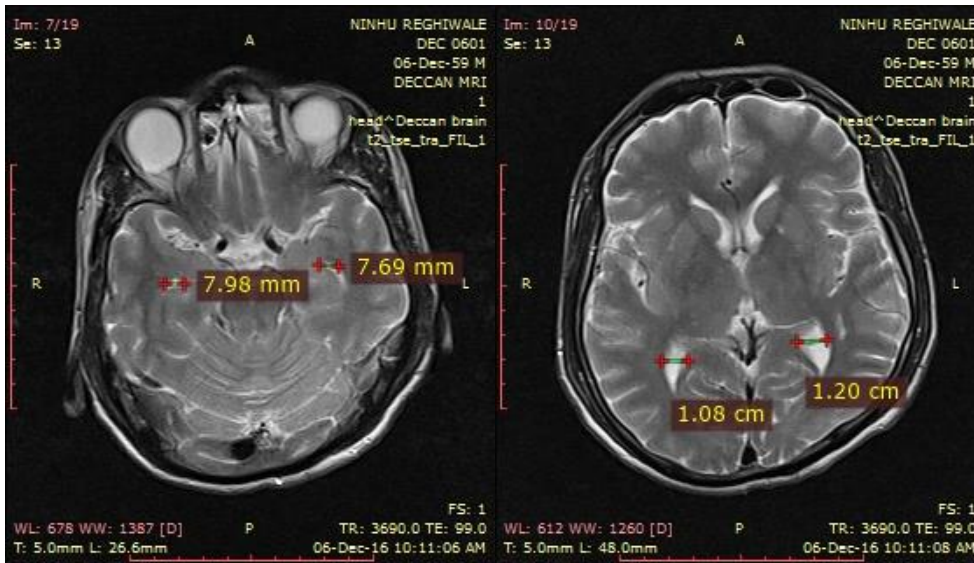


Fig. 3: MRI image of 57yr old female showing temporal and occipital horn horizontal diameter

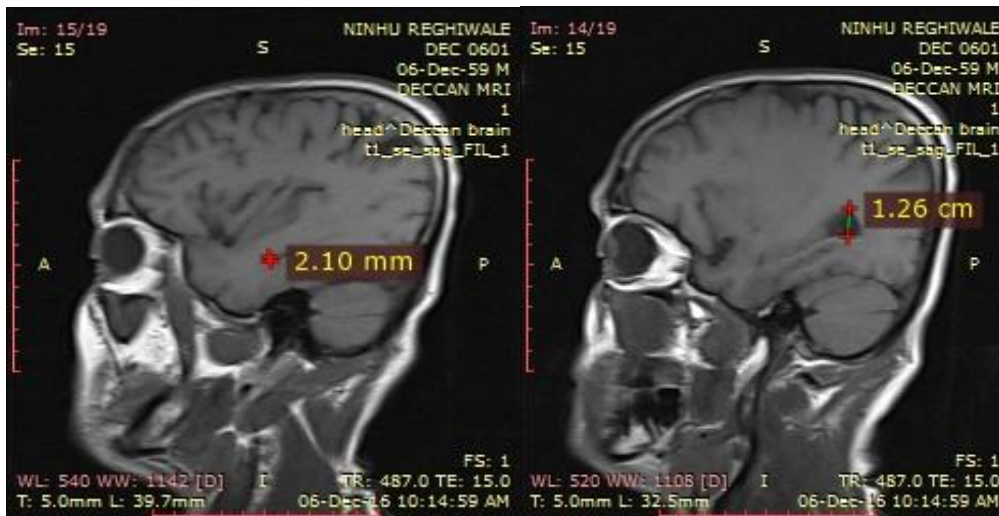


Fig. 4: MRI image of 57yr old female showing temporal and occipital horn vertical diameter

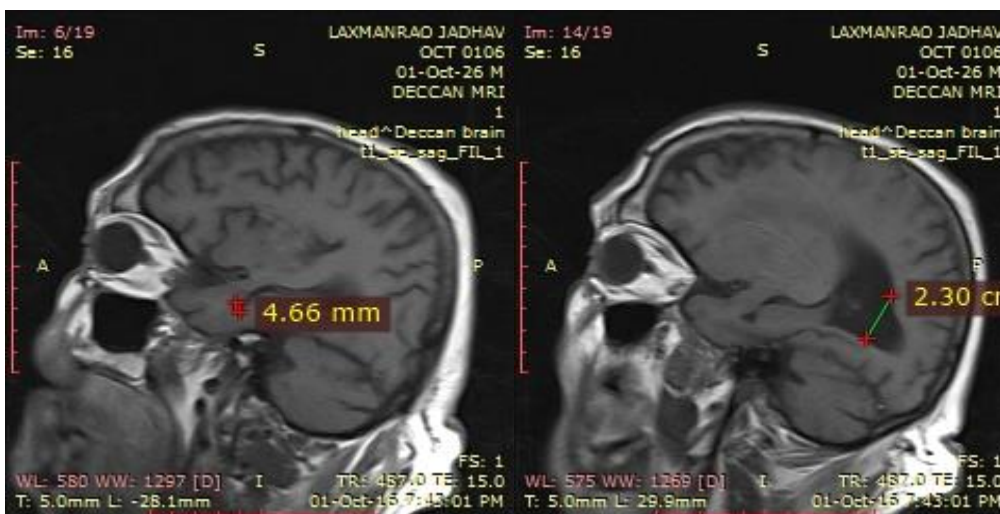


Fig. 5: MRI image of 90yr old male showing temporal and occipital horn vertical diameter

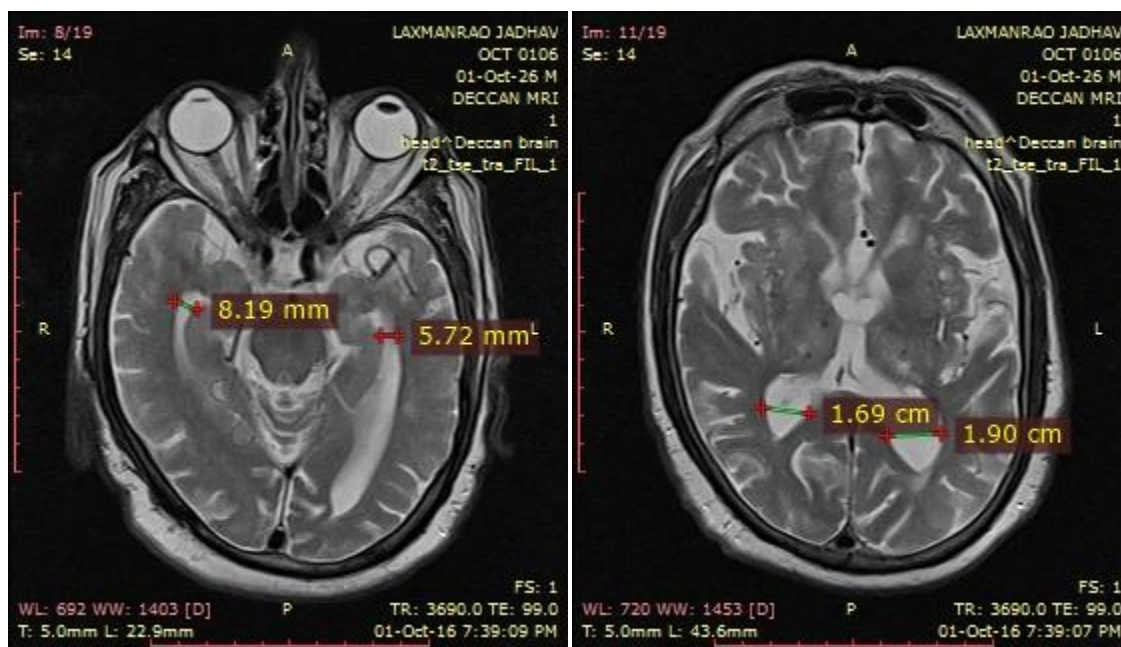


Fig. 6: MRI image of 90yr old male showing temporal and occipital horn diameter

The mean horizontal diameter of temporal horn of both side were decreasing from age group 1 to 10 to 31-40 while it show increase in diameter from 31-40 age group to 81-90 age group.

Also mean vertical diameter of bilateral temporal horn shows hike from age group 1-10 to 31-40 age group while decrease in diameter from 31-40 age group to 81-90 age group.

In occipital horn mean horizontal diameter of both sides show decrease from 1-10 age group to 31-40 age group and shows increase in diameter from age group 31-40 to 81-90 age group. But the mean vertical diameter of both occipital horns showed consistent increase from age group 1-10 to 81-90 age group.

Similarly mean diameter of temporal and occipital horn showed no gross difference in male and female cases. Thus the difference in size of both horns in male and female was insignificant.

Discussion and Conclusion

The increased volume of ventricular system in infant is because of hydrocephalus where there is abnormal accumulation of cerebrospinal fluid which is of two types communicating or non-communicating.

Larger lateral ventricles in parietal region were related to poorer motor development at 2 yrs. Similarly increased ventricular measurements were also related to slower early language development. So surrounding brain growth and intellectual enhancement may be responsible for decrease in temporal and occipital horn diameters in young age groups.^{7,8}

The pathological conditions like Alzheimers disease cause posterior cortical atrophy which is neurodegenerative condition. This produce dilatation of posterior horn of lateral ventricle. Similarly enlargement of posterior and

temporal horns of lateral ventricle results into development of structural and functional changes in the respective areas of involvement.^{9,10}

The picture of fairly symmetrical ventricular system of two sides not cleared in many articles, so frequent asymmetry between both side of normal ventricle are less appreciated. The variant anatomical dimension of lateral ventricles is of great academic interest regarding CSF circulation and also for clinical, radiological and surgical interventions. The volume of cerebral ventricles is determined by nuclei and white matter tracts that abut them and rate of ventricular expansion is accelerated with age. Aging is responsible for loss of white matter integrity. The changes occur in white and grey matter volume in occipitoparietal and temporal region due to aging or pathological causes ventricular expansion.^{11,12}

The temporal horn enlargement seen in hydrocephalus due to increased intraventricular pressure. Similarly congenital anomalies showed agenesis of corpus callosum with enlarged temporal horn. Incomplete inversion of hippocampal formation during the development showed the configuration of enlarged temporal horn. These findings were also found in premature infants who have incomplete sulcation. In dogs the ventricular enlargement was found to be related with aging process.^{13,14}

Baker L analysed 75% of patient with brain anomalies had enlarged temporal horn mostly involving inferolateral aspects of ventricle. The patient with hydrocephalus has also showed temporal horn enlargement in superolateral region. The ventricular enlargement was as result of increased intraventricular pressure.

The rate of ventricular volume change is highly correlated with an increase in senile plaques due to old age.^{9,15}

Kunjan M studied on 12 patients retrospectively. He noted changes in grey and white matter in parieto-occipital region and ventricular expansion due to recurrent falls. He also mentioned age, hypertension and diabetes could be the factor which aggravates above condition.^{1,16} Torkildsen shows greatest variations of occipital and temporal horn size between right and left ventricle. The size of posterior horn of lateral ventricle measured average 1.39 cm in 11 brains and that of temporal horn 4.08cm in left side. On right side occipital horn measured 1.45cm and temporal horn measured 3.97 cm. He measured these horns by ventriculography.⁵

So the normal intact size of occipital horn and temporal horn is not mentioned in any studies before.

By taking into consideration of fact that visual area surrounding the occipital horn and hippocampal area around temporal horn, the enlargement of both occipital and temporal horn ultimately shows disturbance and compression symptoms in nearby and surrounding structures of both horns.

To summarize we have compared the pattern of temporal horn and occipital horn enlargement in different age groups individuals. The distinct morphology and size of temporal and occipital horn was noticed with remarkable differences as per age of individuals.

As the study was done on brain MRI scans of patients, with the detailed clinical history. Our next goal is to measure and analyse occipital and temporal horn size in cadaveric brain and compare it with present study.

Conflict of Interest: None.

References

1. Nagaratnam N, Nagatarnam K. Enlargement of the posterior horns of the lateral ventricles and recurrent falls: A clinical study. *J Clin Gerontol Geriatr* 2016;7(1):27-30.
2. Srijit D, Shipra P. Anatomical study of anomalous posterior horn of lateral ventricle of brain and its clinical significance. *Bratisl Lek Listy* 2007;108(9):422-4.
3. Bates J, Netsky M. Developmental anomalies of the horns of the lateral ventricles. *J Neuropathol Exp Neurol* 1955;14(3):316-25.
4. Torkirson A. The gross anatomy of the lateral ventricle. The department of Neurology and neurosurgery, University of McGill 1924:480-91.
5. Gray H. Nervous system. Williams P L. Gray's Anatomy. 38th edition. Churchill Livingstone Edinburgh;1998:1205-7.
6. Moore K L, Persaud TVN. The nervous system. The developing human- clinically oriented embryology, 6th edition; WB Saunders company, Toronto 1998: 465-7.
7. Soni SP, Gupta BD. Normal parameters of ventricular system in healthy infants. *Indian Paediatrics* 1995;32:550-5.
8. Fore L M, Choo P. The relationship between ventricular size at 1 Months and outcome at 2 years in infant less than 30 weeks gestation. *Br Med J* 2014;(F)1-6.
9. Baker L L, Barkovich A J. The large temporal horn: MR analysis in developmental brain anomalies versus hydrocephalus. *Am J Neuroradiol* 1992;13(1):115-22.
10. Heinz ER, Ward A, Drayer BP, Dubois PJ. Distinction between obstructive and atrophic dilatation of ventricles in children. *J Comput Assist Tomogr* 1980;4:320-5.
11. Sjaastad, Skalte LO, Engset A. The width of the temporal horn and the differential diagnosis between pressure hydrocephalus and hydrocephalus ex vacuo. *Neurol* 1969;19:1087-93.
12. Childe AE, Penfield W. Anatomic and pneumographic studies of the temporal horn. *Arch Neural Psychiatry* 1937;37:1021-34.
13. Lindgren E. A pneumoencephalographic study of the temporal horn with special reference to tumors in the temporal region. *Acta Radio/ (Suppl)* 1948;69:1-151.
14. Martazami M M, Adeeb M. The ventricular system of the brain: A comprehensive review of its history, Anatomy, histology. *Embryol Surg Consideration, Childs Nerv Syst* 2012;30(1):19-35.
15. Du AT, Schuff N, Chao L, Kornak J, Ezekiel F. White matter lesions are associated with cortical atrophy more than entorhinal and hippocampal atrophy. *Neurobiol Aging* 2005;26:553-9.
16. Vernooij MW, De Groot M, Van Der Lugt A, Ikram M, Hrestin G, et al. White matter atrophy and lesion formation explain the loss of structural integrity of white matter in aging. *Neuroimage* 2008;43:470.

How to cite this article: Kalyankar AG, Dope SA, Sukre SB, Shingare PH. Anatomical study of size variability of temporal and occipital horns of lateral ventricles of human brain: MRI study. *Indian J Clin Anat Physiol* 2019;6(2):133-8.