

Elevated ramification of arterial brachialis and its quantifiable impact

Karishma Sharma^{1*}, Prashant Prasad², M.S Ansari³, K.S Ravi⁴, Brijendra Singh⁵

¹PhD Scholar, ²PG Student, ^{3,4}Associate Professor, ⁵Professor and Head, Dept. of Anatomy, All India Institute of Medical Sciences, Rishikesh, Uttarakhand, India

*Corresponding Author: Karishma Sharma

Email: karishma.ssharma4249@gmail.com

Received: 18th March, 2019

Accepted: 18th April, 2019

Abstract

Introduction: Knowledge of variations play significant role in medical sciences and surgical outcome. Discrepancy of arterial Brachialis should be known and kept in mind of radiologists, surgeons during surgical procedures, reconstructive surgeries, measuring blood pressure. So to prevent any accidental detriment, cognizance and scrutiny of anatomical variation is very important.

Materials and Methods: Prevalent engagement was carried out on 12 upper limbs of 6 cadavers, during dissection in Branch of Anatomy, AIIMS Rishikesh, independent of age and sex. All dissections was done as per Cunningham handy guidebook of Anatomy, during dissection for undergraduate students. Variations were observed and noted.

Observation and Result: Arm length varied from 29 to 35 cm on right or left side. Branching pattern was uniform in (100 per cent cases) of left arm, arterial Brachialis was splitted in Radial and Ulnar artery in cubital fossa. But in right limb 4 (66.70 per cent) constrains of divarication was in cubital-fossa, 1(16.70 per cent) in middle third arm and 1 (16.70 per cent) cases in upper third arm directed to the acromian process.

Conclusion: We noted that disparity in arterial brachialis is frequent. There is no compelling association between arm- magnitude and the level of Arterial brachialis partition. Association of Anatomical disparity in branching outline of arterial Brachialis is vital to avert unintended injury to blood vessel during any interventional clinical procedure.

Keywords: Arterial brachialis, Cubital fossa, Bifurcation, Arm, Cadaver.

Introduction

Brachial means "Comprehended to arm". Arteria Brachialis is prolongation of supplementary artery. It begins at substandard border of tendon of teres major and ends about a centimeter distal to elbow joint in cubital fossa. First it is medial to humerus then progressively spiral anterior to it awaiting it lies midway sandwiched between humeral epicondyles. Arterial Brachialis is ostensibly enclosed with skin, superficial fasciae and subterranean fasciae.¹

Law of vascular anatomy that remain constant is variations. Arterial variations are common in living and lifeless individuals; it varies between inhabitants living in unlike places, countries. It's that some arteries have more incidence of variations then others. In upper limb the prevalence of discrepancy is 18.53% to 20%. Karlsson,² Niechajev and Compta³ pragmatic lofty beginning of radial artery is commonest vascular dissimilarity of upper limb. Treves and Roger⁴ bring into being superficial brachial, a common anomaly as vas aberrans.

Anatomical knowledge of variation in echelon of branching outline of arterial Brachialis is important during percutaneous arterial catheterization process. This prevents any major or minor complication arising during process due to lack of knowledge of level of dissimilarity and disparity in branching outline of brachial artery.

Knowledge of anomalous branching pattern of brachial and ante brachial arteries plays significant role during dialysis to treat chronic renal failure as radial artery and cephalic veins are best choice for arteriovenous fistula in wrist². Clinical applications of arterial Brachialis are recording blood pressure, pulse doppler sonography, arterial

puncture for gasometry. So by taking all these points into consideration study was conducted to know the level of Sub-Division and Sub-categorization of arterial Brachialis and its relation with arm length if any. Its knowledge will help in interventional clinical procedures as well as vascular and reconstruction surgeries.

Materials and Methods

The current study was approved out on 12 upper limbs of 6 cadavers, present in area of Anatomy, AIIMS, irrespective of age and sex. All dissections was done as per Cunningham handy instruction booklet of Anatomy, for the period of practical teaching for undergraduate students. Variations were observed and noted. Dissection was carried out from superficial to deep structures skin, superficial facia deep facia and arterial Brachialis was traced from its origin, course to its termination. Length of arm was calculated by measuring tape from acromian of scapula to lateral condyle of humerus. According to Cunningham handy guidebook of anatomy, cubital fossa was uncovered and arterial Brachialis divergence was measured, space between intercondylar line of humerus (line joining medial and lateral epicondyles) to point it branched. Statistical examination of data was done for proportion and Spearman's Rank Correlation. The results were considered statistically significant when $P < 0.05$.

Observation and Result

Among 12 upper limbs arm length varied from 29 to 35 cm on right or left side (Table 1,2). Majority of cases (100%) on left side branching was in cubital fossa and in 4(66.7%)

cases on right side, level of branching was in cubital fossa, 1(16.7%) was in middle 3rd of arm (Fig. 2) and 1(16.7%) was in upper 3rd of arm towards the acromian process (Fig. 1) (Table 3, 4). With help of Spearman's Rank Correlation, no momentous alliance was observed between length of arm and level of branching of arterial Brachialis as P value is 0.4 on left side and 0.3 on right side.

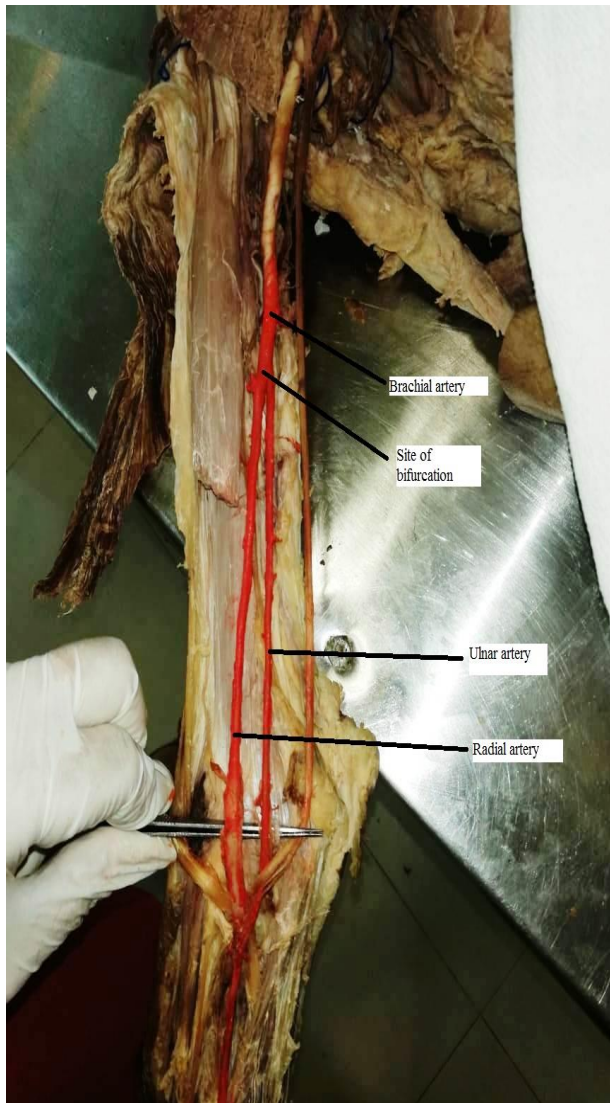


Fig. 1: Bifurcation at upper 3rd of arm

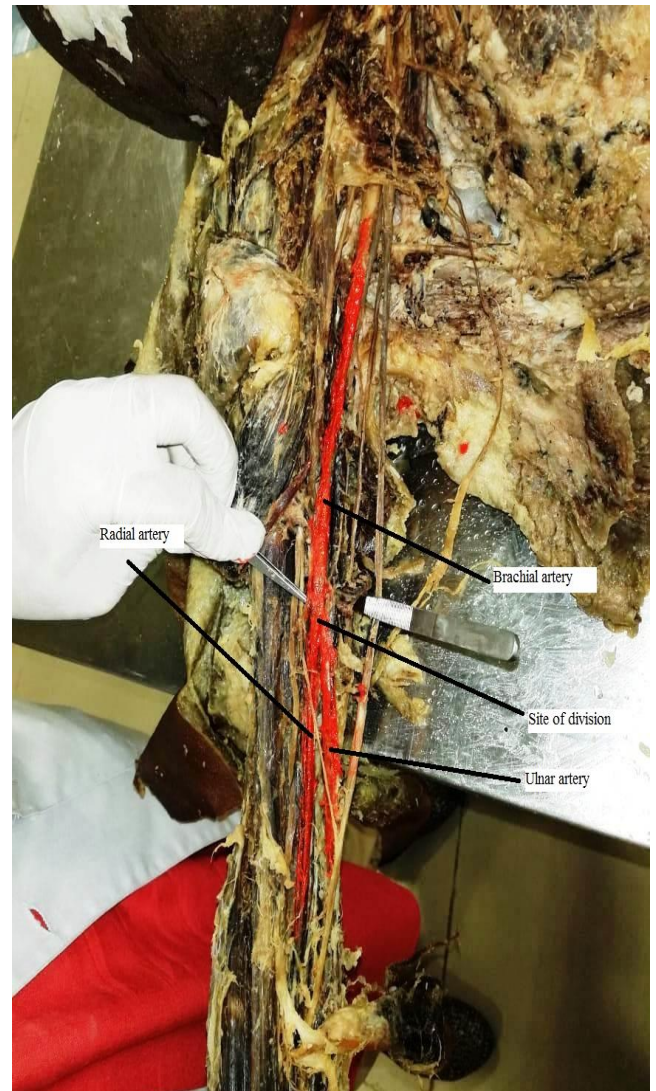


Fig. 2: Bifurcation at middle 3rd of arm

Discussion

Von Haller in 1813 noted arterial variation for the first time in upper limb.⁸⁻⁹ According to Rossi et al elevated dissection of arterial Brachialis was positioned 20cm beyond cubital fossa and 8.5 cm beneath axilla, in right side and 21.5 cm above cubital fossa, 7.0cm below axilla in left side of arm. Harbans Singh also observed mutual high splitting up of brachial artery.¹¹ High divergence of arterial Brachialis at lower edging of teres major was noted by Shewale. According to Uma Shivanal, lofty division of arterial Brachialis was pragmatic in one specimen (2%), and in our study branching was not homogeneous in right side but it was uniform on left side. In the left side divergence was at point of cubital fossa and on right side bifurcation was 1(16.7%) in middle 3rd of arm, 1 (16.7%) was in upper 3rd of arm and 4 (66.7%) in cubital fossa. Huber experiential supplementary kindling of brachial artery. He bring into being arterial Brachialis was tri-furcated in ulnar, radial, common interosseus or median arteries. Patnaik also

observed accessory branches in upper limb of 50 year old male cadaver.

Bansal and Vare reported lofty bi- separation of arterial Brachialis -superficial in arm and deep enduring as interosseus complex in forearm. Karlsson and Niechajev reported soaring dissection of radial artery as commonest vascular pattern in 10% of cases by angiograph. Same results was found by Patnaik¹⁵ et al in 14.27, and by Millar¹⁷ in 3%. Arterial Brachialis diverge proximally and come together to form single trunk observed by William et al.¹⁸ Satynarayana N establish dissection of arterial Brachialis at stage of inclusion of coracobrachialis in middle of right arm. Measurement lengthwise of arterial Brachialis was 11.5cm and had fewer calibers than usual, level of divergence was normal.¹⁹ Puspallata M also established high division of brachial artery.²⁰

Embryogenesis

Tangential division of seventh intersegmental artery (subclavian) gives axis artery for upper limb bud. It is separated into proximal and distal parts. Proximal part of key trunk gives axillary ongoing as arterial Brachialis and distal part persist anterior interosseus artery.

Radial artery arises first more proximally than ulnar artery comes from main trunk and crosses in front of median nerve. Last arteries emerge in forearm are radial and ulnar. Later on radial artery outline new alliance with main trunk at or near level of ulnar artery. Upper portion of main stem usually disappears. Consequently radial and ulnar arteries crop up at indistinguishable level in cubital fossa.

Arterial variation causes are many like local factors as position of fetus in uterus, early movement of limbs, unusual muscular development. At time of angiogenesis genetic factor involvement also contribute to arterial variation.²¹

Table 1: Position of separation of arterial brachialis on right side

S. No	Site of division	Towards acromian process	Towards wrist	Length of arm	Distance from AB line
1	Cubital fossa	no	yes	33cm	2cm
2	Cubital fossa	no	yes	35cm	1cm
3	Middle 3rd of arm	yes	no	32cm	13cm
4	Upper 3rd of arm	yes	no	35cm	10cm
5	Cubital fossa	no	yes	34cm	2cm
6	Cubital fossa	no	yes	34cm	2cm

Table 2: Position of separation of arterial brachialis on left side

S. No	Site of division	Towards acromian process	Towards wrist	Length of arm	Distance from AB line
1	Cubital fossa	no	yes	33cm	2cm
2	Cubital fossa	no	yes	35cm	1.5cm
3	Cubital fossa	no	yes	29cm	2cm
4	Cubital fossa	no	yes	35cm	2cm
5	Cubital fossa	no	yes	34cm	3cm
6	Cubital fossa	no	yes	34cm	2cm

Table 3: Association among arm length and echelon of termination (Spearman’s rank - correlation)

Area	ρ	P-Value
Left Side	-0.348	0.499
Right Side	-0.469	0.348

Table 4: Position of branching in proportion / percentage

Categorization of Point of termination	Left Side (%)	Right Side (%)	Total (%)
Cubital fossa	6 (100)	4 (66.7)	10
Middle 3rd of arm	0	1 (16.7)	1
Upper 3rd of arm	0	1 (16.7)	1

Conclusion

Arterial variation documentation is important to anatomists, surgeons in advanced techniques for micro vascular reconstructive surgeries, for measuring blood pressure, grafting etc. It is important for radiologist, cardiologist and vascular surgeons for better treatment planning. So we wrap up that there is unambiguous dissimilarity in the branching pattern of brachial artery. At the same time, there is no noteworthy association linking arm length and the level of arterial Brachialis bifurcation. The acquaintance of anatomical dissimilarity in branching blueprint of arterial Brachialis is crucial to prevent inadvertent damage to blood vessel during any interventional clinical procedure.

Limitations

Small sample size

Conflict of Interest: None.

References

1. Standring S, Gray S (2008) Anatomy (40th Edn) Spain, Churchill Livingstone, Elsevier pp: 830-5.
2. Karleson S, Niechajev A. arterial anatomy of the upper extremity. *Acta Radiological Diagn* 1982;23(7):115-21.
3. Compta XG. Origin of radial artery from the axillary artery and associated hand vascular anomalies. *J Hand Surg* 1991;16A:293-6.
4. Treves, Rogers. Surgical applied anatomy In. the upper extremity. 11th Edn. Cassell and Co. Ltd. London, 1947, pp 247
5. Junior R, Esteves, Simoes JS, Fernandes GJM. Bilateral high division of the arterial Brachialis in one human male cadaver: a case report. *J Morphol Sci* 2011;28(3):204-7.
6. Malcic-Gürbüz J¹, Gürünlüoğlu R, Ozdoğmuş O, Yalin A. Unique Case of Trifurcation of the Brachial Artery: Its Clinical Significance. *Clin Anat* 2002;15(3):224-7.
7. G J Romanes. Cunningham's manual of practical Anatomy" (New York, Oxford University Press, 2005) 67-71
8. Bidarkotimath S, Avadhani R, Kumar A. Primary pattern of arteries of upper limb with relevance to their variations. *Int J Morphol* 2011;29(4):1422-28.
9. Bidarkotimath S, Avadhani R, Kumar A, "An anatomical study of primary pattern of arteries of upper limb with relevance to their variations". *NUJHS* 2012;2(1):08-14.
10. Rossi Junior WC, Esteves A, Simões JS, Fernandes GJM. Bilateral high division of the arterial Brachialis in one human male cadaver: case report. *J Morphol Sci* 2011;28:204-7.
11. Singh H, Gupta N, Bargotra RN, Singh NP. Higher bifurcation of arterial Brachialis with superficial course of radial artery in forearm: case report. *JK Sci* 2010;12(1):39-40.
12. Shewale. Bifurcation of arterial Brachialis at it's commencement-A case report. *Biomed Res* 23(3):453-6.
13. Uma Shivanal, M.S. Trinesh Gowda. A study of variations in arterial Brachialis and its branching pattern. *Int J Res Med Sci* 2015;3(6):1392-6.
14. Huber GC. Piersol's human anatomy in the vascular system 9th Edn. Vol. 1 J.B. Lippincott Co. Philadelphia, 1930 pp 767-91.
15. Patnaik VVG, Kalse G, Sigla RK. Trifurcation of Arterial Brachialis – a case report. *J Anatomical Soc India* 2001;50(2):163-5.
16. Vare AM, Bansal PC. A case of anomalous arterial Brachialis and other associate vascular anomalies in a single upper limb. *J Anatomical Soc India* 1969;18 (2):50-3.
17. Miller RA. Observations upon the arrangement of axillary artery and brachial plexus. *Am J Anat* 1939;64:143-63.
18. Williams PL, Bannister LH, Berry M.N, Collins P, Dyson M, Dussek JE, Ferguson MWJ. Gray's Anatomy. Cardiovascular system 38th Edn. Churchill Livingstone, New York, 1995, pp1538-1540
19. Bidarkotimath S, Avadhani R, Kumar A. Primary pattern of arteries of upper limb with relevance to their variations. *Int J Morphol* 2011;29(4):1422-8.
20. Puspaltha M, Haq I. Bilateral high divisions of the arterial Brachialis - a case report. *Anatomica Karnataka* 2010;4(1):59-61.
21. Ahmet Uzun, Leonard L Seelig Jr. The anastomotic artery connecting the axillary or brachial artery to one of the forearm arteries. *Folia Morphol* 2000;59(3):217-20.

How to cite this article: Sharma K, Prasad P, Ansari MS, Ravi KS, Singh B. Elevated ramification of arterial brachialis and its quantifiable impact. *Indian J Clin Anat Physiol* 2019;6(2):158-61.