

Cadaveric morphological study of superior transverse scapular ligament and its clinical correlation

Usha Dandekar^{1*}, Kundankumar Dandekar²

¹Associate Professor, ²Professor, ¹Dept. of Anatomy, ²Dept. of Surgery, Rural Medical College, Pravara Institute of Medical Sciences, Deemed University, Ahmednagar, Maharashtra, India

***Corresponding Author: Usha Dandekar**

Email: drushadandekar@yahoo.co.in

Received: 8th December, 2018

Accepted: 29th January, 2019

Abstract

The two ends of suprascapular notch [SSN] are bridged by a sturdy fibrous band like superior transverse scapular ligament [STSL]. This bridging is responsible to convert the notch into foramen providing passage to suprascapular nerve. This anatomical relation has potential of compressing the nerve which may result in a condition called suprascapular nerve entrapment syndrome (SNES). A cadaveric morphological study was undertaken on 31 cadavers to study the details of morphology of STSL considering its role in causation of SNES and to elucidate the anatomical basis of the entrapment neuropathy. The results revealed single STSL in 98.4% and bifid STSL in 1.6%. According to shape, fan shaped STSL were found in 74.2%, band shaped STSL in 24.2% and bifid STSL in 1.6%. The mean cross sectional area of suprascapular opening was 32.89 mm², 18.86mm² and 22mm² in specimens with fan shaped, band shaped and bifid STSL respectively. The anatomical relations of suprascapular vessels to STSL were recorded as: First type (29.03%) showed the presence of suprascapular vein below the STSL and the suprascapular artery above it. The second type (54.84%), revealed the placement of both suprascapular artery and vein were above the ligament. The third type showed the passage of all the structures i.e. nerve, vein and artery below the ligament (16.13%). Complete ossification of STSL was noted in only one specimen while thirteen specimens showed partial ossification. Etiology of SNES consists of apparent incriminating anatomy in the form of shape and type of STSL. The surgical relief aims at decompression of suprascapular nerve by excising the STSL. Cadaveric study of STSL providing idea of variations of its morphology shall be of help to surgeons and arthroscopist to plan their approach in treatment of SNES.

Keywords: Superior transverse scapular ligament, Suprascapular nerve entrapment syndrome.

Introduction

The two ends of suprascapular notch [SSN] are bridged by a sturdy fibrous band like superior transverse scapular ligament [STSL]. This bridging is responsible to convert the notch into foramen providing passage to suprascapular nerve. The STSL is attached to the root of coracoid process laterally and to the limit of SSN medially. The Suprascapular nerve travels through the notch roofed by this ligament. The STSL has variable relations to the suprascapular artery and vein but commonly they are found above the ligament.

As quoted by Iqbal et al the crowding and anatomical reduction in the space for passage of suprascapular nerve shall potentially lead to suprascapular nerve entrapment syndrome (SNES).¹ Zehetgruber et al added that SNES as a cause is considered to contribute in 1% to 2% of the total shoulder girdle pain.² SNES was first described by Andre Thomas in 1936 and he was the one to explain the mechanism behind causation of SNES.³ SSN, STSL and SNES are closely related terms. Any search of literature for SSN leads to the extensive studies on dry scapulae and because the suprascapular nerve travels through this notch with possibility of obstruction in suprascapular notch, the discussion always ends in correlation of notch to the clinical condition of SNES. The orthopedic literatures emphasize on clinical aspect of SNES but many of them cite references which are based on studies of dry scapulae having no direct correlation with the sex or age of the patient and even the data regarding the previous history of SNES or shoulder

pain is not available. Also in dry scapular study, the surrounding soft tissue anatomy in SSN region is not available for correlation of available space for the nerve predicting its impingement potential capability, possibility or probability.

Importance of SSN is underlined because it is a peculiar structure that allows passage to the suprascapular nerve through a foramen formed due to bridging by the STSL. This arrangement may lead to clinical condition resulting into shoulder girdle pain. In severe cases the muscles namely supraspinatus and infraspinatus may get atrophied. In SSN region, compression of suprascapular nerve is possible because of variable anatomy of SSN or STSL.

Polguy et al⁴ in 2013 classified STSL into three types. In the first type the ligament had a uniform fan shape. In this type the ratio of proximal width to distal width was equal or more than two. The ligaments were thicker at the distal end than the proximal end. The second type was band shaped. The ratio between proximal width and distal width was less than two and the ligament was similar to the first type in thickness. The third type was bifid with two separate bands. Medially they were attached separately to SSN on its medial border while their lateral ends were attached to common point on lateral border of SSN. The thickness at proximal and distal ends was same. Polguy et al.⁵ divided the bifid STSL into two subtypes taking into consideration its topography. The first type consisted of bifid STSL having two bands i.e. superior and inferior while the second type showed bifid STSL having anterior and posterior bands.

The study of SSN in dry scapulae will not give an idea of exact space available for suprascapular nerve in SSN as the main characters of suprascapular nerve and STSL who play major role in SNES are missing. In cadaveric dissection the effect of variations in morphology of STSL on suprascapular nerve and its relation to the suprascapular opening cross sectional area will be helpful. Considering that not many cadaveric studies are available on SSN region, the present work was carried out to emphasize on morphology of STSL which is important contributing factor in causation of SNES as well as to delineate the detailed anatomy of this region with the aim to elucidate the anatomical basis of the entrapment neuropathy.

Materials and Methods

This study consisted of careful dissection of 31 formalin fixed cadavers (27 Males and 4 females) which were used by MBBS students for dissection in the Rural Medical College Loni in the department of Anatomy. The study was undertaken only after receiving the ethical clearance from the Ethical Committee of Pravara Institute of Medical Sciences Deemed University to which the Rural Medical College is affiliated. [Letter PIMS/IEC-DR/2018/134 Reg. No: PIMS/ DR/ RMC/ 2018 /254]. The cadavers here are procured and maintained in the Rural Medical College, Loni, registered under Bombay Anatomy Act 1949 with state of Maharashtra.

Cadavers with any operative procedure in suprascapular notch region or topographical derangement of shoulders were excluded. The suprascapular region was dissected. The trapezius was reflected, followed by reflection of muscles namely the deltoid followed by subscapularis muscle and supraspinatus muscle. The suprascapular ligament was carefully dissected and its relation to the suprascapular vessels and nerve were delineated. The morphology of STSL, its relation to suprascapular nerve and vessels and presence of any abnormal masses in this area were recorded. The cross sectional area of the suprascapular opening was calculated using the mathematical formula of calculating the area of an ellipse as described in an article by Mitchel.⁶

[Area = $\pi \times D1/2 \times D2/2$ (D1=Vertical diameter of suprascapular opening & D2= Transverse diameter of the suprascapular opening)]. Morphometric measurements were recorded with use of digital Vernier caliper. Photographic documentations were recorded and the data was analyzed statistically wherever necessary. Studies of different authors

and data from different population was compared with present study.

Results

In all 62 dissected shoulders, STSL was found in the majority of cases as a fibrous band. In most cases its base was attached either to scapula on its superior border or to medial margin of SSN. Single STSL was present in 98.4% specimens [Fig. 1] whereas, 1.6% showed bifid STSL [Fig. 2]. The bifid STSL presented with two separate band as: anterior band and posterior band. These bands were placed one in front of the other. The bands were separately attached to coracoid process near its base while the medial attachment was common.

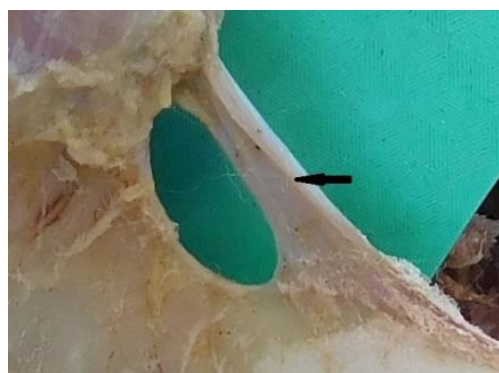

Fig. 1: Single STSL

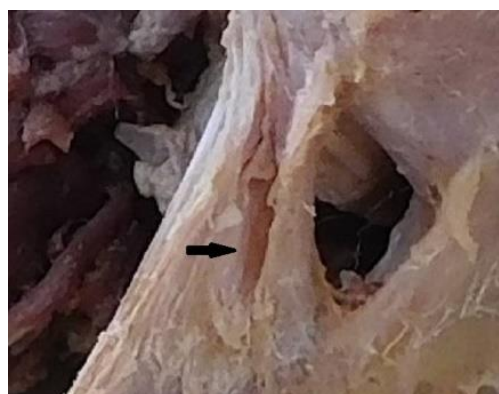

Fig. 2: Bifid STSL

The records of various STSL measurements on right and left side are mentioned in Table 1.

Table 1: Measurements of STSL

	Measurements of STSL on right side (mm)			Measurements of STSL on left side (mm)			Average
	Min	Max	Mean	Min	Max	Mean	
Superior length	7	42	20.13	12	35	20.58	20.35
Inferior Length	7	20	13.94	9	20	13.13	13.53
Thickness at lateral end	1	2	1.52	1	3	1.77	1.64
Thickness at medial end	1	2	1.16	1	3	1.32	1.24
Width at lateral end	2	8	3.61	2	7	3.53	3.57
Width at medial end	4	35	12.58	3	34	11.77	12.17

We classified the STSL based on the description by Polgaj et al⁴ as fan shaped STSL in 74.2% [Fig. 3], band shaped STSL in 24.2% [Fig. 4] and bifid STSL in 1.6% [Fig. 2] specimens. A narrow slit like suprascapular opening can be observed between and the medial border of the root of the coracoid process and the lateral edge of ligament. The following records of mean cross sectional area of suprascapular opening were noted: 32.89 mm² in the fan shaped specimens, 18.86 mm² area in band shaped specimens and 22mm² area in bifid STSL.

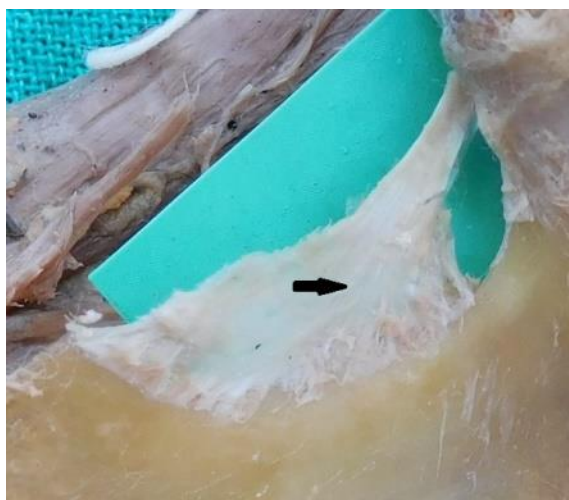


Fig. 3: Fan shaped STSL

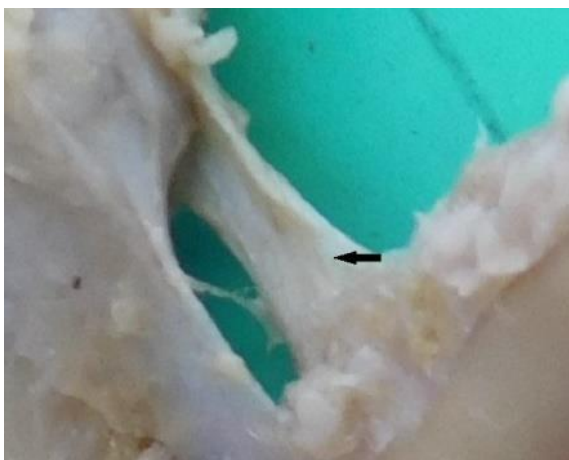


Fig. 4: Band shaped STSL

In present study the passage of suprascapular nerve was under the STSL in all the specimens. The suprascapular vessels passed either above or below the STSL. The anatomical relations of suprascapular vessels to STSL were recorded as: First type (29.03%) showed the presence of suprascapular vein below the STSL and the suprascapular artery above it. The second type (54.84%), revealed the placement of both suprascapular artery and vein were above the ligament. The third type showed the passage of all the structures i.e. nerve, vein and artery below the ligament (16.13%).

In present study complete ossification of STSL was noted in 1.61% specimen [Fig. 5] and partial ossification in 20.96% specimens [Fig. 6]. It was noted that in our study the percentage of fan shaped STSL getting ossified was more than in band shaped STSL. The mean distance between the base of SSN and the supraglenoid tubercle was 36.27mm and the mean distance between posterior rim of glenoid cavity and the base of scapular spine was 19.03mm.

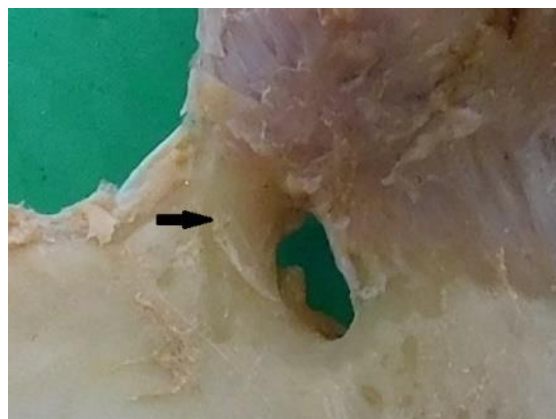


Fig. 5: Completely ossified STSL

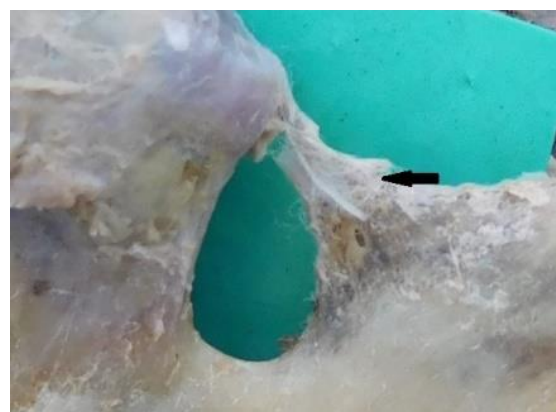

Fig. 6: Partially ossified STSL

Discussion

SNES is a neuropathy because of suprascapular nerve impingement. The compression is commonly observed at SSN. As described by Zehetgruber and El Sayed, clinically SNES is characterized by shoulder pain which is dull and aching in nature more so involving posterior part of shoulder. The severe cases may show atrophy of muscles namely infraspinatus and supraspinatus. The external rotation of arm and abduction of shoulder may become painful and difficult.^{2,7} Kopell and Thompson⁸ in 1959, reported that abduction or horizontal adduction of the shoulder stretches the nerve which lead to its compression and thus pain. Rengachary et al in his largely cited article has described the sling effect as main causative factor in compressing the nerve. He stated that the angulated nerve against the STSL is responsible for its compression. In addition many authors contributed in describing various

factors like ossified STSL,^{4,5,10-36} calcified STSL^{37,38} or bifid STSL⁵ resulting in SNES.

In our study single STSL was found in 98.4% and bifid STSL in 1.6% which correspond to the findings of other authors namely Polguy, Polguy and Aragao.^{4,5,39} During its passage through the SSN the suprascapular nerve is liable for compression because of variations in thickness and length of STSL. Simeone Joseph⁴⁰ reported the average length of STSL as 12.8 ± 1.5 mm. We found that our values of thickness and length of STSL are lower than in the study done by Aragao.³⁹

In the present study the fan shaped STSL (74.2%) was more common as compared to band shaped (24.2%) and bifid STSL (1.6%). Polguy et al⁴ reported fan shaped (54.6%), band shaped (41.9%) and bifid STSL (3.5%). We found the mean cross sectional area of suprascapular opening in case of single STSL was 29.44 mm² while in bifid STSL it was 22 mm². These findings correspond to the findings reported by Polguy et al⁵ (single STSL 31.32 mm² & bifid STSL 25.58mm²). Rekha B.S.²⁵ reported area of 64.49mm² as mean cross sectional area of suprascapular opening.. The cross sectional area varies depending on the shape of the STSL. We found in the specimens with fan shaped, band shaped and bifid STSL, the cross sectional areas were 32.89 mm², 18.86 mm² and 22 mm² respectively. These findings are not coinciding with the findings reported by Polguy et al.⁴ Podgorski⁴¹ reported area of suprascapular opening in fan shaped STSL as 38.56mm² and for band shaped STSL as 23.9mm². It may be appreciated that band shaped STSL overlying the suprascapular opening results in constrained space increasing the possibility of entrapment.

The suprascapular nerve passing below STSL through suprascapular opening was present in all specimens. The suprascapular vessels passed either above or below the STSL. The relation of suprascapular vessels and suprascapular nerve was reported by Polguy et al.⁴ as two types: the artery above the STSL, the vein and nerve below (First type), and both vessels above the STSL and the nerve below it (Second type). In our study, we found additional third type in which all 3 structures, the suprascapular nerve and suprascapular vessels ran below STSL. Podgorski⁴¹ reported this third type but he could not find the second type. (Table 2)

Table 2: Relations of suprascapular vessels and nerve to STSL

	Polguy et al ⁴ %	Podgorski ⁴¹	Present study %
Type I	72.1	96	29.03
Type II	27.9	0	54.84
Type III	0	4	16.13

As Apurba has described the space for passage of suprascapular nerve is reduced because of ossification of STSL leading to nerve irritation during shoulder movements resulting in possibility of SNES.¹⁰ A literature review reveals 1.5% to 19.44% incidence of complete ossification of the STSL.^{5,10-36,42-48} In our study, 1.61% specimen

showed complete ossification. Findings of Dunkelgrun¹¹ supports this opinion. He disagrees about the relation between ossification of STSL and aging. In contrast Kazuya⁴⁵ supports the possibility of correlation between ossification of STSL and aging.

The distance between SSN and supraglenoid tubercle is of immense importance during open surgical procedures requiring dissection of shoulder joint from posterior approach. The suprascapular nerve during surgery can be safely handled if operation is confined to the safe zone.³³. In our study the mean distance between the SSN and the supraglenoid tubercle and the mean distance between posterior rim of glenoid cavity and the base of scapular spine were higher as compare to the findings of other authors like Bage NN, SharmaR, Philip SE, Vandana R, Albino P and Shivaleela.^{21,26,28,33,46,49} (Table 3)

Table 3: Comparison between mean distance between the SSN and the supraglenoid tubercle and mean distance between posterior rim of glenoid cavity and the base of scapular spine

	Mean distance between the SSN and the supraglenoid tubercle (mm)	Mean distance between posterior rim of glenoid cavity and the base of scapular spine (mm)
Bage NN	24.79	13.07
Sharma R	29.98	-
Philip SE	28.10	16.37
Vandana R	27.3	13
Albino P.	31	-
Shivaleela C.	31.58	19
Present study	36.27	19.03

Conclusion

The incriminating factors in causation of SNES mainly include morphology of suprascapular notch and shape of STSL. The surgical relief aims at decompression of suprascapular nerve by excising the STSL. The SSN is a fixed bony structure which can not be altered, thus does not contribute in treatment of SNES. This fact underlines the importance of STSL which needs to be approached and excised carefully in decompression treatment of SNES. Cadaveric study of STSL providing idea of variations of morphology of STSL shall be of help to surgeons and arthroscopist to plan their approach in treatment of SNES.

Conflict of Interest: None.

References

1. Iqbal K, Iqbal R, Khan SG. Anatomical variations in shape of suprascapular notch of scapula. *J Morphol Sci* 2010;27:1-2.
2. Zehetgruber H, Noske H, Lang T, Wurnig C. Suprascapular nerve entrapment, A meta-analysis International Orthopedics (SICOT) 2002;26:339-43.
3. Pecina M. Who really first described and explained the suprascapular nerve entrapment syndrome. *J Bone Joint Surg Am* 2001;83-A(8):1273-4.
4. Polguy M, Jedrezwski K, Podgorski M, Majos A, Topol M. A proposal for classification of the superior transverse scapular

- ligament: variable morphology and its potential influence on suprascapular nerve entrapment. *J Shoulder Elbow Surg* 2013;22:1265-73.
5. Polguy M, Jędrzejewski K, Majos A, Topol M. Variations in bifid superior transverse scapular ligament as a possible factor of suprascapular entrapment: an anatomical study. *Int Orthop* 2012;36:2095-100.
 6. Mitchell J. The incidence and dimensions of the retroarticular canal of the atlas vertebra. *Acta Anatomica* 1988a;163:113-120.
 7. El Sayed AMM, Rasha ME, Bahaa AM. Suprascapular Nerve: Anatomical and Clinical Study. *Int J Clin Exp Med Sci* 2016;2(3):31-9.
 8. Thompson WAL, Kopell HP. Peripheral entrapment neuropathies of the upper extremity. *New Engl J Med* 1959;260:1261-5.
 9. Rengachary SS, Burr D, Lucas S, Hassanein KM, Mohn MP, Matzke H. Suprascapular entrapment neuropathy: a clinical, anatomical, and comparative study. II: anatomical study. *Neurosurg* 1979;5(4):447-51.
 10. Apurba P, Singh M, Kaur H. Variations in the Shape and Dimension of the Suprascapular Notch in Dried Human Scapula-An Osteological Study with its Clinical Implications. *Int J Anat, Radiol Surg* 2016;5(2):1-5.
 11. Dunkelgrun M, Iesaka K, Park SS, Kummer FJ, Zuckerman JD. Interobserver reliability and intra observer reproducibility in suprascapular notch typing, *Bulletin: Hosp Jt Dis* 2003;61(3-4):118-22.
 12. Akhtar MJ, Madhukar PK, Fatima N, Kumar A, Kumar B, Sinha RR, Kumar V. Ossification of Transverse Scapular Ligament in North Indian Population. *J Evol Med Dent Sci* 2014;3(63):13884-92.
 13. Joshi SS, Joshi SD, Pandey R, Makhani JS. Note on the anatomy of the suprascapular notch and ligament in central Indians. *Anatomical Adjunct* 1990;1(9):37-46.
 14. Thounaojam K, Karam R, Singh NS. Ossification of transverse scapular ligament. *J Evol Med Dent Sci* 2013;2(12).
 15. Gopal K, Choudhary AK, Agarwal J, Kumar V. Variations in suprascapular notch morphology and its clinical importance. *Int J Res Med Sci* 2015;3:301-6
 16. Sutaria LK, Nayak TV, Patel SV, Jadav HR, Pensi CA. Morphology and morphometric analysis of suprascapular notch. *IJBAR* 2013;04(01).
 17. Polguy M, Sibinski M, Grzegorzewski A, Waszczykowski M, Majos A, Topol M. Morphological and radiological study of ossified superior transverse scapular ligament as potential risk factor of suprascapular nerve entrapment., *BioMed Res Int* 2014;2014 Article ID 613601, 7 pages <http://dx.doi.org/10.1155/2014/613601>
 18. Basha MA, Sugavasi R. Prevalence of ossified superior transverse scapular ligament in south Indian population-research article. *Int J Health Sci Res* 2015;5(8):534-6.
 19. Nagaraj S, Krishnaiah M, Praveen Kumar M, Sherke AR. Study of Morphological Variations of Suprascapular Notch. *IOSR J Dent Med Sci* 2014;13(6):121-3.
 20. Natsis K, Totlis T, Tsikaras P, Appell HJ, Skandalakis P, Koebeke J. Proposal for classification of the suprascapular notch: a study on 423 dried scapulas. *Clin Anat* 2007;20:135-9.
 21. Bage NN, Sriambika K, Murugan M, Nim VK. Morphometric study of suprascapular notch as a factor of suprascapular nerve entrapment and dimensions of safe zone to prevent suprascapular nerve injury. *Int J Anat Res* 2017;5(2.3):4015-9.
 22. Mistry P, Chauhan K., Mehta C, Patil D, Bansal M, Suthar K. A [28] study of incidence of ossification of superior transverse scapular ligament of scapula and its clinical implications. *Int J Basic & Appl Med Sci* 2013;3:41-5.
 23. Raj Kishore Mahato, Parineeta Suman. "Complete Absence of the Suprascapular Notch: A Risk Factor for Suprascapular Nerve Entrapment Neuropathy. *J Evol Med Dent Sci* 2013;2(25):4542-5.
 24. Desai RR, Ambali MP, Doshi MA Incidence of ossification of superior transverse scapular ligament of scapula in Indian population. *Int J Curr Microbiol App Sci* 2014;3(9):1081-4.
 25. Rekha BS, Divya Shanthi D'sa. Study of Complete ossification of the superior transverse scapular ligament in Human dry Scapulae. *Indian J Clin Anat Physiol* 2016;3(2):108-12.
 26. Sharma R, Sharma R, Singla R, Kullar JS, Sharma T. Suprascapular notch: a morphometric and morphologic study in north Indian population. *Int J Anat Res* 2015;3(3):1306-11. DOI: 10.16965/ijar.2015.217
 27. Saikia R, Baishya RJ, Deka B. Variations in the Shape of the Suprascapular Notch in Dry Human Scapula: An Anatomical Study. *Int J Sci Stud* 2017;5(1):187-90.
 28. Philip SE, Dakshayani K.R. A morphometric study of suprascapular notch and its safe zone. *Int J Anat Res* 2017;5(2.1):3766-70. DOI: 10.16965/ijar.2017.172
 29. Jangde S, Arya RS, Paikra S, Basan K. Bony suprascapular foramen, a potential site for suprascapular nerve entrapment: a morphological study on dried human scapulae. *Int J Anat Res* 2015;3(3):1316-20. DOI: 10.16965/ijar.2015.232
 30. Stylianos K, Nikolaos G, Alikei F. Formation of suprascapular foramen as a result of ossification of superior transverse scapular ligament: a case report and short review of the literature; *IJAE (Italian J Anat Embryol)* 2016;121(2):205-10.
 31. Shanmugam S, Puthuraj M, Jayamrugavel G, Thiagarajan S. A study on the morphological variations of the suprascapular notch in the population of eastern delta region of Tamilnadu. *Int J Anat Res* 2017;5(1):3430-4.
 32. Kannan U, Kannan NS, Anbalagan J, Rao S. Study of suprascapular notch in Indian dry scapulae with specific reference to the incidence of completely ossified superior transverse scapular ligament. *J Clin Diagn Res* 2014;8:7-10.
 33. Vandana R, Patil S. Morphometric study of suprascapular notch. *NJCA* 2013;2(3):140-4.
 34. Vasudha TK, Shetty A, Gowd S, Rajasekhar SS. Morphological [17] study on suprascapular notch and superior transverse scapular ligaments in human scapulae. *Int J Med Res Health Sci* 2013;2(4):793-8.
 35. Zahid A, Khan MW, Khan B. Ossified superior transverse scapular ligament: a morphological study on dried Pakistani scapulae. *Biomedica* 2014;30(3):1-4.
 36. Zuberi HR, Azhar AS. Study of suprascapular notch of scapula and its clinical relevance *Med Pulse. Int Med J* 2015;2(10):721-4.
 37. Cohen SB, Dines DM, Moorman CT. Familial calcification of the superior transverse scapular ligament causing neuropathy. *Clin Orthops Relat Res* 1997;334:131-5.
 38. Bayramoglu A, Demiryürek D, Tüccar E, Erbil M, Aldur MM, Tetik et al. Variations in anatomy at the suprascapular notch possibly causing suprascapular nerve entrapment: An anatomical study. *Knee Surg Sports Trauma Arthrosc* 2003;11:393-98.
 39. Aragão JA, Teles LNS, Bárbarade A, Chaves J, Prado JCO, Pereira PS, Dantas JBL, Reis FP. The Superior Transverse Scapular Ligament in Fetuses. *Anat Res Int* 2013, Article ID 323194, <http://dx.doi.org/10.1155/2013/323194>
 40. Simeone F.J., Bredella M.A., Chang C.Y. *Skeletal Radiol* 2015;44:1663. doi:10.1007/s00256-015-2209-2
 41. Podgórski M, Topol M, Sibiński M, Grzelak P, Stefańczyk L, Polguy M. New parameters describing Morphological variations in the suprascapular notch region as potential predictors of suprascapular nerve entrapment. *BMC Musculoskeletal Disord* 2014;15:396.
 42. Hassanein GHES, Ali MB. Variations of suprascapular notch in adult Egyptian scapulae. *Int J Anat Res* 2015;3(4):1536-42.

43. Soni G, Malik VS, Boddeti RK. Morphometric analysis of suprascapular notch: review of literature. *Int J Anat Res* 2015;3(4):1624-8.
44. Patil GV, Shishirkumar, Apoorva D, Thejeswari, Sushanth N.K. Study of Morphological Variations of Suprascapular Notch in Human Dry Scapulae of South Indians. *Int J Sci Res Publications*, 2014;4(9):1-4.
45. Kazuya Inoue Suprascapular notch variations: a 3DCT study. *J Orthop Sci* 2014;19(6):920-4.
46. Albino P, Carbone S, Candela V, Arceri V, Vestri AR, Gumina S, Morphometry of the suprascapular notch: correlation with scapular dimensions and clinical relevance. *BMC Musculoskeletal Disord* 2013;14:172.
47. Mohan SS, Sudhakar SK. The Importance of Suprascapular Notch and Foramen in Identification. *Indian J Forensic Med Toxicol* 2017;11(1):111-4.
48. Tubbs RS, Smyth MD, Salter G, Oakes WJ. Anomalous traversal of the suprascapular artery through the suprascapular notch: a possible mechanism for undiagnosed shoulder pain? *Med Sci Monit* 2000;9:116-19.
49. Shivaleela C, Archana BJ, Kumar GV, Swetha R, Lakshmi Prabha S. Morphometric analysis of suprascapular notch in human adult scapulae with clinical relevance. *RJPBCS* 2014;5(6):741-7.

How to cite this article: Usha Dandekar, Kundankumar Dandekar. Cadaveric morphological study of superior transverse scapular ligament and its clinical correlation. *Indian J Clin Anat Physiol* 2019;6(2):173-8.