

Anomalous development of thyroid gland; a cadaveric study in coastal population of Andhra Pradesh

T. Sravani¹, P. Sofia^{2*}, C. K Lakshmi Devi³

^{1,2}Assistant Professor, ³Professor, Dept. of Anatomy, ^{1,2}Government Medical College, Kadapa, Andhra Pradesh, ³ACSR Government Medical College, Nellore, Andhra Pradesh, India

***Corresponding Author: P. Sofia**

Email: sofiapeddity@gmail.com

Received: 6th December, 2018

Accepted: 10th February, 2019

Abstract

Introduction: Thyroid gland is a butterfly shaped richly vascular, brownish-red endocrine organ, located at the lower part of the neck opposite to the fifth, sixth and seventh cervical and the first thoracic vertebrae. On account of developmental abnormalities thyroid gland shows various morphological anomalies like absence of isthmus, ectopic position, and absence of any one of the lateral lobes.

Aims: The present study is aimed at documentation of morphological abnormalities and their incidences of thyroid gland, which is useful for the surgeons to plan for proper surgical procedures in thyroid disease.

Materials and Methods: The present study was conducted in 50 cadavers (39 male & 11 female) in coastal region of Andhra Pradesh.

Results: There is variable lobular pattern in 21 (42%) cadavers. Out of these, isthmus was absent in 8 (20.5%) male, and 3 (27.3%) female cadavers. Relation of tracheal rings to the isthmus was noted. Pyramidal lobe was present in 17 (43.5%) male and 2 female (18.1%) cadavers. Pyramidal lobe is frequently arising from the Isthmus. Levator glandulae thyroideae (LGT) was present in 16 (41%) male and 2 (18.1%) female cadavers. The average height and thickness of right lobe is 4.3cm and 1.15 cm and left lobe is 4.2cm and 1.15cm.

Conclusion: As developmental abnormalities of the thyroid gland are common, it is essential to know their variations and incidences for successful thyroid surgeries.

Keywords: Thyroid gland, Pyramidal lobe, Isthmus, Levator glandulae thyroideae.

Introduction

Thyroid gland is considered as one of the most important endocrine gland, because its secretions will help in the growth differentiation, organisation, and maturation of the cells in the body. Thyroid gland consists of right and left lobes connected by a narrow median isthmus. Pyramidal lobe (PL) is a conical part of the gland which ascends towards the hyoid bone from either of the lateral lobes or isthmus. A fibrous or muscular band, Levator Glandulae thyroideae (LGT) above attached to the body of the hyoid bone many times or to the thyroid cartilage from the pyramidal lobe or isthmus of the thyroid gland. Thyroid gland develops mainly from the thyroglossal duct which starts as a diverticulum, immediately behind the tuberculum impar. The diverticulum grows down into the neck and bifurcates to form the two lateral lobes of the thyroid gland. Developing thyroid gland comes in contact with the caudal pharyngeal complex, from which parafollicular cells develop.¹ Developmental anomalies cause various morphological abnormalities in thyroid gland. Thyroid diseases are well documented and require medical and surgical interventions. Clinicians should know about these variations prior to surgical procedures to plan for proper surgeries for better outcome. Therefore knowledge of the various congenital anomalies and their incidences is of utmost importance to the clinicians.²

Materials and Methods

The present work was done on 50 well embalmed cadavers in the department of Anatomy, Narayana Medical College, Nellore over a period of 3 years, with ages ranging from 40

to 75 years. All the cadavers were labelled from 1 to 50 with suffix "M" for males and "F" for females. Among those 50 cadavers, 39 were males and 11 were females. Any abnormal swellings noted in the thyroid region were excluded for the study. Institutional ethical committee approval was obtained.

Regular dissection technique was followed to observe the thyroid gland. A vertical midline incision was given from symphysis menti to the jugular notch. Skin and platysma were reflected laterally, deep fascia was removed to expose the infrahyoid muscles. Strap muscles of the neck were reflected laterally, remaining deep fascia and fat surrounding the gland was removed. The thyroid gland was observed for 1. Presence or absence of isthmus and its relation to tracheal rings, 2. Presence of pyramidal lobe and levator glandulae thyroideae, and 3. Height and thickness of lateral lobes.

Results

A total of 50 cadavers were observed for thyroid gland anatomy, variations were observed in 21 (42%) cadavers, and remaining 29 (48%) cadavers were normal. In 11 cadavers isthmus was absent, among these, 8 (20.5%) were male and 3 (27.3%) were female (Fig. 1). Posterior relations of the isthmus was observed in 39 cadavers, Isthmus was posteriorly related to 1st and 2nd tracheal rings in 4 cadavers, first three tracheal rings in 10 cadavers, 2nd, 3rd and 4th tracheal rings in 15 cadavers, 2nd and 3rd tracheal rings in 5 cadavers and 3rd and 4th tracheal rings in 5 cadavers (Table 1). Mean height of the isthmus was 1.3 cm.

Pyramidal lobe was found in 19 (38%) cadavers, among these 17 (43.5%) were male and 2 (18%) were females. There is a case with two pyramidal lobes attached to single levator glandulae thyroideae (Fig. 2). Pyramidal lobe of the thyroid gland was frequently arising from Isthmus in 9 cadavers followed by left lobe in 8 cadavers and right lobe in 2 cadavers (Fig. 3-5). Levator glandulae thyroidea was present in 18 (36%) cases. It was extending from the apex of the pyramidal lobe to the hyoid bone and thyroid cartilage (Table 2). Extension of the superior limit of the thyroid gland lateral lobe in relation to the midpoint of the lamina of the thyroid cartilage and the inferior limit of the thyroid gland lateral lobe in relation to the tracheal ring in male and female cadavers on right and left sides is shown in table 3. The mean height and thickness of right lobe is 4.3 cm and 1.15 cm and left lobe is 4.2cm and 1.15cm (Table 4).

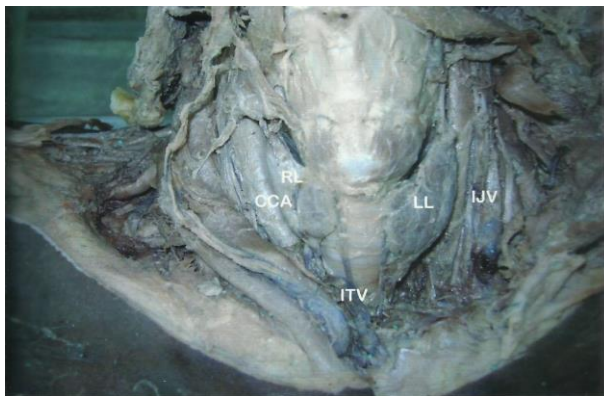


Fig. 1: Absence of isthmus
[CCA: Common carotid artery, ITV: Inferior thyroid vein, LL: Left lobe, RR: Right lobe, IJV: Internal jugular vein]

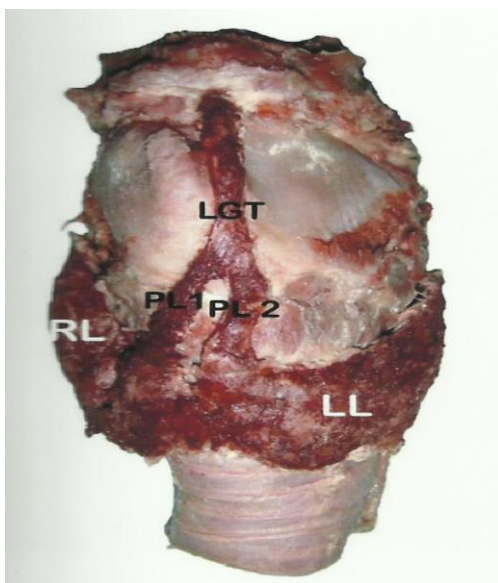


Fig. 2: Two pyramidal lobes attached to single Levator Glandulae thyroideae
[RL: Right lobe, LL: Left lobe, PL1: Pyramidal lobe 1, PL2: Pyramidal lobe 2, LGT: Levator Glandulae Thyroideae]

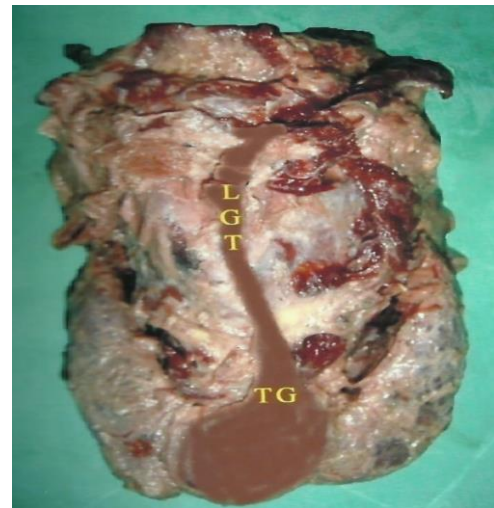


Fig. 3: Pyramidal lobe and levator glandulae thyroideae arising from isthmus
[LGT: Levator Glandulae Thyroideae, TG: Thyroid gland]




Fig. 4: Pyramidal lobe and Levator glandulae from right lobe of thyroid gland

[STA: Superior thyroid artery, IJV: Internal jugular vein, CCA: Common carotid artery, RL: Right lobe, PL: Pyramidal lobe, LGT: Levator glandulae thyroideae]

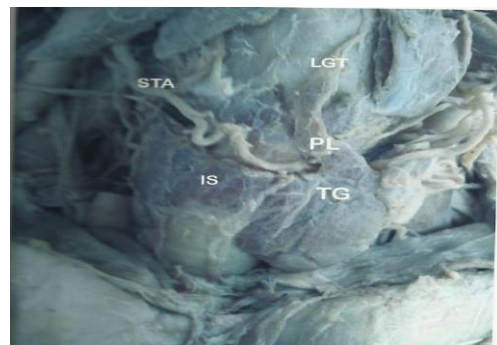


Fig. 5: Levator glandulae thyroideae and pyramidal lobe from left lobe of thyroid
[STA: Superior thyroid artery, IS: Isthmus, TG: Thyroid gland, PL: pyramidal lobe]

Table 1: Posterior relation of isthmus to tracheal rings

Related structure	Frequency	Percentage
1 st and 2 nd rings	4	10%
1 st , 2 nd and 3 rd rings	10	25.6%
2 nd , 3 rd and 4 th rings	15	38.5%
2 nd and 3 rd rings	5	12.8%
3 rd and 4 th rings	5	12.8%
Present in total	39	78%

Table 2: The gross anatomical features of the thyroid gland.

	Male cadavers			Female cadavers		
	Right	Left	Isthmus	Right	Left	Isthmus
Pyramidal lobe	2	7	8	0	1	1
LGT	2	7	7	0	1	1

Table 3: Extension and position of the thyroid gland lateral lobes

	Superior limit in relation to the midpoint of the lamina of the thyroid cartilage						inferior limit in relation to the tracheal ring			
	Right lobe			Left lobe			Right lobe		Left lobe	
	at	below	Above	At	below	Above	5 th	6 th	5 th	6 th
Male (39)	15 (38.5%)	19 (48.7%)	5 (12.8%)	13 (33.3%)	20 (51.2%)	6 (15.4%)	16 (41%)	23 (59%)	19 (48.7%)	20 (51.3%)
Female (11)	6 (54.5%)	4 (36.4%)	1 (9.1%)	6 (54.5%)	3 (27.3%)	2 (18.2%)	4 (36.4%)	7 (63.6%)	5 (45.5%)	6 (54.5%)

Table 4: Mean height and thickness of the thyroid gland lobes

	Height (+/- SD)	Thickness(+/-SD)
Right lobe	4.3+/-0.79	1.15+/-0.45
Left lobe	4.2+/-0.72	1.15+/-0.32

Discussion

The present study was done to document the morphological abnormalities of the thyroid gland like Presence or absence of isthmus and its relation to tracheal rings, Presence of pyramidal lobe and levator glandulae thyroideae, and Height and thickness of lateral lobes in 50 cadavers. Literature suggests that isthmus connecting two lobes appear during course of evolution and may be no isthmus in 5% to 25% of the mammals. Isthmus was found to be absent in 22% (11) of cases in the present study. This is in accordance with study done by Rajkonwar et al,¹ their study showed absence of isthmus in 21.25% of cases. Harjeet et al,² Marshall. C.F.,³ Sharma A et al,⁴ Oya SA,⁵ and Vinaya Kumar MV et al⁶ observed separation of lobes in less than 10% of the cases. Most of the anatomical text described the isthmus being related to 2nd and 3rd tracheal rings, our study be evidence with only 5 cases. 4 cases were posteriorly related to 1st and 2nd tracheal rings, 10 cases related to the first three tracheal rings, 15 cases related to 2nd, 3rd and 4th tracheal rings, and 5 cases related to 3rd and 4th tracheal rings. This is in accordance with S D Joshi et al.⁷ His study shows that 19 cases related to 2nd and 3rd tracheal rings, 14 cases to first two tracheal rings and 12 cases to 1st, 2nd and 3rd tracheal rings.

In present study, Pyramidal lobe was seen in 38% of the cases, and about half of them were attached to the isthmus (47%), followed by left lobe (41.2%), and right lobe

(11.8%). These observations were almost in accordance with the previous studies done by Harjeet et al.,² Marshall et al,³ S D Joshi et al,⁷ Siraj et al.⁸ Veerahanumaiah S et al⁹ and they also found a greater incidence among females. The presence of two pyramidal lobes attached by a single levator glandulae thyroideae has been described by Harjeet et al,² Marshall C F,³ Oya S A,⁵ and Joshi S D.⁷ In presence study, only one case was observed with similar presentation. It is because of the growing thyroglossal duct divide at its apex, and each branch present with a lobe to the gland.¹⁰

levator glandulae thyroideae was seen in 18 (36%) cadavers. In 10 (55.6%) cadavers it was attached to the hyoid bone, in 4 (22.2%) cadavers it was attached to upper border of thyroid cartilage, and in 4 (22.2%) cadavers it was attached to lower border of thyroid cartilage. This is in accordance with the studies done by S D Joshi et al,⁷ and Viswanath N,¹¹ they found levator glandulae thyroideae in 27 (30%) cases, among these 18 (66.66%) were attached to hyoid bone, 4 (14.81%) to the upper border of thyroid cartilage, and 5 (18.51%) to the lower border of the thyroid cartilage. Marshall CF³ found levator glandulae thyroideae was merged with the fascia covering the thyroid cartilage in some of the cases. Faysal et al¹² documented a case with unusual extension of levator glandulae thyroideae from the apex of the mastoid process. No such variations were observed in the present study.

A number of variations in the shape and size of the gland were observed in thyroid studies. The mean length of the lateral lobes is described as 5 cm in the most of the Anatomical texts.¹³⁻¹⁵ Harjeet et al.² described that right lateral lobe was 4.04 cm in length and left lateral lobe 3.82 cm in length among Northwest Indians. In a study done by S D Joshi et al.,⁷ the average length of the right lobe was 4.32 cm and the left lobe was 4.22 cm. The left lobe was smaller than the right lobe. In present study, the mean length of right lobe was 4.3 cm and left lobe was 4.2 cm. Indian physical features compared to western might account for short lateral lobes.

Conclusion

Morphology of the thyroid gland was studied in detail to found any anatomical variations and developmental anomalies among 50 cadavers in coastal Andhra Pradesh. In the present study, we observed 42% anatomical variations in thyroid gland. Absence of Isthmus (22%), prevailing posterior relation of the isthmus to first three tracheal rings (20%), presence of pyramidal lobe (38%), two pyramidal lobes attached to single levator glandulae thyroideae (2%), and short mean length of lateral lobe were distinguished. Knowledge of these anatomical variations are very essential for the surgeons to reduce or avoid iatrogenic injuries during thyroid surgery.

Conflict of Interest: None.

References

1. Rajkonwar AJ, Kusre G. Morphological Variations of the Thyroid Gland among the People of Upper Assam Region of Northeast India: A Cadaveric Study. *J Clin Diagn Res* 2016;10(12):AC01-AC03.
2. Harjeet A, Sahni D, Jit I, Aggarwal AK. Shape, measurement and weight of the thyroid gland in northwest Indians. *Surg Radiol Anat* 2004;26(2):91-5.
3. Marshall, C.F. Variations in form of the thyroid gland in man. *J Anat Physiol* 1895;29 (Pt-2):234-9.
4. Sharma A, Singh R, Kaur R. Morphometric and Morphological Study of Thyroid Gland – A Cadaveric Study. *Int J Sci Res* 2017;6(9):31-3.
5. Oya SA. Gross anatomical study on anomalies of the thyroid gland. *Gazi Medical J* 1997;8:33-8.
6. Vinaya Kumar MV, Mohammad R, Sreelatha S. Possible variations of thyroid gland: A detailed cadaveric study. *Int J Anat Surg Radiol* 2018;7(2):AO 09- AO13
7. Joshi SD, Joshi SS, Daimi SR, Athavale SA. The thyroid gland and its variations: A cadaveric study. *Folia Morphol* 2010;69(1):47-50.
8. Siraj QH, Aleem N, Inam-Ur-Rahman A, Qaisar S, Ahmed M. The pyramidal lobe: a scintigraphic assessment. *Nucl Med Commun* 1989;10:685-93.
9. Veerahanumaiah S, Dakshayani KR, Menasinkai SB. Morphological variations of the thyroid gland. *Int J Res Med Sci* 2015;3:53-7.
10. Sgalitzer KE Contribution to the study of the morphogenesis of the thyroid gland. *J Anat* 1941;75:389-405.
11. Viswanath N. Pyramidal lobe of thyroid gland – Significance in thyroid surgery. *Int J Appl Res* 2016;6(12):137-9.
12. Saadeh FA, Kawas SH, Haikal FA, Hawi JS. Unusual Levator glandulae thyroideae. *J Anat Soc India* 1996;45(2):125-8.

13. Standring S, Ellis H, Healy JC, Johnson D, Williams A, Collins P. Gray's anatomy: the anatomical basis of clinical practice. 39th Ed. Churchill Livingstone: Elsevier; 2005. pp. 543-7.
14. Wood J.F. Buchanan's manual of anatomy. 8th Ed. Billiere Tendall and Cox, London.1953.
15. Hollinshead W.H. Hollinshead's Text book of anatomy 4th Ed. Harper and Row publishers, Philadelphia.1985.

How to cite this article: Sravani T, Sofia P, Devi CKL. Anomalous development of thyroid gland; a cadaveric study in coastal population of Andhra Pradesh. *Indian J Clin Anat Physiol* 2019;6(2):220-3.