

## Varying shapes of lingula and its prevalence in dry adult human mandible

Fasila P Assis<sup>1\*</sup>, Aswathy Sheela Sudhakar<sup>2</sup>, Remya C<sup>3</sup>, Prakash K.G<sup>4</sup>

<sup>1</sup>Assistant Professor, <sup>2,3</sup>Senior Lecturer, <sup>4</sup>Professor and HOD, <sup>1,4</sup>Dept. of Anatomy, <sup>2</sup>Dept. of Periodontology, <sup>3</sup>Dept. of Conservative Dentistry and Endodontics, <sup>1,4</sup>Azeezia Institute of Medical Sciences and Research, Kollam, Kerala, <sup>2,3</sup>Azeezia College of Dental Sciences and Research, Kollam, Kerala, India

**\*Corresponding Author: Fasila P Assis**

Email: drfasilapassis@gmail.com

Received: 24<sup>th</sup> March, 2019

Accepted: 9<sup>th</sup> May, 2019

### Abstract

**Introduction:** Mandibular foramen which transmits inferior alveolar nerve is guarded anteriorly by a bony projection called lingula. Lingula directs oral and maxillofacial surgeons to locate inferior alveolar nerve to provide anaesthetic block during dental procedures. Lack of precise knowledge on varying shapes of lingula in different population might be a cause for surgical failures. This study intended to compare the shape of lingula obtained with the findings of previous authors from different Indian population, to provide a fair idea on ethnic and racial disparity of lingula.

**Materials and Methods:** Varying shapes of lingula observed in 50 (100 sides) dry adult human mandibles collected from department of Anatomy, AIMSRS, Kollam. Related the findings of lingula with the genders of mandible and correlated the findings with previous studies from different ethnic groups.

**Results:** The most frequent shape of the lingula was triangular (47%), followed by nodular (26%), truncated (18%), assimilated (7%) types and M shaped lingula observed in 0.2% of mandible. Majority of male mandible (56%) showed triangular variety of lingula and almost equal proportion (38%) and (30%) of female mandible showed triangular and nodular variety respectively.

**Conclusion:** Maxillo-facial surgeons blindly palpate lingula to give nerve block during several dental procedures. Lingula forms a bony landmark for mandibular ramus osteotomy. Hence a compiling knowledge on anatomical variants in different population would be of great help to dental surgeons to perform safer surgeries.

**Keywords:** Gender disparity, Inferior alveolar nerve, Lingula, Mandibular ramus osteotomy, Nerve block.

### Introduction

Lingula of mandible is considered to be the most reliable reference point for locating the inferior alveolar nerve in many dental procedures, which led to several studies about its morphology.<sup>1</sup> For about half of adult mandible, anterior wall of mandibular foramen is majorly contributed by lingula. Lower jaw and adjoining structures are supplied by inferior alveolar nerve, which conducts via mandibular foramen.<sup>2</sup> For any dental procedure, an effectual anaesthesia of inferior alveolar nerve is a must. Many common dental procedures like tooth extraction, root canal treatment, nerve ablation for facial neuralgia and mandibular ramus osteotomy procedures like sagittal and vertical split ramus osteotomy carried out to correct dental facial deformities, requires anaesthetising inferior alveolar nerve.<sup>2,3</sup> Lingula has been reported by many authors to have sexual and racial disparity.<sup>3</sup> Though standard books have mentioned about varying shape of lingula, its classification in to triangular, nodular, truncated and assimilated according to its appearance was first described by Tuli et al.<sup>4</sup> Morphometric values of lingula will be of paramount importance to the anthropological and forensic experts for differentiating sexual dimorphism of mandible.<sup>5,13</sup> The sphenomandibular ligament is merely a point of attachment to this vestigial structure and is not responsible for altering the shape of lingula.<sup>6,7</sup> Lingula not only helps to guide the inferioralveolar nerve, it also acts as a bony landmark while doing osteotomy procedures, where cut should be made exactly above to the tip of lingula.<sup>8</sup> In an average 10-15% of

surgical attempts go for a failure mainly due to anatomical variations of lingula.<sup>9-11</sup> Failure to correctly assess the lingula might result in either inappropriate anaesthesia to the site of surgery or will lead to temporary or permanent nerve damage.<sup>12</sup> The main aim of this study was to analyse varying shapes, and relating it with the gender of the obtained mandible and also to compare the findings with previous authors in order to have a fair idea on ethnic and racial disparity of lingula among Indian population.

### Materials and Methods

An institutional based study on 50 adult dry human mandibles (100 sides) was performed. Mandibles were obtained from the Department of Anatomy, Azeezia Institute of Medical Sciences and Research, Kollam. Permission from ethical committee of the institution was obtained. Damaged mandibles and mandibles of extreme ages were excluded from the study. Shapes of lingula were classified into triangular type i.e. apex pointed with broad base, nodular i.e. lingula incorporate within the ramus of mandible except apex., truncated i.e. lingula having flat projection with blunt apex and assimilated were entire lingula incorporated with the ramus of mandible.<sup>4</sup> (Fig. 1-5). These findings were correlated with the genders of the mandible by observing gonial flare.<sup>15</sup> (Table 1) To avoid error, the shapes of lingula was recorded separately at different occasions by different observers. Observed shape of lingula was compared with the findings of previous studies from different Indian population (Table 2).

## Result

In present study 47% of lingula showed triangular variety (Fig. 1). Out of which, 23 were bilateral and 5 were unilateral in 56% of male mandible and in 38% of female mandible, 15 numbers were bilateral and 4 were unilateral. Total of 26% lingula had nodular variety (Fig. 2), out of which 22% of male mandible, 5 was bilateral and 6 being unilateral and 30% of female mandible, 7 was bilateral and 8 being unilateral. Total of 18% lingula was observed to be truncated variety (Fig. 3), out of which 6 was bilateral and 2 being unilateral in male mandible and in female mandible, 7 mandible showed truncated variety bilaterally and unilateral in total was seen in 3 sides. Assimilated variety (Fig. 4) was only observed in 7%, out of which male mandible only 1 was bilateral and 2 being unilateral and in female mandible 1 each for both bilateral and unilateral respectively. A special variety with two apices as M shaped (Fig. 5) was observed unilaterally in a male and a female mandible (Table 1).

## Discussion

In a study by Khan et al on 200 dry human mandibles, have mentioned that triangular shape lingula were more prevalent in males (59.25%). The least prevalent in male mandibles was nodular (4.5%). The truncated type is almost twice as common in male (6%) than female mandibles (3.5%). Female mandible showed 20.25% of triangular and 3.5% as truncated variety. He also concluded that male sex feature of a lingula is to be triangular type and female mandible showed 0% of assimilated variety in his study.<sup>1</sup> In present study, female mandible showed 38% and 30% prevalence of triangular and nodular variety. Assimilated was observed in 0.6% of male and 0.8% of female mandible respectively. In a study done by Sophia et al. has mentioned that 49% of procured mandibles had shown triangular variety, nodular in 23%, truncated in 18% and least been assimilated which was present only in 10% of mandibles.<sup>2</sup> Nirmal et al. has clearly mentioned about male mandible showing prevalence of triangular variety (36%) and equal proportion of assimilated and truncated variety of 8.92%. Female mandible in his study showed equal prevalence of triangular and nodular variety of 11.3 and 10.7% respectively.<sup>3</sup> Contrary to this; female mandible was observed to have almost equal proportion of triangular (38%) and nodular variety (30%) in present study respectively. Tuli et al. has observed triangular type (67.9% and 5%) was the most common in both male and female mandibles and assimilated (70.6% and 4.4%) being the least common in both the genders respectively. It was also observed that the truncated type was twice seen in males (17.6%) than in females (8.8%), and the nodular type was double in females (16.2%) as compared with male mandibles (9.6%).<sup>4</sup> In the present study, truncated variety of lingula was four times more observed in male mandible when compared to female mandible. Also a special variety of lingula with two apices (M shaped) was observed unilaterally in a male and a female mandible, accounting for 0.2% (Fig. 5). M shaped lingula was also reported by Varma C.L and Shameer P.A in

8 specimens out of 193 i.e. 4%.<sup>6</sup> In a study done in north Gujarat population, the author mentions a different finding of truncated being the most prevalent i.e. 42.22%, nodular and assimilated being in equal proportion of 21.67% and 20.56% respectively. Assimilated variety was observed in 15.55%.<sup>7</sup> The same records of truncated type of lingula being most prevalent was also observed by Padmavathy et al. where she found truncated variety in 33.84%, triangular in 29.23%, nodular type in 19.23%, assimilated variety in 17.69%.<sup>8</sup> Smrithy et al. done a study among north Indian population and discovered that triangular type (50%) was most prevalent, followed by truncated (33.82%), nodular variety (11.76%) and assimilated (2.9%) type. All types were more observed bilaterally.<sup>9</sup> Devi et al. has concluded that nodular and truncated are found bilaterally among Indian population.<sup>10</sup> In a study conducted by Shenoy et al. they have mentioned nodular variety was observed in 39% being the most common type, truncated in 29%, triangular type in 23% and assimilated in 9% as least common.<sup>11</sup> Hence, it's evident that shapes of lingula do differ from population to population showing racial disparity. (Table 2) A study conducted by Samanta et al. has found triangular (61.6%) to be the most common and assimilated (11.6%) being the least common type of lingula.<sup>12</sup> This finding was similar to the observation of the present study, where triangular was seen in 49% and assimilated in 7% only. But every type of lingula was observed more bilaterally in present study, when compared to the study performed by Samanta et al. who has mentioned that every type of lingula was more observed unilaterally.<sup>12</sup> Morphological features of lingula, along with other metric and non-metric features of mandible are sufficient to determine the sex of the given bone. Knowledge of different types of lingula and its prevalence in each gender can be of great importance in forensic and related fields.<sup>13</sup> Unlike other studies, Alvis N et al. have mentioned about the position of lingula based on its shape. He has mentioned triangular variety located posterior when compared to nodular variety which was more anterior in reference to the width of mandibular ramus. He has also concluded that, sex disparity in the shape of lingula is more remarkable when compared to the race dimorphism.<sup>14</sup>

Future scope of the study is to analyse the varying shape and prevalence of lingula in live patient by radiological methods using cone beam computerised tomography and orthopantomogram.

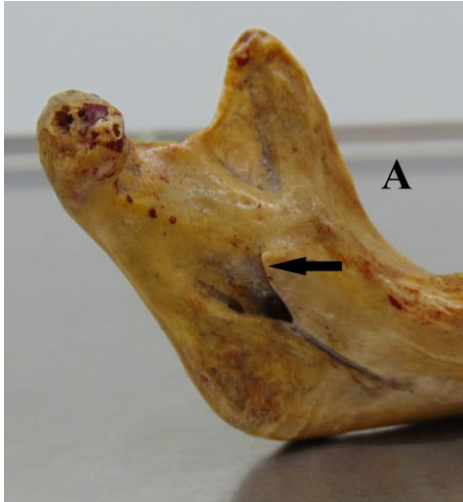


Fig. 1: Triangular type

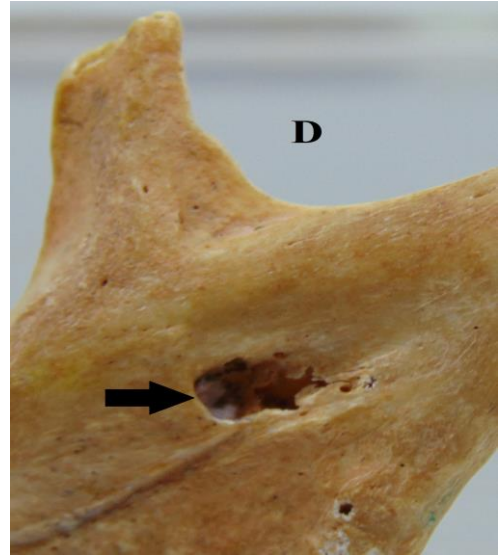


Fig. 4: Assimilated type

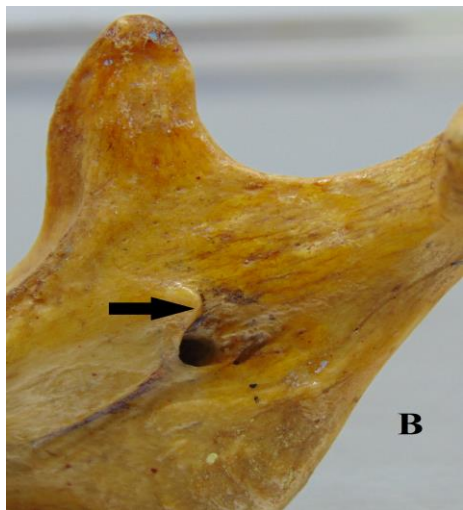


Fig. 2: Nodular type

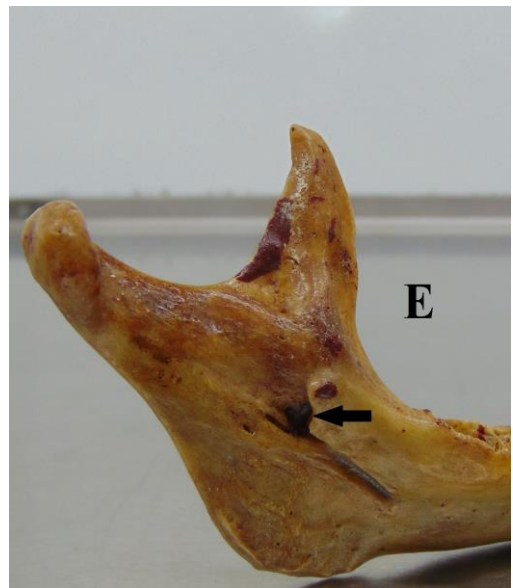


Fig. 5: M shaped type

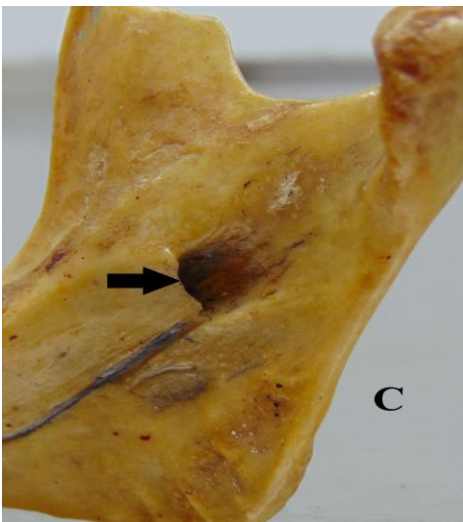


Fig. 3: Truncated type

**Table 1:** Variation in shape of lingula in male (M) and female (F) mandibles

S. No.	Shapes	Sex	Bilateral	Unilateral		% in Male & Female mandible	Total %
				Right	Left		
1	Triangular	M	23	2	3	56.0	47
	Triangular	F	15	3	1	38.0	
2	Nodular	M	5	2	4	22.0	26
	Nodular	F	7	5	3	30.0	
3	Truncated	M	6	1	1	16.0	18
	Truncated	F	7	2	1	2.0	
4	Assimilated	M	1	2	-	0.6	7
	Assimilated	F	1	1	2	0.8	
5	M Shaped	M	-	1	-	0.2	2
	M Shaped	F	-	-	1	0.2	
Total							100

**Table 2:** Comparing the findings on shape of lingula from different study population

Author	Study population	No of specimens	Triangular (%)	Nodular (%)	Truncated (%)	Assimilated (%)
Thanveer et al <sup>1</sup>	South India	200	69	9.2	5.5	8.9
Sophia MM et al <sup>2</sup>	South India	50	49	23	18	10
Nirmale et al <sup>3</sup>	North India	84	47.6	27.9	13.6	10.7
Tuli et al <sup>4</sup>	North India	165	68.5	10.9	15.8	4.8
Kayalvili Sanmugam <sup>5</sup>	South India	100	48	26	19	7
Varma et al <sup>6</sup>	South India	193	13	42	29	6
Umesh P Modasiya <sup>7</sup>	North India	90	42.2	15.5	21.6	20.5
Samantha et al <sup>14</sup>		124	61.6	31.6	46.6	11.6
Padmavathi et al. <sup>10</sup>	South India	65	29.2	19.2	33.8	17.7
Smrity et al. <sup>16</sup>	North India	50	42	10	36	12
Present study	South India	50	47	26	18	7

**Conclusion**

The present study contributes to literature regarding the shape and location of the lingula. Triangular type of lingula being the most prominent feature of male mandible (56%). Female mandible showed prevalence of both triangular (38%) and nodular (30%) variety. Assimilated (7%) type being the least common found in both male and female mandibles. A special variety of M shaped lingula was observed only in 0.2% of specimen. Every type of lingula was more observed to be a bilateral feature. Maximum attempt has been put to compare present study findings with that of previous authors of various populations to determine gender disparity.

**Acknowledgment**

We would like to thank the Head of Institution for permitting us to conduct this study. Also we would like to

thank HOD of Anatomy Department for granting us the permission to use Department resources like dry human mandibles and digital vernier caliper for the study.

**Conflict of Interests:** None.

**References**

1. Tanveer Ahamed Khan H.S, Sharieff. J.H. Observation on morphological features of human mandibles in 200 south Indian subjects. *Anatomica Karnataka* 2011;5,(1):44-8.
2. Sophia MM, Alagesan A, Ramachandran K.A. Morphometric and Morphological study of mandibular lingula and its clinical significance. *Int J Med Res Rev* 2015;3(2):141-8.
3. V.K. Nirmale, U. W. Mane, S.B. Sukre, C.V. Diwan. Morphological Features of Human Mandible. *Int J Recent Trends Sci Technol* 2012;3(2):38-43.
4. Tuli A, Choudhry R, Choudhry S, Raheja S, Agarwal S. Variation in shape of the lingula in the adult human mandible. *J Anat* 2000;197(2):313-317.
5. Kayalvili Sanmugam. A Study of Morphological Variation of Lingula and Coronoid Process of Adult Human Dry Mandibles. *J Pharm Sci Res* 2015;7(11):1017-20.
6. Varma CL, Sameer PA. Morphological variants of lingula in south Indian Mandibles. *RRJHMS* 2013;2(1):31-4.
7. Umesh P Modasiya 1, Sanjaykumar D Kanani. Study of lingula in dry human mandibles and its clinical significance. *Int J Anat Res* 2018;6(2.2):2321-4287.
8. Padmavathi G, Varalakshmi KJ, Suman T, Roopashree K. A Morphological and morphometric study of the lingula in dry adult human mandibles of South Indian origin and its clinical significance. *Int J Health Sci Res* 2014;4(6):56-6.
9. Smrity G, Krishna P. Morphological analysis of the lingula in dry mandibles of individuals in North India. *J Dent Med Sci* 2014;13(1):46.

10. Devi R, Aruna N, Manjunath KY and Balasubramanyam M. Incidence of morphological variants of mandibular lingula. *Indian J Dent Res* 2003;14:210-13.
11. Varsha Shenoy, S Vijaylakshmi, P Saraswathi. Osteometric Analysis of the Mandibular Foramen in Dry Human Mandibles. *J Clin Diagn Res* 2012;6(4):557-60.
12. Samanta PP, Kharab P. Morphological Analysis of Lingula in Dry Adult Human Mandibles of North Indian Population. *J Cranio Max Dis* 2012;1:7-1.
13. Singh R, Mishra SR, Sushobhana, Passey J, Kumar P, Singh S, et al. Sexual dimorphism in adult human mandible of north Indian origin. *Forensic Med Anat Res* 2015;3:82-8.
14. Nilton Alves and Naira Figueiredo Deana. Morphological Study of the Lingula in Adult Human Mandibles of Brazilians Individuals and Clinical Implications. *BioMed Res Int* 2015:1-7.

**How to cite this article:** Assis FP, Sudhakar AS, Remya C, Prakash KG. Varying shapes of lingula and its prevalence in dry adult human mandible. *Indian J Clin Anat Physiol* 2019;6(2):224-8.