

## Esthetic rehabilitation of malpositioned implants – A case report

Aanchal Punjabi<sup>1\*</sup>, Gaurang Mistry<sup>2</sup>, Rajeev Singh<sup>3</sup>

<sup>1</sup>Post Graduate Student, <sup>2</sup>Professor and HOD, <sup>3</sup>Professor, Dept. of Prosthodontics, DY Patil University, School of Dentistry, Maharashtra, India

\*Corresponding Author: Aanchal Punjabi

Email: aanchalpunjabi@gmail.com

### Abstract

The replacement of a missing tooth with an implant prosthesis has revolutionized oral rehabilitation by providing a predictable treatment modality. However, the placement of an incorrectly angulated implant results in several complications posing a demanding clinical scenario for prosthetic rehabilitation. An improperly angulated implant in the anterior esthetic zone can be restored with the help on a 2 unit Paulo Malo prosthesis in order to rectify the angulation, restoring the correct arch form, mask the labial screw holes and is easy to disassemble and repair; providing good retrievability.

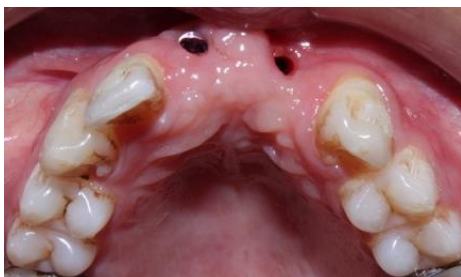**Keywords:** Esthetics, Anterior implant, Malpositioned, Paulo malo prosthesis.

### Introduction

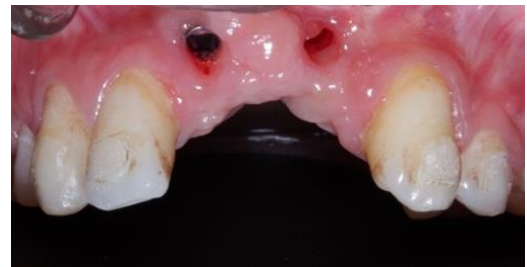A synergistic pink and white balance in the anterior esthetic zone is the ultimate objective of satisfactory treatment. An amalgamation of exacting patient expectations and compromised pre-existing anatomy manifests as one of the greatest challenges for a restorative prosthodontist. The replacement of a missing tooth with an implant prosthesis has revolutionized oral rehabilitation by providing a predictable treatment modality. The emphasis of treatment has gradually progressed from merely satisfying functional demands to restoring a combination of function and esthetics. The ideal implant placement requires an integration of precise treatment planning, meticulous surgical skills and accurate 3 dimensional implant placement. However, if a clinician falls short in any of the above areas, the prosthetic management of the hard and soft tissues poses a demanding clinical scenario, requiring a well-equipped restorative prosthodontist.

### Case Report

A 20 year old male presented to the Department of Prosthodontics and Implantology, DY Patil University, School of Dentistry, Mumbai with a chief complaint of missing maxillary anterior teeth and requested for the replacement of the same. The patient's history and clinical examination revealed that the patient had undergone a symphyseal graft followed by immediate endosseous implant placement (Noble Biocare, Replace) with healing abutments for both the maxillary central incisors.



**Fig. 1a:** Intra-oral pre-treatment frontal view



**Fig. 1b:** Intra-oral pre-treatment occlusal view

On further examination, the implants were osseointegrated with a severe labio-palatal angulation, increased subcrestal depth (5mm in the 21 region) and compromised position. Hence the patient was given the following treatment options:

1. Surgical removal of the malpositioned implants followed by a second grafting procedure and implant placement in a favorable position.
2. Prosthetic management using a two unit Paulo-malo prosthesis and laminate veneers on the adjacent teeth.

The patient was not willing to undergo an additional surgical procedure and opted for the prosthetic management of the existing implants.

A closed tray implant level impression was made with addition silicone impression material (Aquasil; Dentsply); the accuracy of which was clarified with the aid of a verification jig. The model was then scanned using an extra-oral scanner and a computer aided designing of the prosthetic framework along with the final prosthesis was done on the Exocad software. At this stage it was observed that the adjacent teeth (12, 23) required laminates for establishment of satisfactory proportions and shape correction as the canine had to be converted into a lateral incisor.

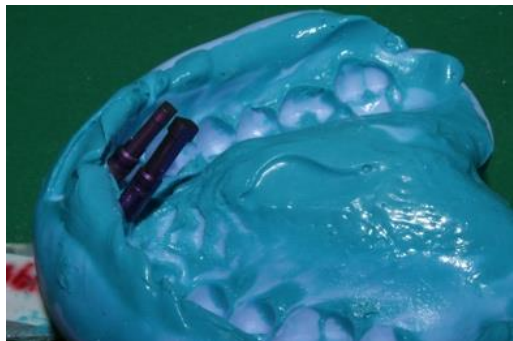


Fig. 2: Implant level impression



Fig. 6: Polymethyl methacrylate trial

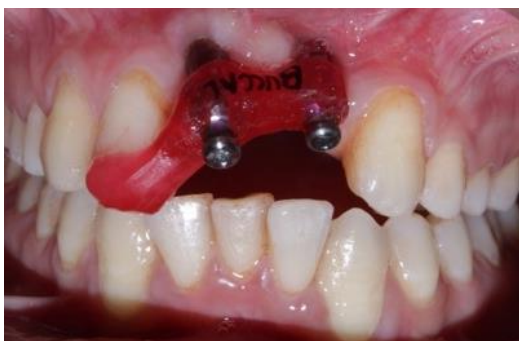

Fig. 3: Trial of verification jig

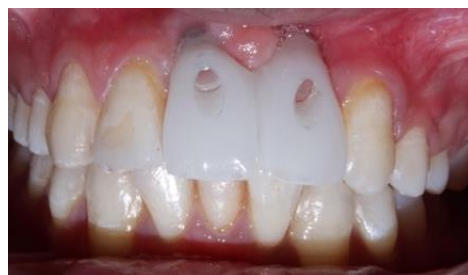

Fig. 7: Intra-oral trial of polymethyl methacrylate crowns

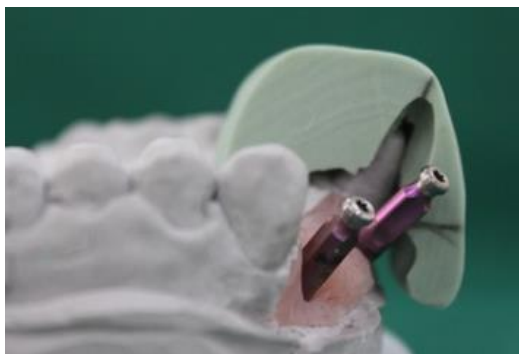

Fig. 4: Buccally tilted implant angulation. Note – correct tooth angulation depicted by the putty index.

Once the alterations were made, the screw-retained, definitive titanium framework was milled using computer aided manufacturing and verified intra-orally. Subsequently, the gingival aspect of the framework was layered with pink ceramic in addition to application of an opaquer over the abutments.



Fig. 8: Definitive titanium framework

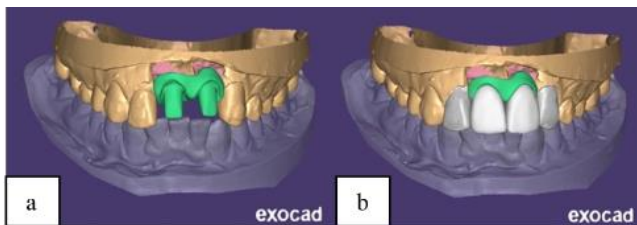


Fig. 5a, 5b: Computer aided design of prosthetic framework, final crowns and laminates.

On approval of the design, a polymethyl methacrylate trial was 3D printed and checked intra-orally for any modifications. Care was taken to ensure a correct angulation of the abutments along the contour of the maxillary arch in addition to a satisfactory level of the gingival zeniths and extra-oral lip support.

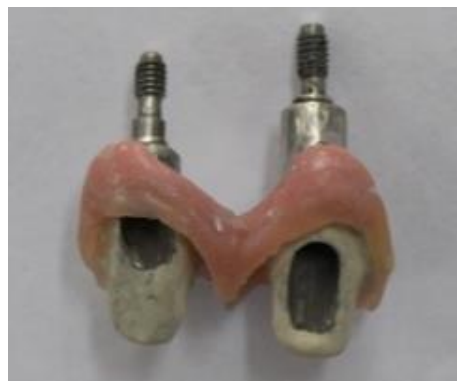
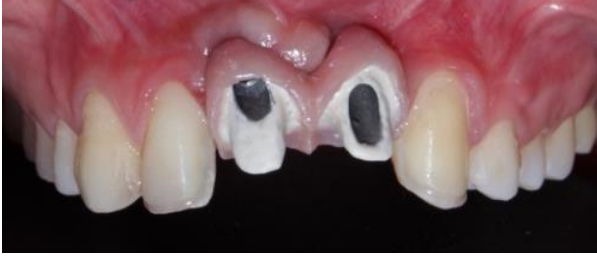
Fig. 9: Ceramic soft tissue moulage on the titanium framework

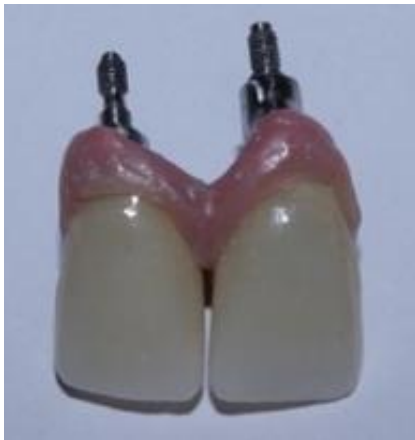

**Fig. 10:** Laminate preparation on 12, 23 and trial insertion of screw-retained framework

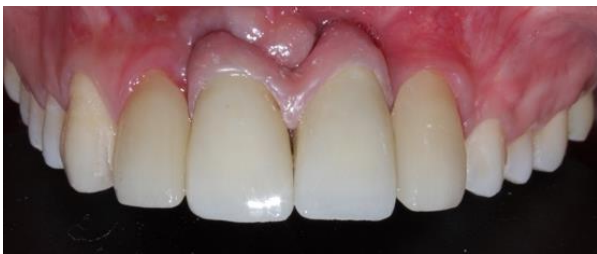Laminate preparation on 12 and 23 was done using Gurel’s technique to ensure a conservative preparation and a final impression of the prepared teeth along with the titanium framework was made in polyether impression material (Impregum; 3M ESPE).

This was followed by a bisque trial of the zirconia with ceramic layering crowns and lithium disilicate laminates. The overjet and overbite was maintained at 1.5mm to ensure a shallow anterior guidance.

Thereafter, the ceramic of the various parts of the definitive prosthesis were glazed. The abutment screws were tightened to a torque of 30N, followed by blockage of the screw-access hole with gutta percha and composite resin.

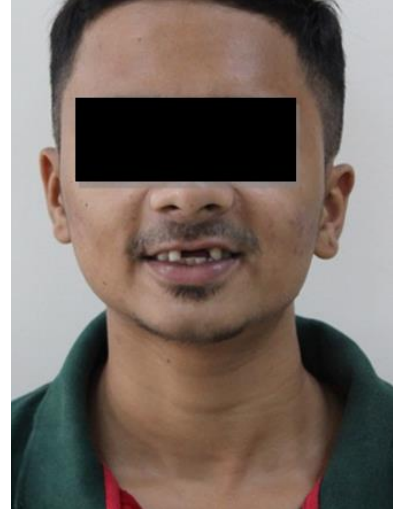

**Fig. 11:** Definitive prosthesis



**Fig. 12:** Intra-oral view of definitive Paulo Malo prosthesis and laminate veneers

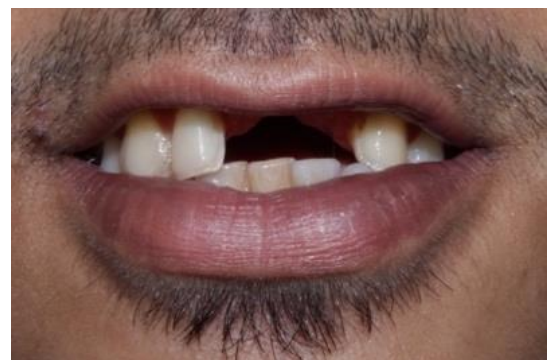The zirconia crowns were cemented with a resin reinforced glass ionomer cement (Fuji Cem, GC) and the laminates with a resin cement (Calibra).



**Fig. 13:** Pre-treatment extra-oral view

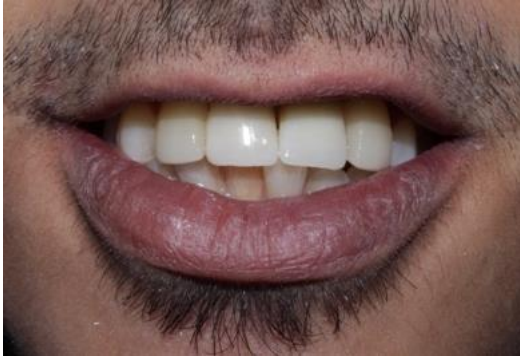

**Fig. 14:** Post-treatment extra-oral view



**Fig. 15:** Pre-treatment smile





**Fig. 16:** Post-treatment smile.

### Discussion

Restoration of a malposed implant is one of the most arduous clinical situations encountered by a prosthodontist. The scale of difficulty further escalates when the implant is within the anterior esthetic zone as that requires a tactful balance between the mechanical concepts of prosthetic implantology and satisfactory esthetics.

The treatment options available included angulated abutments with single crowns, splinted crowns, hybrid prosthesis or a combination screw-cement retained, Paulo-malo prosthesis.

1. Studies by Clelland et al, Pellizzer et al and Bergkvist have suggested that splinted restorations offer load sharing among the components of the rehabilitation and decrease the stress on cortical bone.<sup>1-3</sup> While the marginal bone loss in both splinted and unsplinted implants was similar, the implant survival rate for splinted implants was statistically higher than the latter in a meta-analysis done by de Souza Batista et al.<sup>4</sup> Therefore, a splinted prosthesis was preferred in order to minimize the risk of micromotion above physiologic limits.
2. Implant supported splinted crowns was the second treatment option, however, due to the unfavorable implant position and angulation, the screw holes would be directed buccally making a screw-retained implant prosthesis an esthetic failure. Additionally, a cement-retained prosthesis was deemed unfavorable in this clinical scenario due to the excessive subcrestal depth of the implants, which led to poor accessibility of the implant site for cement removal. This would invariably lead to a downward spread of inflammation, peri-implantitis and implant failure in the future.
3. A study conducted by Bozini T et al indicated that the most common prosthesis-related complication were acrylic resin veneer fracture and denture teeth wear.<sup>5</sup> Acrylic resin veneer fracture may be attributed to design issues and/or technical errors,<sup>6</sup> whereas the high frequency of tooth wear was attributed to the inherent limitations of resin denture teeth.<sup>7</sup> Therefore, a hybrid prosthesis was disregarded in this clinical scenario.

Keeping the above situation in mind, a screw-cement retained Paulo-Malo prosthesis was the treatment option of choice as this design combined the advantages of both

approaches. The screw-retained framework splints the two unfavorably angulated implants together, rectifying the angulation, restoring the correct arch form and is easy to disassemble and repair; providing good retrievability. The titanium framework veneered with gingiva-coloured porcelain conceals the soft and hard tissue defects, particularly in patients with severe alveolar ridge resorption,<sup>8</sup> establishing a good pink and white balance. The crowns were individually cemented to the titanium framework, ensuring that the designed prosthesis could provide optimal esthetics regardless of where the screw access openings were located.<sup>9-10</sup> This approach is beneficial for prosthesis maintenance and repair and permits the relatively easy cleaning of excess cement.

The excessive labial angulation and subcrestal position of the 2 implants documented in the case above, required thorough prosthetic planning with the help of a digital design protocol and polymethyl methacrylate trial, which allowed a 3-dimensional view of the underlying abutment framework and the final crowns at inception. The position of the final prosthetic assembly within the dental arch, shape and contour of the teeth requiring replacement, ratios and proportions of the teeth in the esthetic zone and the pink and white balance were all established with the aid of computer aided design and intra-oral trial. This trial was a scientific approach which gave the patient and clinician a complete picture of the final design, in the process proving to be cost effective and time efficient.

Subsequently, the titanium framework was milled using computer aided design and computer aided manufacturing. Conventionally, fabrication of superstructures for implant-supported fixed dental prosthesis was done using the lost-wax technique, which is labour intensive, technique sensitive and often fails to provide a passive fit for the framework.<sup>11-13</sup> The precision of the underlying framework fit is essential for optimal screw mechanics as several longitudinal clinical studies have demonstrated that poorly fitting frameworks are one of the primary causes of screw loosening or fracture, abutment fractures and even implant fracture. Hence, the introduction of CAD/CAM technologies for manufacturing implant superstructures has proven to be advantageous in the quality of materials, precision of the milled framework, and passive fit.<sup>14</sup> Moreover, the preserved data from the digital impression and design of the CAD/ CAM-fabricated titanium framework and restorations in the software can be used if repair or re-fabrication of the definitive cast and/or prosthesis is needed.<sup>15</sup>

Titanium was the material of choice because of its biocompatibility, light weight; as the prosthesis was reasonably bulky replacing the soft tissue and teeth, relative flexure compared to a rigid metal; since that would transmit less forces onto the underlying implant. Moreover, the milling accuracy of titanium and abutment fit provide an excellent advantage. The only disadvantage of this metal is its inherent greyness which shows through the crowns, compromising the overall result. This aspect was attended to by using an opaquer over the abutments.

Zirconia with ceramic layering was the selected final restoration because it made the crowns look more versatile, lifelike and natural in appearance. Thus, the individually luted crowns offered optimal esthetics and ease of repair in the event of restoration fracture.

### Conclusion

The case report presented above is a classic prosthodontic challenge faced by a clinician when the patient is unwilling to improve the surgical site and requests for rehabilitation of the existing situation. The biological, mechanical and esthetic factors were analysed along with the various treatment modalities available, in order to provide a favourable outcome. Therefore, a combination of advancements in technology, meticulous evaluation and superior prosthetic technique salvaged a compromised clinical scenario in the anterior esthetic zone.

**Conflict of Interest:** None.

### References

1. Clelland N, Chaudhry J, Rashid RG, McGlumphy E. Split-mouth comparison of splinted and nonsplinted prostheses on short implants: 3-year results. *Int J Oral Maxillofac Implants* 2016;31:1135-41.
2. Pellizzer E, Santiago J Jr, Villa L, de Souza Batista V, de Mello C, de Faria Almeida D, et al. Photoelastic stress analysis of splinted and unitary implant-supported prostheses. *Appl Phys B* 2014;117:235-44.
3. Bergkvist G, Simonsson K, Rydberg K, Johansson F, Derand T. A finite element analysis of stress distribution in bone tissue surrounding uncoupled or splinted dental implants. *Clin Implant Dent Relat Res* 2008;10:40-6.
4. de Souza Batista VE, Verri FR, Lemos CA, Almeida DA, Cruz RS, Oliveira HF, Gomes JM, Pellizzer EP. Should the restoration of adjacent implants be splinted or nonsplinted? A systematic review and meta-analysis. *J Prosthet Dent* 2018;119:1-11.
5. Bozini T, Petridis H, Garefis K, Garefis P. A meta-analysis of prosthodontic complication rates of implant-supported fixed dental prostheses in edentulous patients after an observation period of at least 5 years. *Int J Oral Maxillofac Implants* 2011;26:304-18.
6. Papaspyridakos P, Chen CJ, Chuang SK, Weber HP, Gallucci GO. A systematic review of biologic and technical complications with fixed implant rehabilitations for edentulous patients. *Int J Oral Maxillofac Implants* 2012;27:102-10.
7. Purcell BA, McGlumphy EA, Holloway JA, Beck FM. Prosthetic complications in mandibular metal-resin implant-fixed complete dental prostheses: a 5 to 9 year analysis. *Int J Oral Maxillofac Implants* 2008;23:847-57.
8. Wang P, Tang C, Tang Y, Wu Y. Immediate implant placement and complete mouth rehabilitation with CAD-CAM titanium frameworks and cemented crowns for a patient with severe periodontal disease: A clinical report. *J Prosthet Dent* 2018;119:511-5.
9. Shadid R, Sadaqa N. A comparison between screw- and cement-retained implant prostheses. A literature review. *J Oral Implantol* 2012;38:298-307.
10. Wittneben JG, Joda T, Weber HP, Brägger U. Screw retained vs. cement retained implant-supported fixed dental prosthesis. *Periodontol* 2000 2017;73:141-51.
11. Carr AB, Stewart RB. Full-arch implant framework casting accuracy: preliminary in vitro observation for in vivo testing. *J*

*Prosthodont* 1993;2(1):2-8.

12. Haselhuhn K, Marotti J, Tortamano P, Weiss C, Suleiman L, Wolfart S. Assessment of the stress transmitted to dental implants connected to screw-retained bars using different casting techniques. *J Oral Implantol* 2014;40(6):641-8.
13. Thalji G, Bryington M, Kok IJ, Cooper LF. Prosthodontic Management of Implant Therapy. *Dent Clin N Am* 2014;58:207-25.
14. Ortorp A, Jemt T, Back T. Comparisons of precision of fit between cast and CNC-milled titanium implant frameworks for the edentulous mandible. *Int J Prosthodont* 2003;16(2):194-200.
15. Lin WS, Metz MJ, Pollini A, Ntounis A, Morton D. Digital data acquisition for a CAD/CAM-fabricated titanium framework and zirconium oxide restorations for an implant-supported fixed complete dental prosthesis. *J Prosthet Dent* 2014;112:1324-9.

**How to cite the article:** Punjabi A, Mistry G, Singh R. Esthetic rehabilitation of malpositioned implants – A case report. *J Dent Specialities* 2019;7(1):49-53.