

## Diagnostic utility of Alpha Methylacyl CoA Racemase in prostatic adenocarcinoma: An institutional experience

Harsha Shrivastava<sup>1\*</sup>, S. B Patil<sup>2</sup>, Rajashekar KS<sup>3</sup>

<sup>1</sup>Post Graduate, <sup>2</sup>Professor, Dept. of Pathology, J.J.M. Medical College, Davangare, Karnataka, India

### Article Info

Received: 6<sup>th</sup> February, 2019

Accepted: 27<sup>th</sup> March, 2019

Published Online: 9<sup>th</sup> August, 2019

**Keywords:** Prostate adenocarcinoma, Gleason score, AMACR.

### Abstract

P504S is a prostate cancer specific gene that encodes for  $\alpha$ -methylacyl CoA racemase (AMACR). AMACR has been shown to be selectively over expressed in prostatic adenocarcinoma with minimal to undetectable expression in benign prostatic tissue. We studied the expression of AMACR in 30 cases of prostatic adenocarcinoma using polyclonal anti-AMACR antibody and correlated it with Gleason score. Extent of staining/proportion score (0: no positive cells; 1+: 1-10% positive cells; 2+: 11-50% positive cells; 3+: >50% positive cells) was also recorded and correlated with Gleason score. All the 30 cases showed strong, cytoplasmic granular AMACR staining irrespective of their Gleason score with 26 (86.7%) cases showing immunostaining in more than 50% tumor cells (3+ proportion score). Benign prostate tissue adjacent to adenocarcinoma showed negative AMACR staining. No correlation was seen between Gleason score and AMACR proportion score. We concluded that AMACR is a highly sensitive positive marker of prostatic adenocarcinoma.

### Introduction

Prostate cancer is the second most frequently diagnosed cancer and the fifth most common cause of death due to cancer in men worldwide.<sup>1</sup> Histologically adenocarcinoma is the most common subtype of prostate cancer and hence the need to find a sensitive immunohistochemical marker for diagnosing prostatic adenocarcinoma. AMACR is not only a sensitive but also a positive marker of prostatic adenocarcinoma. The AMACR gene (also referred to as P504S) was identified by Xu et al<sup>2</sup> in the year 2000 with the help of cDNA subtraction combined with high throughput microarray screening. AMACR is a mitochondrial and peroxisomal enzyme involved in the  $\beta$  oxidation of branched chain fatty acids and fatty acid derivatives. AMACR shows selective over expression in prostatic adenocarcinoma with minimal to undetectable expression in benign prostatic tissue. Our aim was to study the expression of AMACR in prostatic adenocarcinoma and to correlate the extent of AMACR staining with Gleason score.

### Materials and Methods

Ours is a 2 years study undertaken from June 2016 to May 2018 in the Department of Pathology, JJM Medical College, Davangere, following approval by the institutional ethical committee. 30 cases of prostatic adenocarcinoma were diagnosed during the study period. The specimens included TURP, Tru-cut needle biopsies and prostatectomies (Graph 1). The diagnosis of prostatic adenocarcinoma was established by examining haematoxylin and eosin (H&E)

stained sections. Prostatic adenocarcinomas were graded according to the 2014 ISUP/WHO Gleason grading of Prostatic carcinoma. There were ten cases with Gleason score 6, eight cases with Gleason score 7, four cases of Gleason score 8, six cases of Gleason score 9 and two cases of Gleason score 10 (Table 1). Polyclonal anti-AMACR antibody (1:100 dilution; Biocare Medicals, USA) was used. Negative control, in which the primary antibody was replaced by PBS, was carried out for each case. Prostate carcinoma was used as positive internal control. Circumferential, granular, luminal (apical) to diffuse cytoplasmic staining of acini was considered as positive AMACR staining while no staining or weak, non-circumferential staining was considered as negative AMACR staining. The extent of AMACR staining (AMACR Proportion score) was recorded as follows: 0 (no positive cells), 1+ (1-10% positive cells), 2+ (11-50% positive cells) and 3+ (>50% positive cells). Data was analyzed using SPSS version 24.0 for MS-Windows. Spearman correlation test was used to correlate Gleason score and AMACR proportion score. p value less than 0.05 was assumed significant.

### Results

All the 30 cases of prostatic adenocarcinoma showed positive AMACR expression irrespective of their Gleason score (Graph 1). AMACR expression was seen as granular, circumferential, diffuse cytoplasmic staining in the malignant glands/cells. 3+ expression of AMACR (>50% of

\*Corresponding Author: Harsha Shrivastava, Post Graduate, Dept. of Pathology, J.J.M. Medical College, Davangare, Karnataka, India  
Email: [harsha28may@gmail.com](mailto:harsha28may@gmail.com)  
<http://doi.org/10.18231/j.ijpo.2019.071>

tumor stained with AMACR) was seen in 26 of 30 (86.7%) prostatic adenocarcinomas (Table 2). Benign glands adjacent to the malignant glands were negative for AMACR. Gleason score was found to have no correlation with AMACR Proportion Score (Table 3).

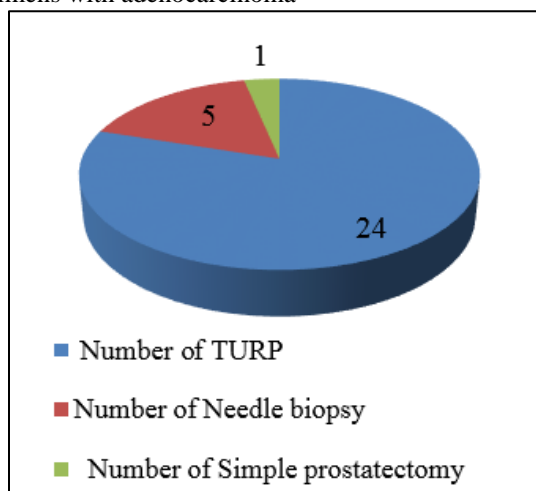
**Table 1:** Gleason score of prostatic adenocarcinomas

Gleason score	Number of cases
6	10
7	8
8	4
9	6
10	2

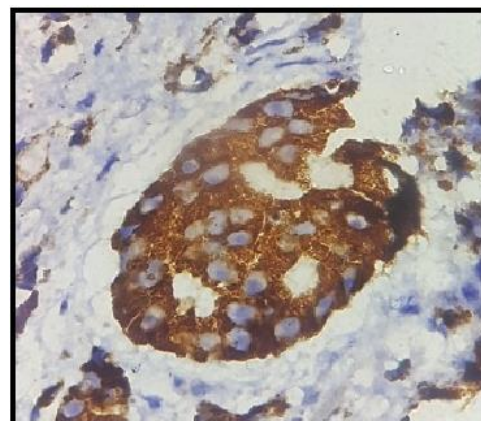
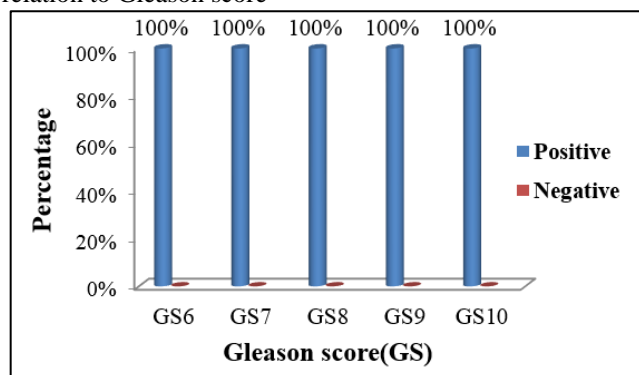
**Table 2:** Distribution of AMACR proportion score

AMACR proportion Score	Number of cases	Percentage (%)
0	0	0
1+	1	3.3
2+	3	10
3+	26	86.7

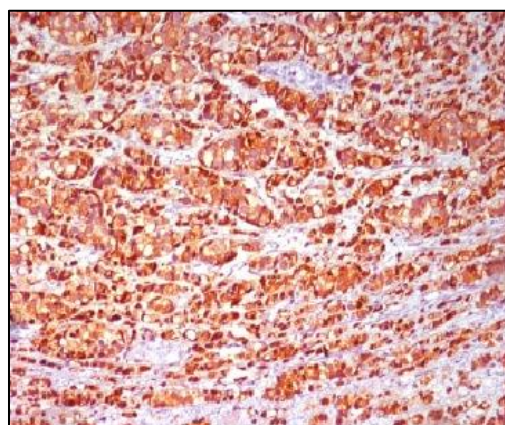
**Graph 1:** Pie chart depicting distribution of prostatic specimens with adenocarcinoma



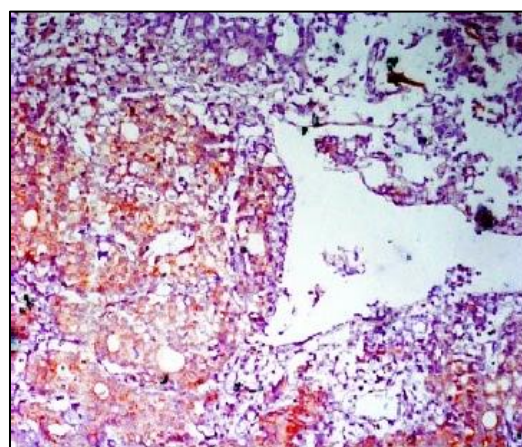
**Graph 2:** Bar diagram showing AMACR expression in relation to Gleason score



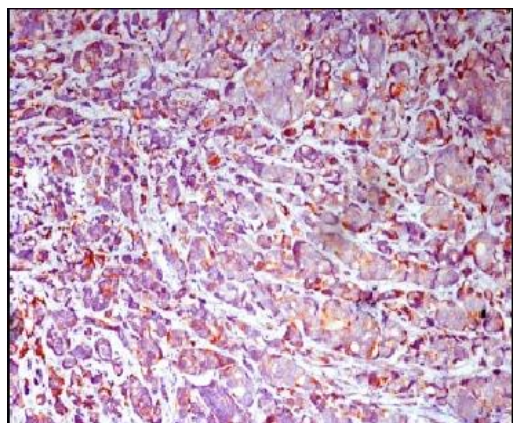
**Fig. 1:** Circumferential, granular, cytoplasmic staining pattern of AMACR seen in prostatic adenocarcinoma (1000X)



**Fig. 2:** Prostatic adenocarcinoma showing 3+ AMACR Proportion score (400X)



**Fig. 3:** Prostatic adenocarcinoma showing 2+ AMACR proportion score (400X)



**Fig. 4:** Prostatic adenocarcinoma a showing 1+ AMACR proportion score (400X)

### Discussion

Diagnosing prostate carcinoma is becoming challenging in the current times due to increase in the number of prostatic needle biopsy samples. This is because needle biopsies at times contain only a small focus of prostatic adenocarcinoma. It is also difficult to distinguish between prostatic adenocarcinoma and its benign mimickers on needle biopsies. Negative staining for basal cell markers like HMWCK and p63 can help in diagnosing prostatic adenocarcinoma but at times morphologically benign glands, atypical adenomatous hyperplasia foci and high grade PIN can also exhibit a discontinuous or even negative staining for HMWCK. Hence a positive IHC marker for prostatic adenocarcinoma like AMACR will be of great advantage.

We analyzed the expression of AMACR in 30 cases of prostatic adenocarcinoma. All the 30 cases stained with

AMACR showed positive AMACR expression. Thus the sensitivity of AMACR for prostatic adenocarcinoma in our study was 100% which is similar to the finding of Jiang Z et al.<sup>3</sup> Rubin MA et al<sup>4</sup> demonstrated 97% sensitivity of AMACR in the detection of prostate cancer. Beach R et al<sup>5</sup> reported 82% sensitivity of AMACR for prostate carcinoma. A total of 184 of 209 cases of prostate adenocarcinoma stained positively for AMACR in a study by Galluzi CM et al.<sup>6</sup> Positive AMACR staining was observed in 83% of prostate cancers in a study by Zhou M et al.<sup>7</sup> AMACR sensitivity in detecting prostate adenocarcinoma was 90% in a study by Rashed HE et al<sup>8</sup> and 90.6% in a study by Ozgur T et al<sup>9</sup> (Table 4).

Difference in sensitivity of AMACR in different studies including absent staining in prostatic adenocarcinoma can be a result of using different antibodies as polyclonal anti-AMACR is 100% sensitive while the sensitivity of monoclonal antiP504S in detecting prostate cancer is only 94%.<sup>10</sup> Other factors that can affect AMACR sensitivity are: concentration of the primary antibody, staining technique (manual or automated) and antigen retrieval protocol.

In our study, 26 (86.7%) prostatic adenocarcinoma cases showed AMACR staining in more than 50% cells. Jiang Z et al<sup>3</sup> and Galluzi CM et al<sup>6</sup> had 96% prostatic adenocarcinoma cases showing AMACR staining in more than 50% cells. Rashid HE et al<sup>8</sup> had 92.6% prostatic adenocarcinoma cases with AMACR staining in more than 50% of the malignant glands. Beach R et al<sup>5</sup> however had only 40% prostatic adenocarcinoma cases in which AMACR staining was present in more than 50% malignant cells (Table 5).

**Table 3:** Correlation of AMACR proportion score with gleason score

Gleason Score	No. of patients	AMACR proportion Score			
		0	1+	2+	3+
6	10	0(0%)	0(0%)	0(0%)	10(100%)
7	8	0(0%)	1(12.5%)	1(12.5%)	6(75%)
8	4	0(0%)	0(0%)	1(25%)	3(75%)
9	6	0(0%)	0(0%)	0(0%)	6(100%)
10	2	0(0%)	0(0%)	1(50%)	1(50%)

p value=0.31 Not significant

**Table 4:** Comparison of sensitivity of AMACR as a prostate cancer marker

Study	Type of antibody	Number of prostate cancer cases subjected to AMACR staining	Prostate cancer cases with positive staining	Sensitivity (%)
Jiang Z et al(2001)	Rabbit monoclonal anti-P504S	137	137	100
Rubin MA et al(2002)	Polyclonal anti-AMACR	70	68	97
Beach R et al(2002)	Rabbit monoclonal anti-P504S	186	153	82
Galluzie CM et al(2003)	Polyclonal anti-AMACR	209	184	88
Rashed HE et al(2012)	Rabbit monoclonal anti-P504S	30	27	90
Ozgur T et al (2013)	Polyclonal Rabbit Anti Human P504S	64	58	90.6
Present study(2018)	Polyclonal anti-AMACR	30	29	96

**Table 5:** Comparison of AMACR proportion score

Study	Number of prostate cancer cases with positive AMACR staining	Positive cases with 3+ proportion score	Percentage
Jiang Z et al(2001)	137	132	96
Beach R et al(2002)	153	60	40
Galluzi CM et al(2003)	184	178	96
Rashid HE et al(2012)	27	25	92.6
Present study(2018)	30	26	86.7

Our study found no correlation between Gleason score and AMACR Proportion score indicating that AMACR expression does not depend on tumor differentiation. This finding is similar to the study by Jiang Z et al<sup>2</sup> who demonstrated a diffuse staining pattern (>75% cells positive) for AMACR in prostatic carcinoma regardless of the Gleason score. Beach R et al<sup>4</sup> made similar observation and concluded that Gleason score has no correlation with the amount of AMACR staining. Rubin MA et al<sup>4</sup> showed strong cytoplasmic AMACR staining in both high-grade and low grade prostatic carcinoma with no association between amount of AMACR staining and Gleason score. Ozgur T et al<sup>9</sup> also did not find any significant correlation between histopathological grade of the tumor and AMACR expression.

Our study confirms that AMACR is a sensitive marker for prostatic adenocarcinoma. Benign prostatic tissue, benign mimickers of prostatic adenocarcinoma like atrophy, basal cell hyperplasia, and inflammatory glands most often show negative AMACR expression. However a diagnosis of benignancy should not be made based only on a negative AMACR staining as AMACR can sometimes be negative in adenocarcinoma. Also the sensitivity of AMACR in detecting some variants of prostatic adenocarcinoma like atrophic, foamy gland and pseudohyperplastic is only 70%, 68% and 77% respectively.<sup>3</sup> Hence results of AMACR staining should be interpreted only in the context of strict morphologic correlation. Also it is better to combine AMACR with a negative marker of prostatic adenocarcinoma like a basal cell marker as the contrasting staining results for adenocarcinoma (positive staining with AMACR and lack of staining with basal cell marker) will not only complement each other but will also increase the diagnostic confidence.

### Conclusion

IHC with anti-AMACR/P504S can detect prostatic adenocarcinoma in all types of prostatic specimens be it needle biopsy or TURP or prostatectomy. AMACR is a highly sensitive marker for prostatic adenocarcinoma. AMACR also shows high specificity for prostatic adenocarcinoma as the benign prostatic tissue adjacent to carcinoma shows negative AMACR staining. Expression of AMACR is not affected by the Gleason score of the prostatic adenocarcinoma. However because of variable sensitivity of AMACR, the diagnosis of prostatic adenocarcinoma should be based on architectural and

cytological findings on H&E stain with use of AMACR possibly in combination with a basal cell marker in suspicious cases containing atypical glands.

**Conflict of Interest:** None.

**Source of Funding:** None.

### References

- Budakh A, Bakshi G, Prakash G. Change in the ranking and increasing trend of the prostate cancer from the population-based cancer registries in India. *Indian J Urol* 2018;34:235-6.
- Xu J, Stolk JA, Zhang X. Identification of differentially expressed genes in human prostate cancer using subtraction and microarray. *Cancer Res* 2000;60:1677-82.
- Jiang Z, Woda BA, Rock KL, Xu Y, Suvas L, Khan A. P504S: A new molecular marker for the detection of prostate carcinoma. *Am J Surg Pathol* 2001;25:1397-1404.
- Rubin MA, Zhou M, Dhanasekaran SM.  $\alpha$ -Methylacyl coenzyme A racemase as a tissue biomarker for prostate cancer. *JAMA* 2002;287:1662-70.
- Beach R, Gown AM, De Peralta-Venturina MN. P504S immunohistochemical detection in 405 prostatic specimens including 376 18-gauge needle biopsies. *Am J Surg Pathol* 2002;26:1588-96.
- Magi-Galluzzi C, Luo J, Isaacs WB. Alpha-methylacyl-CoA racemase: a variably sensitive immunohistochemical marker for the diagnosis of small prostate cancer foci on needle biopsy. *Am J Surg Pathol* 2003;27:1128-33.
- Zhou M, Chinnaiyan AM, Kleer CG. Alpha-methylacyl-CoA racemase: a novel tumor marker overexpressed in several human cancers and their precursor lesions. *Am J Surg Pathol* 2002;26:926-31.
- Rashed HE, Kateb MI, Ragab AA, Shaker SS. Evaluation of minimal prostate cancer in needle biopsy specimens using AMACR(P504S), p63 and Ki67. *Life Sci J* 2012;9:12-21.
- Ozgur T, Atik E, Hakverdi S, Yaldiz M. The expressions of AMACR and iNOS in prostate adenocarcinomas. *Pak J Med Sci* 2013;29:610-13.
- Kunju LP, Chinnaiyan AM, Shah RB. Comparison of monoclonal antibody (P504S) and polyclonal antibody to alpha methylacyl-CoA (AMACR) in the workup of prostate cancer. *Histopathol* 2005;47:587-96.

**How to cite this article:** Shrivastava H, Patil SB, Rajashekar KS. Diagnostic utility of Alpha Methylacyl CoA Racemase in prostatic adenocarcinoma: An institutional experience. *Indian J Pathol Oncol* 2019;6(3):368-71.