

Rare case of neurofibroma of cheek- Case report

Shaik Ali Hassan^{1*}, Sumit Bhateja², Geetika Arora³

¹Dental Surgeon, ²HOD, ³Reader, ^{1,2}Manav Rachna Dental College, Faridabad, Haryana, ³Inderprastha Dental College & Hospital, Ghaziabad, Uttar Pradesh, India

***Corresponding Author: Shaik Ali Hassan**

Email: alishaikhassan@gmail.com

Abstract

Plexiform neurofibroma is most debilitating form on neurofibromatosis-1. They most often are recognized with the presence of café-au-lait macules which are coffee in milk colour. In our case of plexiform neurofibroma was in form of trident (Thrishul) which patient was having since childhood and now its increased in size. In this case report we describe the rare type of plexiform neurofibroma of cheek.

Keywords: Plexiform neurofibroma, Neurofibromatosis type-1, Café-au-lait spots, Trident, Von recklinghausens disease, Crowes sign.

Introduction

A neurofibroma is a benign tumor of the nerve sheath in the peripheral nervous system. The most common being neurofibromatosis type I (NF-I) or von Recklinghausen's disease. NF-I is an autosomal dominant genetic disorder that can lead to a variety of symptoms, from disfigurement to pain and cognitive impairment. Neurofibromas arise from schwann cells that exhibit biallelic inactivation of the NF-I gene on chromosome region 17q11.2 that codes for the protein neurofibromin.¹ NF-I is estimated to occur in one in every 3000 births with no sex predilection.²⁻⁴ Most of the time it is tested by genetic method, only 2/3rd of cases are detected but cannot say the severity of disease. Some researchers say that neurofibromas alone are pathognomonic of the disease. The condition can cause disfigurement by affecting important supportive structures.⁵ The PNF is seen at birth and often develops in early childhood with a growth rate and a structure that varies considerably and unpredictably.²⁻⁴ Due to the involvement of several nerve and tissue packages and the spread of Plexiform neuro fibroma (PNF), the risk of neurological and functional destruction during surgical resection is high. As a result, surgical procedures are often delayed as long as possible in childhood. Most cases require repeated operations because they are limited to implementation.⁶

Case Report

A male patient of age 59 years reported to department of oral medicine and radiology with the chief complaint of growth on the left side of the face. There was no medical history associated. Patient doesn't has any history of drug allergy. Patient gives a history of smoking since 15-20 years. There was no known evidence of hereditary disease in the family and none of the other relatives had a known history of this disease. Patient said that the growth was there since birth and now it increased in size and causing esthetic problem for the patient. On physical examination the café-au-lait macules seen on left cheek (Fig. 1) measuring more than 5.5mm which were in the form of trident, one macule extending from corner of lower lip, 2nd macule going towards the orbit, and last macule extending towards the left ear tragus. An incisional biopsy was taken from the lip lesion and stained with

hematoxylin and eosin (H and E). Haematoxylin examination (Fig. 2) revealed that the presence of cellular neoplasm composed of combined proliferation of schwann's cells, fibroblast, perineural cells and axon cells. Schwann cells are spindle cells with wavy nuclei arranged in bundles. The endoneurium showed myxoid changes. With the biopsy we came to conclusion as the plexiform neurofibroma.

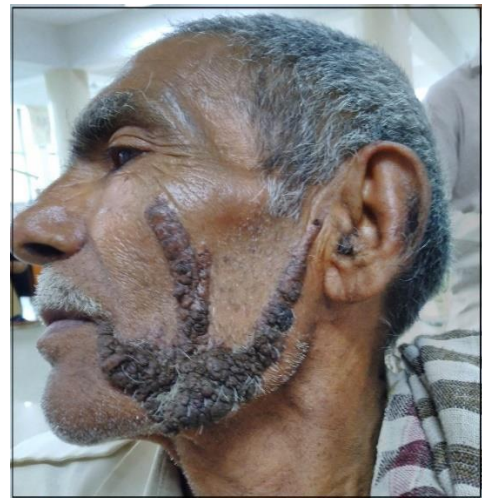

Fig. 1: Plexiform neurofibroma with café-au-lait macules

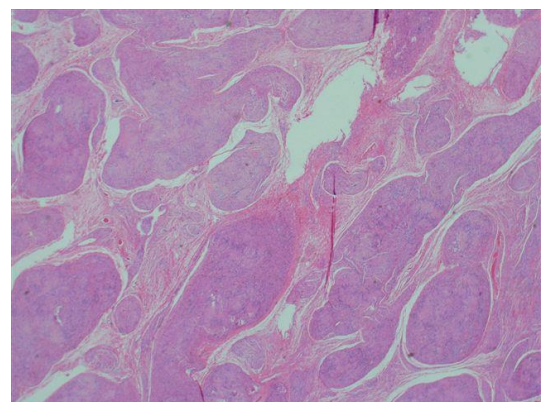


Fig. 2: Haematoxylin and eosin staining of plexiform neurofibroma

Discussion

The neurofibroma is the most common type of peripheral nerve neoplasm. It arises from a mixture of cell types, including Schwann cells and perineural fibroblasts. Solitary tumors are most common in young adults and present as slow-growing, soft, painless lesions that vary in size from small nodules to larger masses. The skin is the most frequent location for neurofibromas, but lesions of the oral cavity are not common. In oral cavity it affects only tongue and buccal mucosa. The main diagnostic criteria for plexiform neurofibroma.

The diagnostic criteria are met when a patient has two or more other following functions:

1. At least six macules of coffee with milk of more than 5 mm. larger diameter in prepubertal people and more than 15 mm in diameter, the largest in post-puberty people
2. Two or more neurofibromas of any type plexiform neurofibroma
3. Freckles in the armpit or groin
4. Optical glioma
5. Two nodes of Lisch or more (Iris hamartomas)
6. A typical bone lesion, such as sphenoid bone. Dysplasia or thinning of the long bone cortex with or no pseudoarthrosis.
7. First-degree relatives (parents, siblings or descendants) with NF1, based on the a Forementioned criteria.⁷ Patients have multiple neurofibromas that can do it.

It occurs throughout the body, but occurs more frequently on the skin. The clinical appearance may vary from small papules become larger, soft to massive hanging nodules masses (neuromatous elephantiasis) on the skin. The plexiform neurofibroma, which feels like a “bag of worms,” is considered as good indicator for Neurofibroma -1. The tumor are present at birth, but they often begin to appear during puberty and may continue to develop slowly throughout adulthood as they go unnoticed in child phase. Growth can increase in pregnancy phase. Another characteristic feature is presence of pigmentation of coffee with milk (coffee with milk) in the Skin which is calle café-au-leit spots. These spots are smooth, yellow-brown in color. Dark brown macules whose diameter varies from 1 to 2 mm to several centimeters. They are generally are present at birth or can develop during the first year of life. Freckles are also included under the armpits (Crowes sign). Lisch nodules, translucent brown-pigmented spots on the iris, are found on all affected individuals. The most common general medical problem is hypertension, which may develop secondary to coarctation of the aorta, pheochromocytoma, or renal artery stenosis. In our patient also there was hypertension. Most important complication is the developing of cancer, most often a malignant peripheral nerve sheath tumor (neurofibrosarcoma, malignantschwannoma). There is no therapy for Neuro Fibroma-1, and treatment often is directed toward prevention or management of complications. Facial neurofibromas can be removed for cosmetic purposes using Carbon dioxide (CO₂) laser been used successfully for extensive lesions.

Source of funding

None.

Conflict of interest

None.

References

1. Kleihues P, Cavenee WK. World Health Classification of Tumours. 1st edition. Lyon: IARC Press; 2000. Pathology and genetics of tumours of the nervous system.
2. Cawthon RM, Weiss R, Xu GF, Viskochil D, Culver M, Stevens J, et al. A major segment of the neurofibromatosis type I gene: cDNA sequence, genomic structure, and point mutations. *Cell* 1990;62:193–201.
3. Viskochil D, Buchberg AM, Xu G, Cawthon RM, Stevens J, Wolff RK, et al. Deletions and a translocation interrupt a cloned gene at the neurofibromatosis type I locus. *Cell* 1990;62:187–92.
4. Wallace MR, Marchuk DA, Andersen LB, Letcher R, Odeh HM, Saulino AM, et al. Type I neurofibromatosis gene: Identification of a large transcript disrupted in three NF1 patients. *Sci* 1990;249:181–6.
5. Friedrich RE, Schmelzle R, Hartmann M, Fünsterer C, Mautner VF. Resection of small plexiform neurofibromas in neurofibromatosis type I children. *World J Surg Oncol* 2005;3:6.
6. Sengupta SP. 1st ed. Calcutta: New Centre Book Agency Publications; 1996. Manual of Long and Short Cases in Surgery.
7. Neville BW, Damm DD, Allen CM, Bouquot JE. *Oral Maxillofac Pathol* 2nd ed. Philadelphia: Elsevier; 2002. p. 457-61.

How to cite this article: Hassan SA, Bhateja S, Arora G. Rare case of neurofibroma of cheek- Case report. *Int J Oral Health Dent* 2019;5(3):143-4.