

Apathetic hyperthyroidism with recurrent pre-syncope: An apathetic diagnostic challenge

Shivani Solanki^{1,*}, Rachana Gupta², Sakshi Sharma³, Sourya Acharya⁴, Samarth Shukla⁵

¹⁻³MBBS Student, ^{4,5}Professor, ⁴Dept. of Medicine, ⁵Dept. of Pathology, Jawaharlal Nehru Medical College, Datta Meghe Institute of Medical Sciences, Wardha, Maharashtra, India

***Corresponding Author:**

Email: shivanisolanki00@gmail.com

Abstract

Apathetic hyperthyroidism is a rare presentation of thyrotoxicosis which is commonly seen in elderly individuals. In this condition, the classical signs of hyperthyroidism are absent irrespective of the increased thyroid hormones level. The patient presents with signs and symptoms like lethargy, weakness, loss of weight, and depression. We present a case of apathetic hyperthyroidism in a 77-year-old male patient who presented to us with complaints of intermittent anxiety attacks because of paroxysmal atrial fibrillation, weakness, fatigability and chronic depression. The patient was diagnosed as a case of apathetic hyperthyroidism with paroxysmal atrial fibrillation.

Keywords: Hyperthyroidism, Paroxysmal atrial fibrillation, Thyroid hormones.

Introduction

In 1931 Lahey, described a form of hyperthyroidism known as apathetic or masked thyrotoxicosis which typically occurs in elderly persons. Irrespective of having hyperthyroidism, these patients do not present with classical signs of thyrotoxicosis, rather they present with apathy, decreased motor activity, depression and chronic fatigue.

It is an uncommon but well-recognised presentation of thyrotoxicosis in elderly people.

The diagnosis is suspected when manifestations such as weight loss, weakness, depression, lethargy, dry skin and tachy or bradyarrhythmias are present in an elderly without any obvious cause.

The cardiac manifestations associated with apathetic hyperthyroidism are ischemic heart disease, congestive cardiac failure, thyrotoxic cardiomyopathy, various tachyarrhythmias and bradyarrhythmias. Atrial fibrillation occurs in most of these cases. Low serum thyrotropin concentration is an independent risk factor for atrial fibrillation. On treatment with antithyroid drugs, atrial fibrillation is usually reverted.

Case Report

A 77-year-old male presented to us with chief complaints of attacks of intermittent anxiety, sometimes associated with pre-syncope on and off since 5 months, chronic depression since 4 months, extreme weakness and fatigability since 3 months. There was no history of exertional dyspnoea, orthopnoea, paroxysmal nocturnal dyspnoea, swelling in both lower limbs, chest pain, chronic diarrhoea, blood loss, cough, expectoration, joint pains.

On asking leading questions, patient gave history of weight loss of seven kilograms over the 6 months. For these complaints, patient had visited several clinics and

hospital with a myriad of investigations, was given antidepressant drugs, antacids, cardiac evaluation was done in a hospital which was negative for any pathology.

On examination, patient was slightly anxious, pulse was 108 beats per min, regular, normal volume and peripheral pulses were well felt. Respiratory rate was 16 breaths per minute. Oxygen saturation was 99% while the patient was breathing ambient air. Blood Pressure was 120/90 mmHg. Pallor, icterus and clubbing were absent. JVP was 4cm of water. There was no oedema feet. Examination of neck did not reveal any goitre. CVS, RS and per abdomen was normal.

CNS examination: Higher functions: Patient was anxious and irritable. There were no hallucinations or delusions. Cognition, abstract reasoning, judgement, calculation were normal. Speech was normal. All cranial nerves were intact. Motor system examination revealed bilateral diminished ankle jerks. Sensory system was normal.

There were no thyrotoxic eye signs, tremors, warmth in the palm, ptosis, weakness in proximal muscles and pre-tibial myxoedema.

On investigations, haemoglobin was 12.2gm%. TLC 8000 per cubic mm. KFT, LFT were normal. X-Ray chest was normal. USG and CECT abdomen was normal. Stool for occult blood negative. Upper GI endoscopy and colonoscopy was normal. Prostate specific antigen was normal. 2D echocardiography was normal. Serum metanephrin levels were normal.

The patient was started on conventional antidepressants and tab propranolol 40mg BID and multivitamins. On the second day of hospitalisation, the patient again had an attack of anxiety and complained of palpitations. On examination, the patient was severely anxious and was profusely sweating. Pulse-

140 beats per minute, irregularly irregular. Apex pulse deficit was 24. ECG revealed atrial fibrillation with a fast ventricular rate (Figure-1). Blood pressure was 98 systolic. The patient was immediately given inj. diltiazem 10 mg i.v. bolus and 10mg per hour infusion. Within half an hour, the atrial fibrillation was spontaneously converted to sinus rhythm. A transoesophageal echocardiography was normal. The patient was put on dual antiplatelets. Thyroid profile revealed; TSH <0.001 iu, FT4- 20µg/dl (Normal range- 4.5-11.7µg/dl), FT3- 10.3µg/dl (Normal range- 1.3-5.4µg/dl). USG of the thyroid gland was normal.

A diagnosis of apathetic thyrotoxicosis with episodic atrial fibrillation was kept and antithyroid drugs in the form of tab methimazole 20mg TDS was initiated. Beta blocker continued. Tab diltiazem 30mg TDS was initiated. Thyroid scanning was advised but patient denied for further investigations, was discharged and is awaiting follow up after one month.

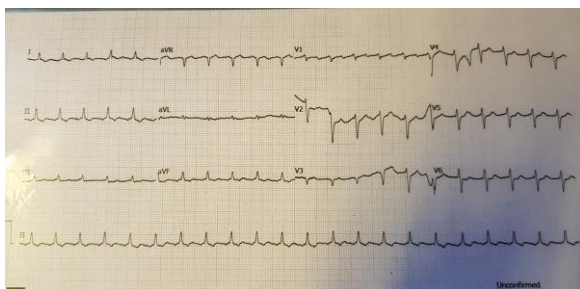


Fig. 1: ECG showing atrial fibrillation with fast ventricular rate

Discussion

Apathetic thyrotoxicosis, also known as masked or hidden thyrotoxicosis, in which irrespective of having increased levels of thyroid hormones in the body, the patient do not classically present with typical manifestations of hyperthyroidism. This condition typically affects the elderly population. The patient usually presents with depression, weight loss, and latent cardiac manifestations specially arrhythmias, heart failure. Because of subtle clinical symptoms and absence of classical clinical signs the diagnosis is often delayed unless a strong suspicion is kept while dealing such cases.

With increased age, the typical symptoms of hyperthyroidism becomes less evident.

The term apathetic was used because of the apathy showed by the patient which is paradoxical to hyperthyroid symptoms.¹ The explanation for apathy and depression in such cases is hypothesised as deficiency of catecholamines and dopamine in the brain. Thyrotoxicosis decreases levels of catecholamines. Another mechanism which is postulated is unresponsiveness of the catecholamines at the receptor level.^{2,3}

Cardiac manifestations of hyperthyroidism range from ischemic heart diseases, congestive heart failure,

thyrotoxic cardiomyopathy, various tachyarrhythmias and bradyarrhythmias. Atrial fibrillation occurs in 10-15% patients of hyperthyroidism. As the age advances, especially elderly hyperthyroid patients older than 60 years are vulnerable. Only 5% hyperthyroid patients under the age of 60 years have atrial fibrillation.^{4,5} The typical atrial fibrillation associated with hyperthyroidism is persistent.⁶ Paroxysmal atrial fibrillation is a rare entity associated with hyperthyroidism. Our patient was unique to have episodic paroxysmal atrial fibrillation that lead to his symptoms, along with other features of apathetic hyperthyroidism.

Elevated thyroid hormones by changing the electrophysiological characteristics of atrial myocytes in form of decreasing the action potential duration, increasing the automaticity leads to the arrhythmogenic trigger around the pulmonary vein cardiac myocytes. The catastrophic complications of atrial fibrillation, especially in elderly, is cerebral embolization.⁷

Management in such cases is usually by anticoagulation therapy till the hyperthyroid phase is controlled by drugs.⁸ As anticoagulation therapy in elderly also predisposes to increased risk of cerebral haemorrhage, prothrombin time should be done intermittently and interpreted cautiously in such cases. In those patients when monitoring is difficult antiplatelet therapy may suffice.⁹ Our patient belonged to a peripheral rural village and as the compliance for meticulous prothrombin time assessment was doubtful, we continued antiplatelet therapy.

To conclude, our patient had apathetic hyperthyroidism with paroxysmal atrial fibrillation leading to intermittent pre-synopes and anxiety attacks. He had other features of apathetic hyperthyroidism in form of depression fatigue and weight loss. Clinicians should keep a high index of suspicion while dealing with elderly persons with unexplained arrhythmias and thyroid profile is mandatory in any elderly patient with behavioural or mood abnormalities.

References

1. Lahey FH. Non-activated (apathetic) type of hyperthyroidism. *N Engl J Med* 1931;204:747-48.
2. McClure DI. Biochemistry of depression. *Can Psychiatr Assoc J* 1971;16(3):247-52.
3. Apathetic thyrotoxicosis (editorial). *Lancet* II 809, 1970.
4. Sawin CT, Geller A, Wolf P, et al. Low serum thyrotropin concentrations as a risk factor for atrial fibrillation in older persons. *N Engl J Med* 1994;331:1249-52.
5. Forfar JC, Miller HC, Toft AD, et al. Occult thyrotoxicosis: a reversible cause of "idiopathic" atrial fibrillation. *Am J Cardiol* 1979;44:9-12.
6. Vargas-Uricoechea H, Bonelo-Perdomo A, Sierra-Torres CH. Effects of thyroid hormones on the heart. *Clin Invest Arterioscler* 2014;26(6):296-309.
7. Staffurth JS, Gibberd JS, Tang FS, et al. Arterial embolism in thyrotoxicosis with atrial fibrillation. *Br Med J* 1977;2:688-90.

8. European Heart Rhythm A, Heart Rhythm S, V. Fuster. ACC/AHA/ESC 2006 guidelines for the management of patients with atrial fibrillation-executive summary: a report of the American College of Cardiology/American Heart Association Task Force on practice Guidelines and the European Society of Cardiology Committee for practice guidelines (Writing committee to revise the 2001 guidelines for the management of patients with atrial fibrillation. *J Am Coll Cardiol* 2008;48(4):854-906.
9. Miller V, Pearce L, Feinberg W, et al. Differential effect of aspirin versus warfarin on clinical stroke types in patients with atrial fibrillation. *Neurol* 1996;46:238-24.

How to cite this article: Solanki S, Gupta R, Sharma S, Acharya S, Shukla S. Apathetic hyperthyroidism with recurrent pre- syncope: An apathetic diagnostic challenge. *Ann Geriatrics Educ Med Sci.* 2018;5(2):69-71.