

## Fibrous dysplasia of the ethmoid and anterior skull base

Anitha Kumari A M<sup>1</sup>, Ria Emmanuel<sup>2\*</sup>, Alphonsa Thomas<sup>3</sup>

<sup>1</sup>Consultant, <sup>2</sup>Senior Resident, <sup>3</sup>Resident, Manipal Hospital, Dept. of ENT, Manipal Hospital, Bangalore, Karnataka, India

\*Corresponding Author: Ria Emmanuel

Email: riaishere@gmail.com

### Abstract

A case of Fibrous Dysplasia of the anterior skull base with involvement of crista galli, ethmoids and middle turbinate is being reported. These tumours should be considered in the differential diagnosis of bony tumours of anterior skull base. We would like to highlight the importance of thorough assessment of radiological imaging prior to biopsy or surgical debulking of such tumours.

**Keywords:** Fibrous dysplasia, Middle turbinate, Endoscopic surgery.

### Introduction

Fibrous Dysplasia (FD) constitute 75% of tumors of sinonasal area. Skull base involvement is seen in 10-25% of monostotic and in 50% of polyostotic FD.<sup>1</sup> FD in this area becomes a diagnostic dilemma due to close resemblance to ossifying fibroma, osteoma and lesions of chondrogenic origin. A case of bony tumor of ethmoid is discussed to highlight the confirmation of diagnosis and treatment.

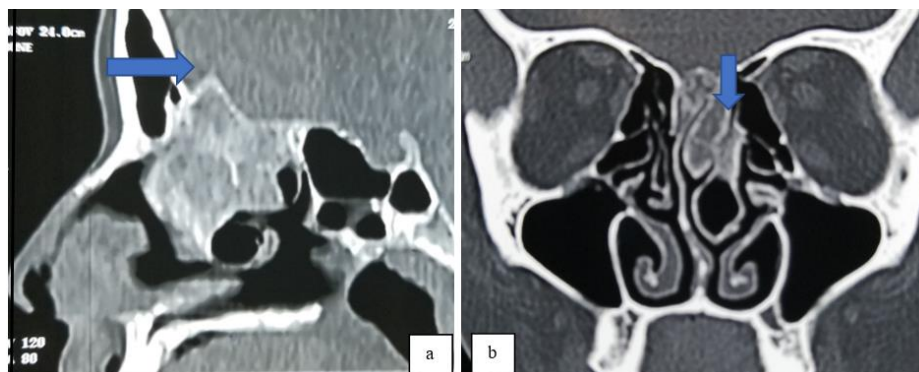
### Case Report

A 26 year old lady referred from neurology presented to the ENT department with complaints of pain over left side of nose for 7 months, headache for a month and blurring of vision in left eye for 2 weeks. Diagnostic nasal endoscopy showed normal mucosa of nasal cavity with a deviated nasal septum to right and spur to left, bulky left middle turbinate and clear bilateral osteomeatal complexes. Ophthalmology evaluation and lab parameters were within normal limits.

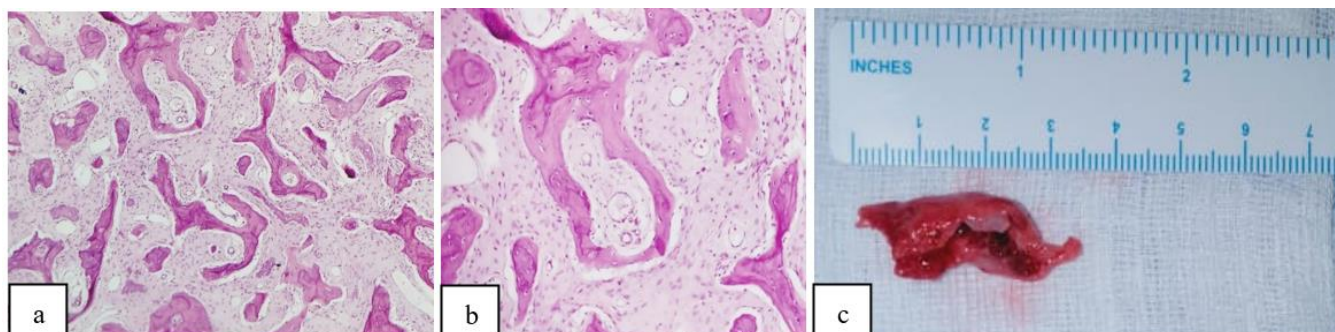
Computed Tomography (CT) imaging showed ground glass appearance of the superior and middle turbinate (MT),

cribriform area involving the crista galli and heterogenous opacification of the left ethmoidal sinus. MRI brain with contrast showed soft tissue intensity in left upper nasal cavity and ethmoid sinus, which appeared iso-hypointense on T1 and iso intense on T2 weighted sequence. The patient was suspected to have an osteolytic lesion involving the anterior skull base with fungal sinusitis. She underwent endoscopic surgery. After entering into the concha on left, excision of MT was performed following ethmoidectomy. Specimen was sent for histopathological examination. Tissue from ethmoid sinus and concha were found gritty with no resemblance to fungal sinusitis. Plan for wide excision was dropped and decided to follow the histology report.

Microscopic examination revealed features suggestive of FD in the chronic stage. Blood work up and systemic examination was within normal limits hence confirmed to be a case of monostotic FD. The patient is asymptomatic post operatively and is on six monthly follow up.



**Fig. 1:** CT scan of the nose and paranasal sinuses; **a:** Sagittal image showing ground glass appearance of the entire extent of the cribriform plate with involvement of the crista galli; **b:** Coronal image showing areas of heterogenous calcification of the left superior and middle turbinate (concha bullosa involving lamellar and bulbous parts) and the cribriform area, heterogenous opacity in left ethmoidal sinus



**Fig. 2:** Haematoxylin and eosin stained photomicrograph; **a:** fragments lined by respiratory epithelium, sub epithelium shows edema, submucous glands, mild inflammation; **b:** bony fragments with haphazardly arranged variably mineralized, curvilinear bony trabeculae with minimal osteoblastic rimming, no nuclear atypia in the osteoblasts; **c:** resected portion of middle turbinate

### Discussion

FD is a skeletal disorder characterized by progressive replacement of the normal bony structures with benign cellular fibrous connective tissue, which is caused by missense mutation of the gene *GNAS1* on chromosome 20. It is categorized based on the extent of involvement into monostotic and polyostotic FD. It may also be a part of McCune Albright syndrome (MAS) or of the Jaffe-Lichtenstein syndrome (JLS). JLS is characterized by polyostotic FD and café-au-lait pigmented skin lesions, while MAS has additional features of hyperfunctional endocrinopathies manifesting as precocious puberty, hyperthyroidism or acromegaly.<sup>1,2</sup>

Imaging description on CT scan is categorized into ground glass pattern with obliteration of corticomedullary distinction (56%), uniformly sclerosing pattern (23%), and cystic variety (21%).<sup>1</sup> Sclerotic form of disease can be mistaken for osteoma or ossifying fibroma.<sup>3</sup> Whereas, localized FD on MRI with contrast often mimics a tumor because fibrous tissue enhance brilliantly. The signal intensity of fibrous dysplasia has been reported to be low on T1-weighted images and T2-weighted images reveal it as either hyperintense or hypointense, which vary based on the amount and degree of bony trabeculae, cellularity, collagen and cystic or hemorrhagic changes.<sup>1</sup>

The histological appearances correspond to the stage of the disease. In acute stage there is rich cellular connective tissue with mitotic figures and woven immature bone, whereas in subacute stage the tissues become less cellular and fibrous, arranged in whorls. In chronic stage laminated bony trabeculae occur in abundance with a rim of osteoblasts. Total serum alkaline phosphatase and urinary hydroxyproline are elevated in active phase of FD in 75% of patients.<sup>3</sup>

Asymptomatic, stable lesions that are located in a silent area can be followed up as prognosis is good in monostotic

FD. Therapeutic debulking is required in cases where it causes pain, deformity, functional impairment and pressure symptoms, to relieve symptoms without curative intent<sup>4</sup>. Though radiology plays an important role, diagnosis needs to be confirmed histologically to chalk out the appropriate line of management.

### Source of Funding

None.

### Conflict of Interest

None.

### References

1. Chong VFH, Khoo JBK. Fibrous dysplasia involving the base of the skull. *Am J Roentgenol.* 2002;178:717-20.
2. DiCaprio MR, Enneking WF. Fibrous dysplasia. Pathophysiology, evaluation, and treatment. *J Bone Joint Surg Am.* 2005;87:1848-64.
3. Bhat V, Kansal K, Krishna SH, Pobby Shetty R, Hassan S. Fibrous dysplasia of the middle nasal turbinate: imaging and clinical significance. *BJR Case Rep.* 2016;2:20150296.
4. Feller L, Wood NH, Khammissa RA, Lemmer J, Ruabenheimer EJ. The nature of fibrous dysplasia. *Head Face Med.* 2009;5:22.

**How to cite this article:** Kumari AAM, Emmanuel R, Thomas A. Fibrous dysplasia of the ethmoid and anterior skull base. *IP Indian J Anat Surg Head Neck Brain.* 2020;6(1):30-1.