



Original Research Article

A prospective study to compare the quality of analgesia after breast cancer surgery using pectoral nerve block versus thoracic paravertebral block

S Meena^{1,*}, H. M Hajashareef², T Murugan²

¹Dept. of Anaesthesiology, Tamil Nadu Government Multi Super Specialty Hospital, Chennai, Tamil Nadu, India

²Government Kilpauk Medical College, Chennai, Tamil Nadu, India



ARTICLE INFO

Article history:

Received 26-05-2019

Accepted 04-11-2019

Available online 20-11-2019

Keywords:

Pectoral nerve block

Thoracic paravertebral block

Modified radical mastectomy.

ABSTRACT

Introduction: Pectoral Nerve block is an interfascial plane block which provides analgesia after breast cancer surgery while Thoracic Paravertebral block is also widely used. This study is designed to compare the quality of analgesia after Modified Radical Mastectomy using the two techniques in terms of, the time for the first request of rescue analgesic, 24 hrs analgesic requirement, Visual Analogue Score for pain at rest at 1 and 6 hours postoperatively.

Results: Patients undergoing breast cancer surgeries done under general anaesthesia at Govt. Kilpauk Medical College and Govt. Royapettah Hospital, Chennai between January 2017 and June 2017 belonging to ASA 1 & 2 were included in this study, 30 patients in PECS group and 30 in TPB group. In TPB group, the time for first rescue analgesia was between 141-360 minutes postoperatively (n=17, 56.67%) than in PECS group where the time for first rescue analgesia was between 121-240 minutes postoperatively (n=27, 90.00%)(p= <0.0001, unpaired t test) 24 hours analgesic consumption in TPB group was 100 mg tramadol postoperatively (n=26, 86.67%) while in PECS group it was 300 mg tramadol postoperatively (n=13, 43.33%)(p= <0.0001, unpaired t test). VAS scores in TPB group at 1 hour and 6 hours postoperatively were 0.00 and 2.13 while VAS in PECS group at 1 hour and 6 hours were 2.00 and 4.00(p= <0.0001, unpaired t test)

Conclusion: Thoracic paravertebral block reduced the 24 hour analgesic consumption, reduced VAS scores at 1 and 6 hours and prolonged the time required for the first request of analgesic compared to pectoral nerve block after modified radical mastectomy

© 2019 Published by Innovative Publication. This is an open access article under the CC BY-NC-ND license (<https://creativecommons.org/licenses/by/4.0/>)

1. Introduction

Breast cancer is the most common cancer among women and the incidence of breast cancer continues to rise. Most women will experience acute post operative pain after breast cancer surgery. Acute post operative pain is an integral risk factor for the development of chronic pain after breast cancer surgery.

Postoperative pain is of prime concern following breast cancer surgeries. The main objective of providing post operative analgesia is to make the patient comfortable without pain, improve early ambulation, improve respiratory function and early restoration of her routine life.

* Corresponding author.

E-mail address: meenadoc@gmail.com (S. Meena).

Thoracic paravertebral block²¹ and thoracic epidural block are widely used for anaesthesia and postoperative pain management after breast cancer surgeries. Pectoral nerve block is a newer technique reported by Blanco et al.¹ This study is designed to compare the quality of analgesia after Modified Radical Mastectomy using Pectoral nerve block and Thoracic Paravertebral block, in terms of, the time for the first request of rescue analgesic, 24 hrs analgesic requirement, Visual Analogue Score for pain at rest at 1 and 6 hours postoperatively, Hemodynamic parameters.

PECS block is performed with the patient in supine position by placing the ipsilateral upper limb in abduction, with a 50mm needle using a linear USG probe of high frequency (6-13 MHz), placed at infra clavicular region

directly above first rib. In PECS 1, the drug is injected between pectoralis major and minor muscles. In PECS 2, the USG probe is moved towards the axilla till serratus anterior muscle is identified above second, third and fourth ribs and the drug is injected into the fascial plane between the pectoralis minor and serratus anterior muscle.² Thoracic Paravertebral block is performed with the patient in sitting position at the level of 4th thoracic vertebra with a low resistant technique using an 18G Tuohy needle. The tip of the spinous process is marked on the skin. A para sagittal line is drawn 2.5cms lateral to the midline. At this point, the needle is advanced perpendicularly seeking contact with transverse process of 4th thoracic vertebra, then sliding the needle caudally for 1-1.5cms into the paravertebral space. After negative aspiration for blood and csf, the drug is injected.

2. Materials and Methods

After obtaining Institutional Ethical Committee (Govt. Kilpauk Medical College) clearance, written informed consent was taken from 60 patients, aged 30 to 60 years, with carcinoma breast stage 1 & 2, scheduled for modified radical mastectomy during January 2017 to June 2017. Patients were excluded if there was involvement of the upper, outer quadrant, an allergy or sensitivity to local anaesthetics, spine or chestwall deformities or active infection at the injection site, BMI more than or equal to 35/kg/m², impaired ability to communicate (e.g., confusion, poor hearing or language barrier), uncontrolled diabetes mellitus, systemic hypertension, severe cardiovascular disease, patients on beta blocker therapy, pregnant patients and Lactating mothers, patients with Coagulation disorders or receiving anticoagulant therapy, sensory block on the contralateral side after paravertebral block, surgical time exceeding 2 hrs. During preoperative visit, demographic data was recorded and Visual Analogue Score (VAS of 1-10) was explained to the patients. A total of 60 patients were allocated according to computer generated sequence into two equal groups, Group 1(PECS-30) & group 2(TPB-30). Group 1 received USG guided PECS block with a high frequency linear probe, 10 ml of 0.25% bupivacaine was injected between pectoralis major & minor, 20 ml of 0.25% bupivacaine was injected between pectoralis minor & serratus anterior. Group B received a single ipsilateral paravertebral block, at T4 level with 20ml of 0.25% bupivacaine. The sensory level was tested with pin prick before induction of general anaesthesia.

Patients were premedicated with Inj. Glycopyrrolate 10mcg/kg IV, Inj. midazolam 0.01mg/kg IV, Inj. fentanyl 2mcg/kg IV. Preoxygenated with 100% oxygen for at least 3 minutes under closed circuit. Induction was done with Inj. Propofol 2mg/kg and Atracurium 0.5mg/kg. Intubated with endotracheal tube of appropriate size(7 or 7.5 mm ID)

for the patient and secured in a proper manner after checking bilateral equal breath sounds. Maintenance was done with nitrous oxide and oxygen in the ratio of 2:1 and sevoflurane 1-2%. Duration of surgery of 2 hours was included in the study

At the end of surgery, patients were extubated after reversal of neuromuscular blockade by injecting neostigmine (50mcg/kg) and glycopyrrolate (10mcg/kg) and shifted to postoperative care unit. Postoperatively patients were assessed for the following

1. Time for request of first analgesic
2. Visual analogue score at rest at 1 and 6 hrs
3. 24 hour analgesic consumption (inj. Tramadol 100 mg im / Inj Paracetamol 1g iv)
4. Hemodynamic parameters

2.1. Statistical analysis

Descriptive statistics were done for all data and reported in terms of mean values and percentages. Suitable statistical tests of comparison were done. Continuous variables were analysed with the unpaired t test. Categorical variables were analysed with the Chi-Square Test and Fisher Exact Test. Statistical significance was taken as P<0.05. The data was analysed using SPSS version 16 and Microsoft Excel 2007.

3. Results

A total of 60 patients were included in the study. The two groups were comparable with respect to Age and Weight.(p value > 0.05). The time for the first request of analgesic was longer in the TPB group, 141-360 minutes than in the PNB group, 121-240 minutes (p=< 0.0001) as in figure 1. 24 hours Analgesic consumption was less in the TPB group, which was about 100 mg tramadol compared to PNB group which required 300mg of tramadol. (p=< 0.0001) as shown in Figure 2. The VAS scores at rest at 1 hour and 6 hours postoperatively in TPB group was 0 and 2 while in PNB group it was 2 and 4. (p=< 0.0001) as in Figure 3 . With regards to hemodynamic parameters, the mean Heart rates before block, pre- induction, post induction & postoperative periods in TPB group were 90.23, 92.13, 96.47, 72.07 while in PNB group it was 97.07, 99.30, 101.53, 85.24 (p=<0.0001). The MAP before block, pre-induction, post- induction & postoperative periods in TPB group were 93.63, 92.27, 84.63, 74.47 while in PNB group it was 99.57, 99.47, 90.20, 91.10 (p=< 0.0001).

4. Discussion

This study shows that thoracic paravertebral block is superior to pectoral nerve block, in terms of time for the request of first analgesic, 24 hours analgesic consumption, VAS scores at 1 and 6 hours at rest.

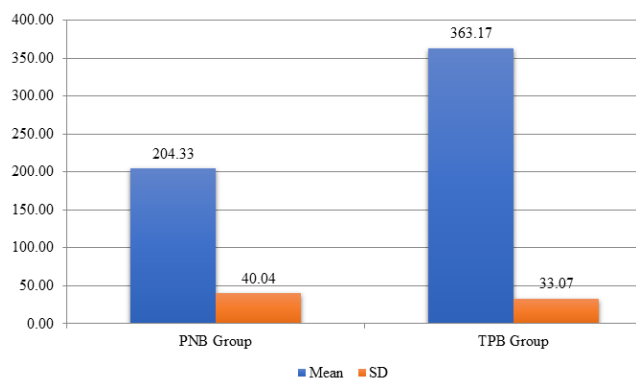


Fig. 1: First rescue analgesic distribution

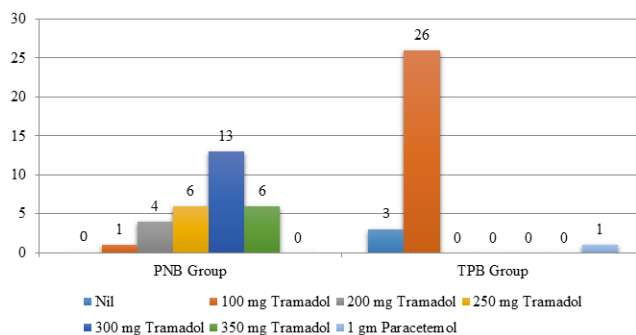


Fig. 2: 24 Hours analgesic consumption groups

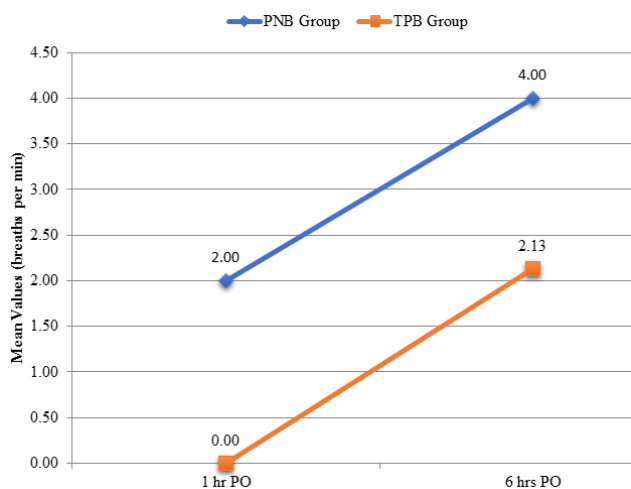


Fig. 3: Visual Analog Scale

Pectoral nerve block is easy to perform, simpler and without any complications but the level of analgesia is lesser than thoracic paravertebral block. It can be performed in supine position and the patient acceptance was also better because the procedure was less invasive. No complications occurred in the pectoral nerve block group in the study. The level of analgesia was lesser because its an interfascial plane block where the drug is injected in between the muscle planes, blocking the pectoral, intercostobrachial,3,4,5,6 intercostal nerves.

With respect to thoracic paravertebral block, the analgesia can be attributed to the containment of the space, limiting anaesthetic drug diffusion and prolonged afferent blockade. The only limitation associated with this technique are the complications²⁰ associated with the block, like pneumothorax, pleural puncture and vascular puncture. These can be avoided by the use of ultrasound guided block.¹⁷ There was one patient where there was epidural spread of the drug in our study. Postoperative analgesia can be prolonged by catheter placement in the paravertebral space & using 0.0625% or 0.125% bupivacaine at a rate of 3 to 10 ml/hr. Postoperative analgesia is possible with other techniques like thoracic epidural which is associated with postural hypotension due to sympathectomy and neurological injury. Thoracic paravertebral block has a minimal risk of neurological injury and being unilateral, sympathectomy causes minimal hypotension. The postoperative pulmonary function was preserved and coughing was effective in patients who received paravertebral block. There was good hemodynamic stability and no patients developed significant hypotension, bradycardia or desaturation. It is considered one of the oldest blocks, which came to light by Hugo Sellheim in 1905. However, it went into neglect until the work by Eason and Wyatt,¹² who renewed interest, especially in thoracic paravertebral block where a single injection provides analgesia over six dermatomes.

In our study, we found thoracic paravertebral block had lower VAS scores, prolonged duration of analgesia and lesser analgesic requirements compared to pectoral nerve block. We did not encounter any complications except for epidural spread in two patients.

5. Results

Thoracic paravertebral block reduces postoperative pain scores, increases the time for first rescue analgesic requirement and decreases the analgesic requirement in the postoperative period compared to pectoral nerve block

6. Source of Funding

None.

7. Conflict of Interest

None.

8. Reference

- Blanco R. The ‘ pecs block ’ : a novel technique for providing analgesia after breast surgery. *Anaesth* 2011;66:847– 848.
- Blanco R, Fajardo M, Parras Maldonado T. Ultrasound description of Pecs II (modified Pecs I): a novel approach to breast surgery. *Rev Esp Anest esiol Reanim* 2012 ;59:470 –475.
- Bashandy GM, Abbas DN. Pectoral nerves I and II blocks in multimodal analgesia for breast cancer surgery: a randomized clinical trial. *Reg Anesth Pain Med* 2015 ;40:68–74.
- Klein SM, Bergh A, Steele SM, Georgiade GS, Greengrass RA. Thoracic paravertebral block for breast surgery. *Anesth Analg* 2000 ;90:1402–1405.
- Schnabel A, Reichl SU, Kranke P, Pogatzki -Zahn EM, Zahn PK. Efficacy and safety of paravertebral blocks in breast surgery: a meta-analysis of randomized controlled trials. *Br J Anaesth* 2010;105:842–852.
- Tahiri Y, Tran DQ, Bouteaud J, Xu L, Lalonde D, Luc M, et al. General anaesthesia versus thoracic paravertebral block for breast surgery: a meta-analysis. *J Plast Reconstr Aesthet Surg* 2011;64:1261–1269.
- M.Z. Naja, M.F. Ziade, P.A. Lonnqvist, Nerve-stimulator guided paravertebral blockade vs. general anaesthesia for breast surgery: a prospective randomized trial. *Eur J Anaesth* 2003;20: 897–903
- M.A. Terheggen, F. Wille, I.H.B. Rinkes, T.I. Ionescu, J.T. Knape, Paravertebral blockade for minor breast surgery, *Anesth Analg* 2002;94:335–339.
- D.J. Buggy, M.J. Kerin, Paravertebral analgesia with levobupivacaine increases postoperative flap tissue oxygen tension after immediate latissimus dorsi breast reconstruction compared with intravenous opioid analgesia. *Anesthesiol* 2004;100:375–380.
- C.L. Burlacu, H.P. Frizelle, D.C. Moriarty, D.J. Buggy, Fentanyl and clonidine as adjunctive analgesics with levobupivacaine in paravertebral analgesia for breast surgery. *Anaesth* 2006;61:932–937.
- L.A. Sopena-Zubiria, L.A. Fernández-Meré, C. Valdés Arias, F. Muñoz González, J. Sánchez Asheras, C. Ibáñez Hernández et al, Thoracic paravertebral block compared to thoracic paravertebral block plus pectoral nerve block in reconstructive breast surgery. *Rev Esp Anesthesiol Reanim* 2012;59:12–17.
- M.J. Eason, R. Wyatt, Paravertebral thoracic block: a reappraisal, *Anaesth* 1979;34:638–642.
- T. Sidiropoulou, O. Buonomo, E. Fabbi, M.B. Silvi, G. Kostopanagiotou, A.F. Sabato et al, A prospective comparison of continuous wound infiltration with ropivacaine versus single-injection paravertebral block after modified radical mastectomy. *Anesth Analg* 2008;106(3):997–1001
- M.A. Terheggen, F. Wille, I.H. Borel Rinkes, T.I. Ionescu, J.T. Knape, Paravertebral blockade for minor breast surgery. *Anesth Analg* 2002;9:355–359.
- E. Coveney, C.R. Weltz, R. Greengrass, Use of paravertebral block anesthesia in the surgical management of breast cancer: experience in 156 cases, *Ann Surg* 1998;227:496–501
- F. Pusch, H. Freitag, C. Weinstabl, Single-injection paravertebral block compared to general anaesthesia in breast surgery. *Acta Anaesthesiol Scand* 1999;43:770–774.
- B. Cowie, D. McGlade, J. Ivanusic, M.J. Barrington, Ultrasound guided thoracic paravertebral blockade: a cadaveric study. *Anesth Analg* 2010;110:1735–1739.
- G. Purcell-Jones, C.E. Pither, D.M. Justins, Paravertebral somatic nerve block: a clinical, radiographic, and computed tomographic study in chronic pain patients. *Anesth Analg* 1989;68:32–39.
- B. Lekhak, C. Bartley, I.D. Conacher, S.M. Nouraei, Total spinal anaesthesia in association with insertion of a paravertebral catheter, *Br J Anaesth* 2001;86:280–282.
- P.A. Lönnqvist, J. MacKenzie, A.K. Soni, I.D. Conacher, Paravertebral blockade. Failure rate and complications *Anesth* 1955;50:813–815.
- M.K. Karmakar, Thoracic paravertebral block, *Anesthesiol* 2001;95:771–780

Author biography

S Meena Assistant Professor

H. M Hajashareef Senior Assistant Professor

T Murugan Professor and Chief Anaesthesiologist

Cite this article: Meena S, Hajashareef HM, Murugan T. A prospective study to compare the quality of analgesia after breast cancer surgery using pectoral nerve block versus thoracic paravertebral block. *Indian J Clin Anaesth* 2019;6(4):592-595.