



## Original Research Article

## Dexmedetomidine as an adjuvant to infraorbital block in children undergoing cleft lip surgery – A clinical comparative study

R D Ravichandra<sup>1</sup>, G B Sumalatha<sup>1,\*</sup><sup>1</sup>Dept. of Anaesthesiology, ESIC Medical College, Gulbarga, Karnataka, India

## ARTICLE INFO

## Article history:

Received 08-11-2019

Accepted 16-11-2019

Available online 28-02-2020

## Keywords:

Analgesia

Bupivacaine

Dexmedetomidine

Infraorbital nerve block

## ABSTRACT

**Introduction:** Regional nerve blocks provide excellent analgesia in children without adverse effects. However the duration of analgesia may be limited therefore addition of adjuvants can effectively prolong the duration of analgesia. Since alpha 2 agonist effectively prolong the duration of analgesia, we conducted a randomised double blind study to evaluate the effectiveness of dexmedetomidine as an adjuvant in infraorbital nerve block.

**Materials and Methods:** Eighty children of ASA grade 1 and 2, of either sex scheduled for cleft lip repair under general anaesthesia were allocated randomly into one of two equal groups (Group B and Group D, n=40). In both group infraorbital nerve block was performed with 1ml of solution on each side. The B group received bupivacaine 0.25% and the D group received bupivacaine 0.25% with 0.5µg/kg dexmedetomidine. The mean duration of analgesia and number of patients receiving rescue analgesia was recorded in both groups. The intraoperative hemodynamic parameters and postoperative sedation scores were recorded. For pain and sedation scores, Mann–Whitney U-test was used. Fisher's exact test was used for comparison of categorical data.  $P \leq 0.05$  was considered as the level of statistical significance.

**Results:** Both groups were comparable in demographic profile. The mean duration of analgesia in Group D (733±49.15 minutes) was significantly longer compared to Group B (496±28.26) ( $p=0.001$ ). There was a statistically significant difference in the number of patients receiving rescue analgesics in Group B (36) and Group D(8). The number of times of rescue analgesics in Group B and Group D was 3and 1 respectively, which was statistically significant. The intraoperative and postoperative hemodynamic HR was comparable in both groups (Figure 2). The sedation score in the postoperative period did not differ between the two groups.

© 2020 Published by Innovative Publication. This is an open access article under the CC BY-NC-ND license (<https://creativecommons.org/licenses/by/4.0/>)

### 1. Introduction

Postoperative pain is often underestimated in children although it is known that pain pathways are developed by 30th week of gestation.<sup>1</sup> Cleft lip is one of the condition which requires early surgical treatment.<sup>2</sup> Bilateral infra-orbital nerve block is proved to produce good postoperative analgesia in patients undergoing cleft lip repair surgery.<sup>3</sup> The advantage of infra- orbital nerve block is that it reduces the use of opioid analgesics which may lead to respiratory depression.<sup>4</sup> Since single dose of local anaesthetic may have limited duration of action, numerous additives have been

used to prolong the duration of postoperative analgesia. Dexmedetomidine, an alpha-2 agonist has been proved effective in producing prolonged postoperative analgesia when added in peripheral nerve blocks.<sup>5,6</sup> Hence we conducted this prospective, randomized, double-blind study to compare the efficacy of dexmedetomidine as an adjuvant for bupivacaine in infra-orbital block in pediatric patients for cleft lip repair. The primary objective of this study was to compare the mean postoperative duration of analgesia defined as the time from the end of successful block to the time of first rescue analgesic. The number of patients requiring the rescue analgesic was also recorded. The secondary outcomes were to evaluate intra-operative and

\* Corresponding author.

E-mail address: [gbsumaravi@gmail.com](mailto:gbsumaravi@gmail.com) (G. B. Sumalatha).

post-operative hemodynamic parameters and postoperative sedation score.

## 2. Materials and Methods

After obtaining the institutional ethical committee clearance, 80 patients belonging to American society of Anaesthesiologist Physical status(ASA) grade 1 & 2 of either sex, aged 3 months to 1 year scheduled for cleft lip repair were considered in the study. The exclusion criteria included ASA grade 3 & 4, failure to obtain consent from parents, local infection at the site of injection, associated congenital anomalies, history of upper or lower airway problems and known coagulation disorders.

Pre-anesthetic evaluation was done a day prior to the surgery involving a complete assessment of the patient with required investigations. Preoperative fasting was followed according to the standard guidelines. After obtaining written informed consent from parents, patients were randomly allocated to two groups (n=40) using computer-generated randomization numbers with a closed-seal envelope. In both the group, infra-orbital nerve block was performed bilaterally by landmark technique using 1ml of solution on each side. The B group received bupivacaine 0.25%, whereas the D group received bupivacaine 0.25% with 0.5 µg/kg of Dexmedetomidine (Dextomed, neon).

General anaesthesia was induced by the inhalation of 8% sevoflurane in 100% oxygen via a face mask with spontaneous ventilation. Monitors were connected to monitor heart rate (HR), pulse oximeter (SpO<sub>2</sub>), non invasive blood pressure (NIBP), Electrocardiogram(ECG), End tidal carbon dioxide (ETCO<sub>2</sub>), body temperature and anaesthetic gas monitor (AGM). An appropriate size peripheral intravenous (IV) cannula was secured in all the patients. The patients received premedication as per the institutional protocol. No additional sedatives and analgesics were administered. Injection propofol 2mg/kg was given IV to facilitate Oral endotracheal intubation. After successful intubation the endotracheal tube was secured centrally over the lower lip. As per the randomisation infra- orbital block was performed bilaterally by landmark technique by the anaesthesiologist blinded to the nature of the drug injected. Anaesthesia was maintained with 1 minimum alveolar concentration of sevoflurane in a 50% oxygen – nitrous oxide mixture with spontaneous ventilation. Isolyte -P solution was infused at a calculated rate according to the patients weight. The block was considered successful when the HR remained stable (not > 20% increase in heart rate (HR) or mean arterial blood pressure) compared to basal HR before the incision. If the block failed, IV fentanyl 1 µg/kg was administered. At the end of the surgery and before extubation, paracetamol suppository at a dose of 10mg/kg was administered to all the patients. Patients were extubated in the operating room after pharyngeal aspiration and recovery of airway-

protective reflexes.

The FLACC scale was used for assessment of postoperative pain.<sup>7</sup> The score was interpreted as: 0: Relaxed, comfortable 1-3: Mild discomfort 4-6: Moderate pain 7-10: Severe pain or discomfort or both. The pain score was assessed every 10 minutes for one hour in post anaesthesia care unit and then every 3 h for 24 h postoperatively in surgical ward. When the pain score exceeded 4, infusion of paracetamol at a dose of 10mg/kg was given over ten minutes. The time from the administration of block to the first analgesic request and the number of patients who received pain medication during the first 24-h were recorded. Postoperative sedation was evaluated hourly by Richmond scale for the first 3 h.<sup>8</sup>

Using the results obtained from previous studies and assuming an alpha error of 0.05 and beta error of 0.2 (power of the study 80%), a sample size of 40 patients per group was calculated. Data were presented as mean and standard deviation, median and range or numbers, and percentages. For normally distributed data, unpaired t-test was used to compare between mean values of both groups. For pain and sedation scores, Mann–Whitney U-test was used. Fisher's exact test was used for comparison of categorical data. P ≤ 0.05 was considered as the level of statistical significance.

## 3. Results

The demographic data was comparable in both groups [Table 1]. The mean duration of postoperative analgesia was 496± 28.26 minutes and 733±49.15 minutes in Group B and Group D respectively [Table 2]. The dexmedetomidine group showed significantly prolonged duration of analgesia when compared to bupivacaine alone group(p=0.001). In Group B, 36 patients required rescue analgesics whereas in Group D 8 patients required rescue analgesics which was statistically significant. The number of times of rescue analgesics in bupivacaine group (Group B) and in dexmedetomidine group (Group D) was 3 and 1 respectively, which was statistically significant (Figure 1). The intraoperative and postoperative HR was similar in both groups (Figure 2). The sedation score in the postoperative period was comparable in both groups.

## 4. Discussion

Peripheral nerve blocks are considered as a good intraoperative and postoperative analgesic technique with limited adverse effects. The drawback of regional block is its lesser duration of action when plain local anaesthetic is used. In order to prolong the duration of nerve blocks, many additives have been evaluated. Dexmedetomidine, an α<sub>2</sub>-receptor agonist has also been evaluated for its effectiveness in prolonging the duration of postoperative analgesia.<sup>9–13</sup>

Various studies in adults suggested that dexmedetomidine when added to brachial plexus block significantly

**Table 1:** Patient demographic data

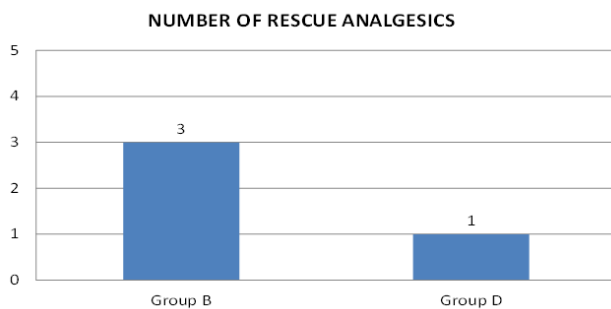
Data	Group B	Group D	P value
Age (months)	5.35±3.09	7.28±1.66	0.764
Sex (M/F)	32/8	29/11	0.613
Weight(kilogram)	5.06±4.45	6.33±5.21	0.319
ASA class I/II	40/0	40/0	-
Duration of surgery (minutes)	40.34 ±5.05	38.82±9.22	0.662

Group B: Bupivacaine ; Group D: Dexmedetomidine

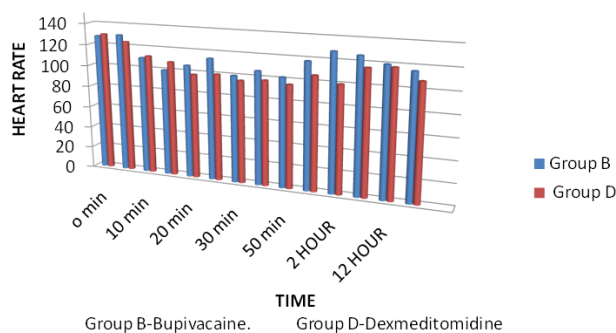
**Table 2:** Comparison of analgesic requirements

Parameter	Group B	Group D	P value
Number of patients requiring rescue analgesia	36	8	0.025*
Duration of analgesia (mean ± SD) (minutes)	496±28.26	733±49.15	0.001*

Group B: Bupivacaine group; Group D: Dexmedetomidine group; SD: deviation;\* : significant

**Fig. 1:** Number of rescue analgesics

Group B: Bupivacaine group, Group D: Dexmedetomidine Group

**Fig. 2:** Intraoperative and postoperative Heart rate

prolonged the duration of analgesia by at least 63% or from 7.5h to 11.9h.<sup>14</sup> However, studies evaluating the effectiveness of dexmedetomidine in peripheral nerve block in children are not many. Therefore we conducted this study to evaluate the effect of 0.5 µg/kg dexmedetomidine in infra - orbital nerve block in children undergoing cleft lip repair surgery. The mechanism of action of dexmedetomidine include central analgesia, vasoconstriction, and anti-inflammatory effects.<sup>15</sup> However,

none of these mechanisms can explain fully the synergistic effect of α<sub>2</sub>-adrenoceptor agonists when added to a local anaesthetic in peripheral nerve blocks. Possible mechanisms explained by few studies were that dexmedetomidine induces vasoconstriction through an action on α<sub>2</sub> adrenoceptors or it produces analgesia peripherally by reducing nor - epinephrine release and increasing the potassium conduction in C and A-delta neurons responsible for passage of pain stimulus, whereas it produces analgesia and sedation centrally by inhibition of substance P release in the nociceptive pathway at the level of the dorsal root ganglia and locus coeruleus.<sup>16–18</sup>

Our study results showed that 0.5µg/kg dexmedetomidine added to bupivacaine increased the duration of analgesia by 3.95 hours when compared to plain bupivacaine (Group B: 496±28.26;Group D:733±49.15). The number of patients who requested for rescue analgesics were less in Group D (20 %) as compared to Group B (90%). This was in consistent with the results reported by Karan et al.,<sup>19</sup> The authors used dexmedetomidine at a dose of 1 µg /kg added to ropivacaine in ultrasound-guided ilioinguinal nerve block. They reported that the duration of analgesia in group receiving dexmedetomidine–ropivacaine mixture was 16.17 ± 0.77 h, and in group receiving plain ropivacaine was 6.9 ± 1.01 h which was statistically significant. They also reported that in dexmedetomidine group only 16.67% of patients required rescue analgesic when compared to plain ropivacaine group. Similarly El-Sayed and El Motlb<sup>20</sup> conducted a study wherein the authors compared dexmedetomidine and dexamethasone as adjuvants to local anaesthetic. They reported that the time of first request of analgesic was 20% longer (P=0.0001) in dexmedetomidine group (689 ± 58.2) compared to dexamethasone group (546 ± 41.6). Obayah et al.,<sup>21</sup> also in their study reported that when dexmedetomidine is used at a dose of 1µg/kg with bupivacaine increased the duration of analgesia up to 21±24 h. In a study by Mangal et al., 1µg/kg of dexmedetomidine with ropivacaine in ultrasound guided

supraclavicular block showed significant prolongation of analgesia ( $704.77 \pm 178.414$  min).<sup>22</sup> In consistent with these studies various other studies also concluded that use of  $1\mu\text{g}/\text{kg}$  dexmedetomidine produced effective and significantly prolonged analgesia.<sup>23,24</sup>

In our study, we also recorded the heart rate intraoperatively and postoperatively. There was no significant difference between the groups. The heart rate remained on lower side in dexmedetomidine group but none of the patients required intervention. The sedation scores were equal in both groups. In dexmedetomidine group patients were comfortable and easily arousable but was statistically not significant.

## 5. Conclusion

Addition of  $0.5\mu\text{g}/\text{kg}$  of dexmedetomidine as to bupivacaine for infra- orbital nerve block effectively increased the duration of analgesia without any intraoperative and postoperative adverse events.

## 6. Source of funding

None.

## 7. Conflict of interest

None.

## References

- Lee SJ, Ralston HJ, Drey EA, Partridge JC, Rosen MA. Fetal pain: A systematic multidisciplinary review of the evidence. *JAMA*. 2005;294:947–954.
- Tremlett M. Anaesthesia for cleft lip and palate surgery. *Curr Anaesth Crit Care*. 2004;15:309–316.
- Mayer MN, Frot C, Barrier G. Anaesthesia for primary repair of cleft lip and palate. *Paediatric Anaesth*. 1993;3:55.
- Doyle E, Hudson I. Anaesthesia for primary repair of cleft lip and cleft palate: a review of 244 procedures. *Paediatric Anaesth*. 1992;2:139–145.
- Jöhr M. Regional anaesthesia in neonates, infants and children: An educational review. *Eur J Anaesthesiol*. 2015;32:289–297.
- Mangal V, Mistry T, Sharma G, Kazim M, Ahuja N, Kulshrestha A. Effects of dexmedetomidine as an adjuvant to ropivacaine in ultrasound-guided supraclavicular brachial plexus block: A prospective, randomized, double-blind study. *J Anaesthesiol Clin Pharmacol*. 2018;34:357–361.
- Merkel SI, Lewis VT, Shayevitz JR, Malviya S. The FLACC: A behavioral scale for scoring postoperative pain in young children. *Pediatr Nurs*. 1997;23:293–297.
- Sessler CN, Gosnell MS, Grap MJ, Brophy GM, Neal O, et al. The Richmond agitation-sedation scale: Validity and reliability in adult intensive care unit patients. *Am J Respir Crit Care Med*. 2002;166:1338–1344.
- Ammar AS, Mahmoud KM. Ultrasound-guided single injection infraclavicular brachial plexus block using bupivacaine alone or combined with dexmedetomidine for pain control in upper limb surgery: A prospective randomized controlled trial. *Saudi J Anaesth*. 2012;6:109–114.
- Esmaglu A, Yegenoglu F, Akin A, Turk CY. Dexmedetomidine added to levobupivacaine prolongs axillary brachial plexus block. *Anesth Analg*. 2010;111:1548–1551.
- Kaygusuz K, Kol IO, Duger C, Gursoy S, Ozturk H, Kayacan U. Effects of adding dexmedetomidine to levobupivacaine in axillary brachial plexus block. *Curr Ther Res Clin Exp*. 2012;73:103–111.
- Agarwal S, Aggarwal R, Gupta P. Dexmedetomidine prolongs the effect of bupivacaine in supraclavicular brachial plexus block. *J Anaesthesiol Clin Pharmacol*. 2014;30:36–40.
- Biswas S, Das RK, Mukherjee G, Ghose T. Dexmedetomidine adjuvant to levobupivacaine in supraclavicular brachial plexus block: A randomized double blind prospective study. *Ethiop J Health Sci*. 2014;24:203–208.
- Vorobeichik R, Brull A, Fw. Evidence basis for using perineural dexmedetomidine to enhance the quality of brachial plexus nerve blocks: a systematic review and meta-analysis of randomized controlled trials. *Br J Anaesth*. 2017;118(2):167–181.
- Iskandar H, Benard A, Ruel-Raymond J, C, Manaud G, B. The analgesic effect of interscalene block using clonidine as an analgesic for shoulder arthroscopy. *Anesth Analg*. 2003;96:260–262.
- Lee MJ, Koo DJ, Choi YS, Lee KC, Kim HY. Dexamethasone or dexmedetomidine as local anesthetic adjuvants for ultrasound-guided axillary brachial plexus blocks with nerve stimulation. *Korean J Pain*. 2016;29:29–33.
- Talke P, Lobo E, Brown R. Systemically administered alpha-2-agonist-induced peripheral vasoconstriction in humans. *Anesthesiol*. 2003;99:65–70.
- Yoshitomi T, Kohjitani A, Maeda S, Higuchi H, Shimada M, Miyawaki T. Dexmedetomidine enhances the local anesthetic action of lidocaine via an alpha-2A adrenoceptor. *Anesth Analg*. 2008;107:96–101.
- Karan D, Swaro S, Mahapatra PR, Banerjee A. Effect of Dexmedetomidine as an Adjuvant to Ropivacaine in Ilioinguinal-Iliohypogastric Nerve Blocks for Inguinal Hernia Repair in Pediatric Patients: A Randomized, Double-Blind. *Control Trial Anesth Essays Res*. 2018;12940:924–929.
- El-Emam ESM, Motlb EAE. Comparative evaluation of dexamethasone and dexmedetomidine as adjuvants for bupivacaine in ultrasound-Guided infraorbital nerve block for cleft lip repair: A prospective, randomized, Double-Blind study. *Anesth Essays Res*. 2019;13:354–358.
- Obayah GM, Refaie A, Aboushanab O, Ibraheem N, Abdelazees M. Addition of dexmedetomidine to bupivacaine for greater palatine nerve block prolongs postoperative analgesia after cleft palate repair. *Eur J Anaesthesiol*. 2010;27:280–284.
- Mangal V, Mistry T, Sharma G, Kazim M, Ahuja N, Kulshrestha A. Effects of dexmedetomidine as an adjuvant to ropivacaine in ultrasound-guided supraclavicular brachial plexus block: A prospective, randomized, double-blind study. *J Anaesthesiol Clin Pharmacol*. 2018;34:357–361.
- Bharti N, Sardana DK, Bala I. The Analgesic Efficacy of Dexmedetomidine as an Adjunct to Local Anesthetics in Supraclavicular Brachial Plexus Block: A Randomized Controlled Trial. *Anesth Analg*. 2015;121:1655–1660.
- Hamed MA, Ghaber S, Reda A. Dexmedetomidine and fentanyl as an adjunct to bupivacaine 0.5% in supraclavicular nerve block: A randomized controlled study. *Anesth Essays Res*. 2018;12:475–479.

## Author biography

**R D Ravichandra** Assistant Professor

**G B Sumalatha** Assistant Professor

**Cite this article:** Ravichandra RD, Sumalatha GB. Dexmedetomidine as an adjuvant to infraorbital block in children undergoing cleft lip surgery – A clinical comparative study. *Indian J Clin Anaesth* 2020;7(1):12-15.