

## Patterns and incidence of temporal bone fractures

Sandeep Velicheti<sup>1\*</sup>, Rani Tadicherla<sup>2</sup>, Mahita Movva<sup>3</sup>, Chandrasekhar Kondragunta<sup>4</sup>, Deepthi. G<sup>5</sup>

<sup>1</sup>Associate Professor, <sup>2,3,5</sup>Post Graduate, <sup>4</sup>Professor and HOD, Dept. of Radiodiagnosis, <sup>1-5</sup>DR.PSIMS & RF, Gannavaram, Andhra Pradesh, India

**\*Corresponding Author: Sandeep Velicheti**

Email: sandeepvel@gmail.com

### Abstract

**Introduction:** Temporal bone has a complex anatomy, divided into five bony divisions, which include squamous part, petrous bone, tympanic part, mastoid process, and styloid process. This contains cranial nerves V, VI, VII, and VIII and vascular structures such as the internal carotid and middle meningeal arteries, the sigmoid sinus, and the jugular bulb. It also harbors the sensorineural and membranous structures of the inner ear.

The most common cause of temporal bone fractures is high energy blunt head trauma. For the assessment of temporal fractures, cranial CT is a fundamental and initial diagnostic modality.

Complications of temporal bone fractures include facial nerve palsy, cerebrospinal fluid leakage, conductive hearing loss, sensorineural hearing loss, and vertigo. These fractures are divided into longitudinal and transverse based on whether the fracture line is passing parallel to or perpendicular to petrous bone respectively.

**Materials and Methods:** This was a cross-sectional study done at Dr. PSIMS & RF, Gannavaram, Andhra Pradesh. The study period was between January 2015 to December 2018, done on Siemens 16 Slice CT machine with the patients' age ranging from 18 to 70 years who underwent CT brain in view of Road traffic accidents.

**Results:** Among the total number of 30 patients, we have divided into combined fractures of various parts and isolated fractures of various parts. Isolated petrous fracture seen in 3 cases, squamous in 10 and mastoid in 5 patients, among the fractures, isolated squamous (58.8%) is the most common one seen. In thirteen cases (43.3%) combined fractures of at least two parts seen, among the various combinations seen the most common one is squamous – mastoid 7(50%). Among the total number of cases, facial nerve canal is involved in 7(23%) cases, out of which clinically 4(57.1%) cases presented with facial palsy. Carotid canal is involved in 3(10%) cases, pneumocephalus secondary to mastoid fracture in 6(20%) cases. Hemomastoideum is a common accompaniment in temporal bone fractures almost seen in 18(60%) cases, hemotympanum is seen in 14 cases. In one case, there is bilateral temporal bone fractures with severe injuries. Cochlear & semicircular canal involvement is seen in one among the total number of patients. Among the 30 cases, petrous temporal bone fracture seen in 10 cases, out of which longitudinal fractures seen in 8 cases (10%), mixed fracture is seen in 1 case and transverse fracture in 1 case.

**Keywords:** Temporal bone, Longitudinal fracture, Transverse fracture, Facial nerve injury, Ossicle injury.

### Introduction

Temporal bone has a complex anatomy, divided into five bony divisions, which include squamous part, petrous bone, tympanic part, mastoid process, and styloid process. It contains cranial nerves V, VI, VII, and VIII and vascular structures such as internal carotid and middle meningeal arteries, the sigmoid sinus, and the jugular bulb. It also harbors the sensorineural and membranous structures of the inner ear. The mechanism of injury in most temporal bone fractures is blunt head trauma. The clinical complications include hearing loss, vestibular

dysfunction symptoms, fistula formation, CSF otorrhea, paralysis of the facial nerve, and carotid or jugular injuries.<sup>1</sup>

It is important to identify the pattern of injury, and it is more important to give information to clinician about important structural injuries.

Cranial CT is a fundamental and initial diagnostic modality in patients presenting with polytrauma. In cases of necessity, dedicated MDCT should be considered for the temporal bone.<sup>2</sup>

### Materials and Methods

The present study was a cross-sectional study done at Dr. PSIMS & RF, Gannavaram, Andhra Pradesh. The study period was between January 2015 to December 2018, done on Siemens 16 Slice CT machine. The patients' age range is from 18 to 70 years who underwent CT brain in view of road traffic accidents.

### Imaging protocol

CT examination of the brain is done in an axial plane from base to vertex. In all the patients, we have done dedicated bone protocol reconstruction techniques, which are 1.2mm thick to visualize finer details like facial nerve course. In cases of significant temporal bone fractures, additional HRCT protocol was done later.

### Image analysis

The images were reviewed, and the fracture lines were identified and classified. Complications of temporal bone fractures were identified. The results were tabulated and evaluated by Microsoft excel.

### Results

This study included 30 subjects out of which 28 were male, and 2 were female patients. The youngest age of temporal bone fractures in this study was 18 years; the oldest age was 70 years, and mean age was 44 years.

Retrospective CT bone window of temporal bone fractures evaluated in this study revealed the following

Among the total number of 30 patients evaluated, there was bilateral involvement in two cases with severe head injury. The types of fractures involved are depicted in Table 1.

**Table 1**

Total number of fractures	32	
Isolated fractures	18	56.25%
Combined fractures	14	43.75%

Isolated type of fractures involving various parts of the temporal bone is depicted in table 2. Among them, isolated squamous (55.55%) is the most common one seen.

**Table 2**

Isolated fractures	18	
Mastoid	5	27.77%
Squamous	10	55.55%
Petrous	3	16.66%

Fourteen cases (43.75%) showed combined fractures of at least two parts seen as depicted in table 3. Among the various combinations seen, the most common one is squamous – mastoid 7(50%).

**Table 3**

Combined fractures	14	
S,M,P	3	21.42%
S, M	7	50%
S, P	2	14.28%
M, P	2	14.28%

S – Squamous, P - Petrous, M – Mastoid

Among the 30 cases, petrous temporal bone fractures are seen in 10 cases, and they are further classified based on the fracture line to the long axis of the petrous bone. The types of fractures are depicted in table 4 and the corresponding images in Figures 1 and 2.

**Table 4**

Total petrous fractures isolated (3) + combined (7)	n = 10	
Longitudinal fractures	8	80%
Transverse fractures	1	10%
Both transverse & longitudinal (Mixed)	1	10%

**Table 5**

Total number of cases	30	
Hemomastoideum	18	60%
Hemotympanum	14	46.66%
Pneumocephalus	06	20%
Facial canal fracture	07	23.33%
Carotid canal fracture	03	10%
Cochlea & vestibule involvement	01	3.33%

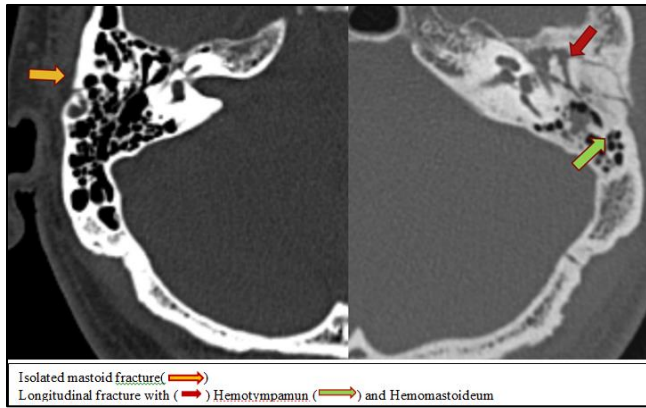


Fig. 1

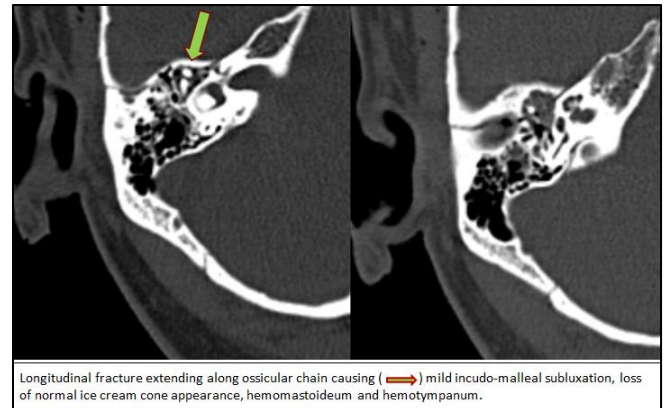


Fig. 4

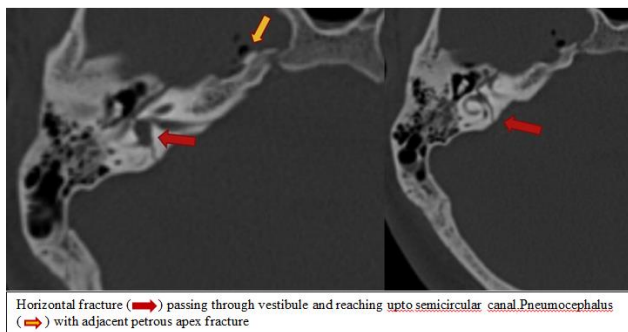


Fig. 2

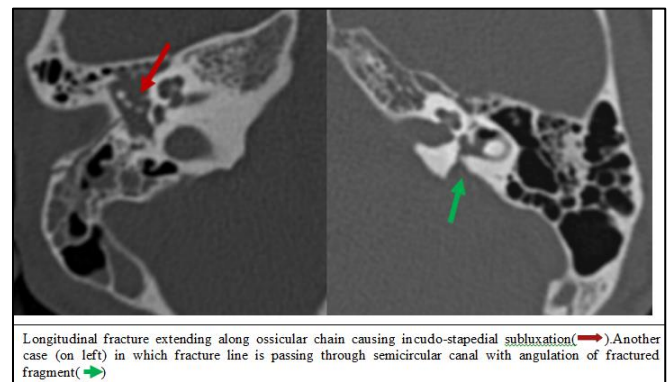


Fig. 5

The involvement of various parts of the temporal bone is depicted in Table 5. Vestibule & semicircular canal involvement is seen in two cases among the total number of patients, which is shown in figure 2. The two cases of transverse fractures showed otic capsule involvement. Out of 30 cases, facial nerve canal is involved in 7 (23.3%) cases, out of which clinically 4 (57.1%) cases presented with facial palsy. Carotid canal is involved in 3 (10%) cases. (Fig. 3).

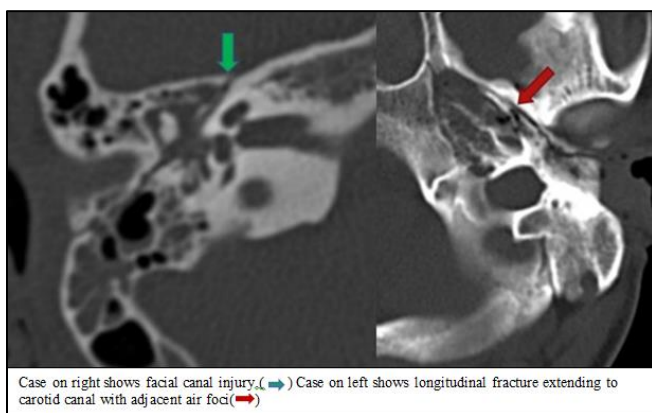


Fig. 3

### Discussion

Temporal bone fractures result from blunt head trauma.<sup>3</sup> Temporal bone fractures require an ample amount of force; hence, other clinically significant injuries mask the temporal bone injury initially.<sup>4</sup> Temporal bone injury is present in 14-22% of patients with skull fractures.<sup>5</sup> There is relatively low metabolic activity in the bone of otic capsule, which was thought to be responsible for lower degrees of bone healing in temporal bone than normal.<sup>6</sup>

Traditionally temporal bone fractures are classified based on their relationship with long axis of petrous portion of temporal bone into longitudinal and transverse. The initial classification of temporal bone fractures was done by Ulrich.<sup>7</sup> According to previous literature, 70-90% of temporal bone fractures are longitudinal, 10-30% are transverse.<sup>8</sup> In our study, we have divided fractures into longitudinal and transverse only if fractures are involving the petrous bone. Longitudinal fractures lie parallel to the petrous bone. We have 8 cases of longitudinal fractures in our study.

They are commonly associated with squamous temporal and parietal bone fractures.<sup>9</sup> The involvement of the otic capsule is uncommon because the fracture line passes away from it. But ossicular chain injury, tympanic membrane rupture, blood collection in the tympanic cavity, and conductive hearing loss are common. Facial nerve injury is also uncommon.<sup>3</sup>

Transverse fractures typically result from anterior or posterior forces, or it is associated with craniovertebral junction injuries.<sup>3</sup> The fracture line usually starts in the vicinity of jugular foramen and traverses perpendicular to the petrous bone long axis. Sensorineural hearing loss is more common in transverse fractures due to injury to labyrinthine structures and cochlear nerve. Perilymphatic fistula formation is another complication due to stapes footplate injury.<sup>10</sup> We did not find any cases of fistula formation in our study. Facial nerve palsy is more common in transverse fractures, and usually, it is complete.<sup>11</sup> There was otic capsule involvement in our study in the case of transverse fracture.

Many temporal bone fractures contain both transverse and longitudinal components. This is called mixed temporal bone fracture. We have encountered 1 case of mixed fracture.

In mixed temporal bone fractures, we don't classify as longitudinal or transverse as they contain both elements. These fractures frequently involve otic capsule, which results in sensorineural hearing loss.<sup>12</sup> It is also associated with conductive deafness due to fractures of the ossicular chain. There was otic capsule involvement in our case of mixed fracture. Recent studies suggest prognostic value and practicality of the classification does not necessarily correlate with clinical findings and patient outcome.<sup>13</sup>

Based on the classification done by Ishman and Friedland,<sup>14</sup> fractures were divided into petrous and non-petrous types. Petrous apex and otic capsule fractures are included under petrous fractures, while those involving middle ear and mastoid are included under non-petrous type. Petrous fractures have more complications compared to non-petrous fractures, i.e., they are more likely to develop facial injury and CSF leak. In our study, we encountered 10 cases of petrous fractures.

A new classification system by Kelly and Tami<sup>15</sup> divides fractures into otic capsule sparing and violating types, which is thought to have better clinical correlation and outcome.<sup>16</sup> This classification system is helpful to anticipate facial nerve injury and CSF leak.<sup>17</sup>

Recognition of external auditory canal injury is important.<sup>18</sup> We have encountered 1 case of external auditory canal involvement.

Ossicular dislocation is common than frank fractures.<sup>19</sup> Incus has minimal support, hence prone for displacement.<sup>20</sup> Incudostapedial joint separation is more common among all.<sup>10</sup> We have seen 2 fractures with ossicular involvement (Fig. 4 and 5).

If the carotid canal is fractured, there could be injuries pertaining to this in the form of dissection, pseudoaneurysm, and transection.<sup>21</sup> CT angiography should be performed in fractures involving the carotid canal. Our study showed carotid canal involvement in 3(10%) cases. No CT angiography performed as they don't have neurological deficits.

The general incidence of facial nerve injury is 7% in temporal bone fractures, and most commonly, these occur at the labyrinthine segment.<sup>8</sup> The injury could cause contusion of the nerve, hematoma, or edema of nerve sheath, partial or complete nerve transection.<sup>11</sup> Patients who have significant facial nerve injury will present with immediate post-traumatic palsy. In our study facial nerve canal is involved in 7(23.3%) cases, which is significantly higher, out of which clinically 4(57.1%) cases presented with facial palsy.

The fractures may directly injure cochlea or its nerve leading to sensory hearing loss. Vertigo is a common symptom after temporal bone trauma. It could be due to direct damage to the vestibule or nerve or sometimes even aqueduct. Injury to the otic capsule may lead to perilymphatic fistula. Trauma to semicircular canals may result in vertigo and should be evaluated carefully. Vestibule & semicircular canal involvement is seen in two cases in our study.

Temporal bone fractures may be unseen sometimes on initial imaging studies. Opacification of mastoid air cells with blood density, external auditory canal, hemotympanum, air-fluid level with blood density in the sphenoid sinus, finding even a small pocket of pneumocephalus adjacent to the temporal

bone, air in the adjacent soft tissues all may indicate unseen temporal bone fractures.<sup>1</sup>

Dividing fractures in the traditional classification system is fine, but while reporting otic capsule sparing or involving method of classification may be clinically more relevant. Identification of injury to the critical structures is important than classifying the fractures alone.

## Conclusion

Temporal bone fractures occur as a result of head trauma. High resolution CT sequences are required for better visualization of smaller structures. In our study, longitudinal type of fractures is common. However, identifying complications of fractures like ossicular involvement, facial nerve injury, otic capsule injuries are more clinically important.

## Source of Funding

None.

## Conflict of Interest

None.

## References

- Zayas OJ, Feliciano YZ, Hadley CR, Gomez AA, Vidal JA. Temporal bone trauma and the role of multidetector CT in the emergency department. *Radio Graphics* 2011;31:1741-45.
- Juliano AF, Ginat DT, Moonis G. Imaging review of the temporal bone: part II—traumatic, postoperative, and noninflammatory nonneoplastic conditions. *Radiol* 2015;276(3):655-72.
- Cannon CR, Jahrsdoerfer RA. Temporal bone fractures: review of 90 cases. *Arch Otolaryngol* 1983;109(5):285-8.
- Travis LW, Stalnakier RL, Melvin JW. Impact trauma of the human temporal bone. *J Trauma* 1977;17(10):761-6.
- Brodie HA, Thompson TC. Management of complications from 820 temporal bone fractures. *Am J Otol* 1997;18(2):188-97.
- Schuknecht H. Pathology of the ear. 2nd ed. Philadelphia, Pa: Lea & Febiger, 1993.
- Ulrich K. Verletzungen des Gehorlorgans bei Schadelbasisfrakturen (Ein Histologisch und Klinische Studie). *Acta Otolaryngol* 1926;6:1-150.
- Swartz JD. Trauma. In: Swartz JD, Harnsberger HR, eds. *Imaging of the temporal bone*. 3rd ed. New York, NY: Thieme, 1997;318-44.
- Avrahami E, Chen Z, Solomon A. Modern high resolution computed tomography (CT) diagnosis of longitudinal fractures of the petrous bone. *Neuroradiol* 1988;30(2):166-8.
- Schubiger O, Valavanis A, Stuckmann G, Antonucci F. Temporal bone fractures and their complications. Examination with high resolution CT. *Neuroradiol* 1986;28(2):93-9.
- Fisch U. Facial paralysis in fractures of the petrous bone. *Laryngoscope* 1974;84(12):2141-54.
- McHugh HE. The surgical treatment of facial paralysis and traumatic conductive deafness in fractures of the temporal bone. *Ann Otol Rhinol Laryngol* 1959;68:855-89.
- Yanagihara N, Murakami S, Nishihara S. Temporal bone fractures inducing facial nerve paralysis: a new classification and its clinical significance. *Ear Nose Throat J* 1997;76(2):79-80, 83-86.
- Ishman SL, Friedland DR. Temporal bone fractures: traditional classification and clinical relevance. *Laryngoscope* 2004;114(10):1734-41.
- Kelly K, Tami T. Temporal bone and skull base trauma. In: Jackler R, Brackmann D, eds. *Neurology*. St Louis, Mo: Mosby, 1994; 1127.
- Brodie HA, Thompson TC. Management of complications from 820 temporal bone fractures. *Am J Otol* 1997;18(2):188-97.
- Little SC, Kesser BW. Radiographic classification of temporal bone fractures: clinical predictability using a new system. *Arch Otolaryngol Head Neck Surg* 2006;132(12):1300-4.
- Gean AD. Scalp and skull injury. In: Gean AD, ed. *Imaging of head trauma*. New York, NY: Raven, 1994;51-73.
- Meriot P, Veillon F, Garcia JF. CT appearances of ossicular injuries. *Radio Graphics* 1997;17(6):1445-54.
- Swartz JD. Temporal bone trauma. In: Som PM, Curtin HD, eds. *Head and neck imaging*. 3rd ed. St Louis, Mo: Mosby, 1995;1425-31.
- Resnick DK, Subach BR, Marion DW. The significance of carotid canal involvement in basilar cranial fracture. *Neurosurg* 1997;40(6):1177-81.

**How to cite this article:** Velicheti S, Tadicherla R, Movva M, Kondragunta C, Deepthi G, Patterns and incidence of temporal bone fractures. *Int J Maxillofac Imaging* 2019;5(4):84-8.