



## Original Research Article

## Evaluation of functional outcome of microsurgical management of lumbar canal stenosis

Santosh J Mangshetty<sup>1</sup>, Abhinandan Gangannavar<sup>2,\*</sup>, Satish Rudrappa<sup>3</sup>, Swaroop Gopal<sup>3</sup>

<sup>1</sup>Dept. of Neurosurgeon, Mangshetty Neuro Clinic, Kalaburagi, Karnataka, India

<sup>2</sup>Dept. of Neurosurgeon, Sparsh Hospital, Bengaluru, Karnataka, India

<sup>3</sup>Dept. of Neurosurgeon, Sakara World Hospital, Bengaluru, Karnataka, India



## ARTICLE INFO

## Article history:

Received 30-11-2019

Accepted 10-12-2019

Available online 14-12-2019

## Keywords:

Lumbar Canal Stenosis

ODI Scores

VAS scale

Neurogenic Claudication

Laminotomy

## ABSTRACT

**Introduction and Objectives:** The present study was undertaken with the objective to study the functional outcome with Oswestry Disability Index and VAS in patients with degenerative lumbar canal stenosis who underwent unilateral laminotomy and bilateral decompression of the canal.

**Materials and Methods :** The cases were the patients who underwent microsurgical treatment for degenerative lumbar canal stenosis, between the age group of 40 to 60 during 2008 – 2010 were taken for the study. Patients with a history of low back pain, neurogenic claudication, radicular pain with single level canal stenosis and without spinal instability were included in the study. The patients underwent a thorough preoperative clinical and radiological examination at the department. VAS- Visual Analog Scale and Oswestry Disability Index and Neck Disability Index (0-10 scale) were used to assess the functional outcome.

**Results:** 45 patients were included in our study. 42.2% were between 60-70 yrs. Males were more compared to females, 82 % people presented with neurogenic claudication pain and the pain was bilateral in 70 %. The duration was ranging from 6 months to 1 year. The functional outcome analyzed with VAS and ODI which showed progressive improvement in the values at the end of 1 year follow up the difference showed a p- value of < 0.001 which was statistically significant, during the follow-up none of the patients had recurrence of the symptoms and did not develop any spinal instability.

**Conclusion:** The functional outcome measured with VAS and ODI showed strongly significant as well as analysis showed immediate improvement with bilateral symptoms, canal stenosis at the L4-5 level. However good results noted in follow -up with a female who was having bilateral symptoms and stenosis at L5 S1 level.

© 2019 Published by Innovative Publication. This is an open access article under the CC BY-NC-ND license (<https://creativecommons.org/licenses/by/4.0/>)

### 1. Introduction

Spinal stenosis is a narrowing of the spinal canal by a combination of bone and soft tissues, which causes mechanical compression of spinal nerve roots. The compression of these nerve roots can be asymptomatic. If symptomatic results in weakness in limbs, gait disturbances, bowel or bladder dysfunction, motor and sensory changes, radicular pain, and neurogenic claudication. Narrowing

of the central canal, lateral recess or foramen thus leads to compression of the neural elements in those locations. Neural compression in the central canal leads to low back pain radiating into both legs and neurogenic claudication defined as intermittent pain or paresthesia in the legs brought on by walking and standing which is relieved by sitting or lying down. The first medical report of spinal stenosis occurred in the 1800.<sup>1-4</sup>

First described by Antoine Portal in 1803,<sup>5,6</sup> he postulated that back and leg pain could be caused by bone impingement on the nerves. In 1893, Lane of

\* Corresponding author.

E-mail address: [intellec19@yahoo.com](mailto:intellec19@yahoo.com) (A. Gangannavar).

England did a decompressive laminectomy to relieve a woman of caudaequina syndrome caused by spinal stenosis. Minimally invasive surgery using microsurgical techniques are commonly performed for lumbar canal stenosis over the last decade. In these procedures, the maximal preservation of structural components such as midline structures, facet joints, and paravertebral muscles are needed to prevent postoperative instability. Among all decompressive procedures, good results have been achieved using bilateral laminotomy and unilateral laminotomy with bilateral decompression.<sup>3,7,8</sup>

## 2. Objective

To study the functional outcome with Oswestry Disability Index and VAS in patients with degenerative lumbar canal stenosis who underwent unilateral laminotomy and bilateral decompression of the canal.

## 3. Materials and Methods

Patients with degenerative lumbar canal stenosis, between the age group of 40 to 60 who underwent unilateral and bilateral decompression at our institution between 2008 – 2010 were taken for the study. Patients with low back pain, neurogenic claudication, radicular pain with single level canal stenosis and without spinal instability were included in the study. Patients with lumbar instability (shown in dynamic lumbar X-ray), patients with vascular claudication and associated medical co-morbidities were excluded.

**Clinical evaluation:** The patients underwent a thorough preoperative clinical and radiological examination at the department. VAS- Visual Analogue Scale 1- 10 and *Oswestry Disability Index and Neck Disability Index* (0-10 scale) were used to assess the functional outcome. 0-4 score was considered as No disability, 5-14 score as Mild disability, 15-24 score as Moderate disability, 25-34 score as Severe disability and > 35 score as Complete disability.

Score interpretation of the Oswestry lbp disability questionnaire

The ODI is a validated disease-specific instrument for the assessment of spinal disorders and consists of a 10-item questionnaire with 6 available responses for each item. The total score ranges from 0 to 100, in which 100 indicates the most severe disability. The items measured are the intensity of pain, personal self-care, social life, sex life, and traveling ability as well as the ability to lift, walk, sit, stand, and sleep. For each item, 0 indicates normal function and 5 indicates the highest level of dysfunction. The sum of the 10 items multiplied by their respective estimates constitutes the ODI score (0–100). The interpretation of ODI score is shown in Table 2. This can be evaluated by careful observation of the patient during the medical examination.

**Table 1:** Interpretation of scores

<b>0% to 20%: minimal disability</b>	The patient can cope with most living activities. Usually, no treatment is indicated apart from advice on lifting sitting and exercise.
<b>21%-40%: moderate disability</b>	The patient experiences more pain and difficulty with sitting, lifting and standing. Travel and social life are more difficult and they may be disabled from work. Personal care, sexual activity, and sleeping are not grossly affected and the patient can usually be managed by conservative means.
<b>41%-60%: severe disability</b>	Pain remains the main problem in this group but activities of daily living are affected. These patients require a detailed investigation.
<b>61%-80%: crippled</b>	Back pain impinges on all aspects of the patient's life. Positive intervention is required.
<b>81%-100%</b>	These patients are either bed-bound or exaggerating their symptoms.

### 3.1. Surgical procedure employed

The patient was placed prone in marked flexion and a standard intervertebral paraspinous process approach was performed. After the positioning of a standard Caspar retractor, the procedure was performed microsurgically, using a surgical microscope that provides constant clear monitoring of anatomical structures. A small interlaminotomy and removal of the LF are performed with the aid of a microdrill and Kerrison rongeurs, preserving the facet joints and exposing the dural sac.

The superior lamina exceeding the midline of the attachment of the spinous process and facet joint were partially thinned using a microdrill in a V shape to allow further removal of the remaining bone using a 2-mm Kerrison punch. The Kerrison tip was forced beneath the lamina, starting from the midline where the Ligamentum flavum attachment is very loose. The laminar thinning was performed, leaving the Ligamentum flavum beneath intact to protect the dural sac. Bone thinning was extended until the upper border of the Ligamentum flavum and the dural sac was visible. The Ligamentum flavum was elevated using dissectors creating a neat cleavage plane with the dural layer. At this point, with the dural layer clearly in view, bone and the Ligamentum flavum were removed in a standard fashion, reaching the midline and decompressing the ipsilateral radicular recess. Finally, the operative microscope was gradually tilted toward the opposite side at

the proper angle, thus allowing as much of the contralateral Ligamentum flavum as possible to be removed using the small Kerrison rongeurs. Part of the spinous process was further drilled, and the inner portion of the facet joint was undercut until the contralateral spinal nerve root and dural border were seen. The narrowing of the spinal canal mostly caused by the degenerative changes affecting the Ligamentum flavum and the facet joints. The facet joints, the pedicle, and the entire posterior intrasupraspinous ligament complex were preserved. The same procedure was performed at multiple levels.

### 3.2. Statistical Methods

Descriptive and inferential statistical analysis has been carried out in the present study. Results on continuous measurements were presented on Mean  $\pm$  SD (Min-Max) and results on categorical measurements were presented in Number (%). Significance is assessed at 5 % level of significance. P-value  $\pm$  0.05 was taken as statistically significant. Statistical software: The Statistical software namely SAS 9.2, SPSS 15.0, Stata 10.1, MedCalc 9.0.1, Systat 12.0 and R environment ver.2.11.1 were used for the analysis of the data and Microsoft Word and Excel have been used to generate graphs, tables etc.

## 4. Results

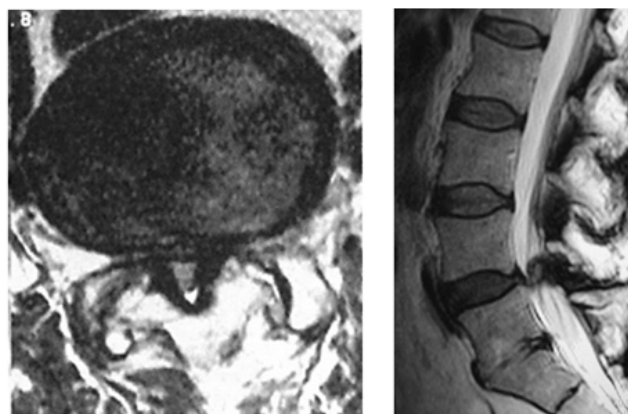
The study was carried during 2008-2010. This was an observational clinical study carried among 45 patients who underwent bilateral decompression with a unilateral laminotomy. As per the age distribution, the mean age of the patients was  $61.31 \pm 9.30$  yrs. The majority of them being in the age group 61-70 years (42.2%) Male (68.9%) were more commonly affected as compared to females. Neurogenic Claudication (82.2%) was a more common presentation among the cases. The majority of the patients (86.7%) completed 6-12 months of follow up period. (Table 2).

The Oswestry Index showed significant improvement post operatively. Preoperatively the mean score on the Oswestry index was  $23.13 \pm 2.13$  which indicates moderate disability was statistically improved postoperatively. The Oswestry index at 3 month, 6 months and 1 year were  $15.13 \pm 2.68$ ,  $12.71 \pm 2.33$  and  $11.93 \pm 2.56$  respectively the results were statistically significant with P-value  $< 0.001$ . (Table 3) VAS score also showed a statistically significant improvement over a period of 1 year (P-value  $< 0.001$ ) (Table 3)

An illustrative case of 58-year-old female, presented with neurogenic claudication for 4 months. MRI L S spine done showed canal stenosis at L4- L5 level, she did not have lumbar instability. She underwent bilateral decompression with a unilateral laminotomy. (Image No.1)

**Table 2:** Sociodemographic, Clinical and radiological Profile of Patients

Characteristics	Variables	Percentage
Age	40-50	15.6
	51-60	26.7
	61-70	42.2
	71-80	15.6
Sex	Female	31.1
	Male	68.9
	LBA	8.9
Presentation	N. claudication	82.2
	Radicular pain	8.9
	Both	71.1
Radiation distribution	Left	8.9
	Right	20.0
	Duration (months) in patients studied	<6 months
	6-12 months	86.7
	>12 months	4.4



**Fig. 1:** MRI L S Spine axial and sagittal view

## 5. Discussion

Lumbar stenosis refers to any narrowing of spinal canal, nerve root canal or intervertebral foramen, resulting in highly variable signs and symptoms such as low back pain and radiating pain to lower extremities. Lumbar spinal stenosis is a common debilitating spinal disease in elderly patients and can significantly limit their quality of life. Stenosis of the lumbar canal is now the most common indication for surgery in patients over 60 years who are suffering from low back pain and leg pain with intermittent claudication. From pathophysiologic perspective, lumbar stenosis typically results from a complex degenerative process that leads to compression of neural elements from a combination of ligamentum hypertrophy, pre-existing congenital narrowing, intervertebral disc bulging or herniation and facet hypertrophy with arthropathy of capsule soft tissue. The treatment options are either operative or conservative. Conservative therapies may be helpful, but do not in most cases, result in long term improvement.

**Table 3:** Function outcome Evaluation using ODI and VAS Score

Tool	Characteristics	Min-Max	Mean ± SD	difference	t value	P value
ODI Evaluation	Baseline	20.00-28.00	23.13±2.13	-	-	-
	Post op 3 months	10.00-22.00	15.13±2.68	8.000	24.449	<0.001**
	Post op 6 months	10.00-20.00	12.71±2.33	10.422	26.131	<0.001**
VAS Score	Post op 1 year	10.00-24.00	11.93±2.56	11.200	25.262	<0.001**
	Baseline	6.00-10.00	7.82±1.01	-	-	-
	Post op 3 months	0.00-6.00	2.64±1.69	5.178	21.158	<0.001**
	Post op 6 months	0.00-3.00	0.96±0.90	6.867	45.447	<0.001**
	Post op 1 year	0.00-6.00	0.73±1.07	7.089	36.757	<0.001**

Controlled clinical studies comparing conservative and surgical treatment are rare and there are few reports on long term results.

Matsunaga et al reported that progressive spondylolisthesis was observed in 34% of non neurosurgically managed, Yoshida et al reported progression of slippage was 33.3% over 10 yrs follow up who were managed conservatively.<sup>9,10</sup> The Maine lumbar Spine study Group atlas and co-workers prospectively followed 119 patients over 4 years- Results are based on patient satisfaction assessment showed 70% surgically treated patients showed improvement versus 52% non surgically treated patients<sup>11</sup> Turner et al did a meta-analysis which concluded 64% of surgically treated patients had good result over midterm followup.<sup>12</sup> The SPORT study was the largest level I prospective randomized study that demonstrated the efficacy of operative treatment over nonoperative treatment for lumbar spinal stenosis at 2 years follows up. These findings are similar to our observation were the patients showed a significant improvement post-surgery within a year of follow up.

Atlas and colleagues assessed surgically and non surgically treated patients outcome at 1 year of 148 patients, 55% surgically versus 28% non surgically treated patients showed definitive improvement in their symptoms.<sup>13</sup> The maximum benefit of surgery was noted after 3 months of follow up. 2002 review by Benoist and 2005 Cochrane review by Gibson and Wendell concluded that there is Level I evidence regarding the efficacy of spinal stenosis surgery when compared to nonoperative treatment.<sup>14,15</sup> Both reviews included one randomized study that examined a small cohort of patients for 10 years following randomization to operative and non operative treatment after 4 years 50% of nonoperative patients had fair improvement compared to 80% of operative group had good results. Our results also have a similar findings were in patients showed a statistically significant improvement with 3 month of surgery.

When conservative measure fails, surgical methods are necessary and inevitable, the most common procedure is expansive laminectomy. Open decompressive laminectomy

is the gold standard for treatment of stable lumbar canal stenosis, the results of expansive laminectomy are satisfactory according to some authors like Epstein et al, Iguchi et al, Mardjetko et al and Jolles et al.<sup>16</sup> In expansive laminectomy entails an extensive resection of posterior spinal elements such as interspinous ligaments, supraspinous ligaments, spinous process, bilateral lamina, portion of facet joint with capsule and ligamentum flavum. In expansive laminectomy common complication is iatrogenic instability following laminectomy it also associated with a prolonged hospital stay, significant pain, blood loss, morbidity, prolonged recovery period and increased incidence of medical complications.

## 6. Conclusion

Unilateral laminotomy to achieve bilateral decompression provides an adequate and safe decompression of the spinal canal in patients with DLSS. Evaluation of follow-up data obtained in our study showed very favourable results for overall clinical improvement as well as a low rate of morbidity (no significant segmental instability requiring fusion procedures), This confirms the feasibility of this minimally invasive approach in elderly and younger the In our opinion, this is an effective and safe procedure in the treatment of DLSS.

## 7. Conflict of interest

None

## 8. Source of funding

None

## References

1. Kirkaldy-Willis WH, Wedge JH, Yong-Hing K. Pathology and pathogenesis of lumbar spondylolisthesis and stenosis. *Spine*. 1976;3:319–328.
2. Verbiest H. A radicular syndrome from developmental narrowing of the lumbar vertebral canal. *Clin Orthop Relat Res*. 2001;(384):3–9.

3. Palmer S, Turner R, Palmer R. Bilateral decompression of lumbar spinal stenosis involving a unilateral approach with microscope and tubular retractor system. *J Neurosurg.* 2002;97(2):213–217. Suppl.
4. Szpalski M, Gunzburg R. Lumbar spinal stenosis in the elderly: an overview. *Eur Spine J.* 2003;12:170–175.
5. Fujita T, Kostuik JP, Huckell CB, Sieber AN. Complications of spinal fusion in adult patients more than 60 years of age. *Orthop Clin North Am.* 1998;29:669–678.
6. Young S, Veerapen R, Laoire SAO. Relief of lumbar canal stenosis using multilevel subarticular fenestrations as an alternative to wide laminectomy: preliminary report. *Neurosurgery.* 1988;23:628–633. Manuscript.
7. Mslman AM, Cansever T. *2 et al J Neurosurgery spine.* 2012;16:68–76.
8. Botwin KP. -. *Phys Med Rehabil Clin N Am.* 2003;14:1–15.
9. Matsunaga S, Kosei I, Kyoji H. Nonsurgically managed patients with degenerative spondylolisthesis: a 10- to 18-year follow-up study. *J Neurosurg.* 2000;93(2):194–198.
10. Yamane T, Yoshida T, Mimatsu K. Early diagnosis of lumbar spondylolysis by MRI. *J Bone Joint Surg Br.* 1993;75(5):764–768.
11. Keller RB, Atlas SJ, Singer DE, Chapin AM, Mooney NA, et al. The Maine Lumbar Spine Study, Part I. Background and concepts. *Spine.* 1996;21(15):1769–1776.
12. Turner DT, Mcglanaghy E, Cuijpers P, Vander G, Karyotaki E, Macbeth A. A Meta-Analysis of Social Skills Training and Related Interventions for Psychosis. *Schizophr Bull.* 2018;44(3):475–491.
13. Benoist M. The natural history of lumbar degenerative spinal stenosis. *Joint and Bone Spine.* 2002;69:450–457.
14. Gibson JN, Waddel G. Surgery for degenerative lumbar spondylosis updated Cochrane review. *Spine.* 2005;30:2312–2320.
15. Mayer TG, Vanharanta H, Gatchel RJ, Mooney V, Barnes D, Judge L. Comparison of CT scan muscle measurements and isokinetic trunk strength in postoperative patients. *Spine.* 1989;14(1):33–36.
16. Epstein JA, Epstein BS, Rosenthal AD, Carras R, Lavine L. Sciatica caused by nerve root entrapment in the lateral recess: the superior facet syndrome. *J Neurosurg.* 1972;36(5):584–589.

### Author biography

**Santosh J Mangshetty** Consultant

**Abhinandan Gangannavar** Consultant

**Satish Rudrappa** Consultant

**Swaroop Gopal** Consultant

**Cite this article:** Mangshetty SJ, Gangannavar A, Rudrappa S, Gopal S. Evaluation of functional outcome of microsurgical management of lumbar canal stenosis. *Indian J Neurosci* 2019;5(4):241-245.