

## Socket shield technique for optimizing aesthetic results of immediate implants

Nour M Alshammari<sup>1\*</sup>, Ibrahim A Alhawiti<sup>2</sup>, Hassan Koshak<sup>3</sup>

<sup>1</sup>Resident, <sup>2</sup>Senior Registrar, <sup>3</sup>Consultant, <sup>2,3</sup>Dept. of Periodontics and Implant Dentistry, <sup>1</sup>Saudi Board of Periodontics Riyadh Elm University Riyadh, Kingdom of Saudi Arabia, <sup>2</sup>Tabuk Specialist Dental Center Ministry of Health Tabuk, Kingdom of Saudi Arabia, <sup>3</sup>Comprehensive Specialized Polyclinic, Ministry of Interior Security Forces Medical Services, Jeddah, Kingdom of Saudi Arabia

**\*Corresponding Author: Nour M Alshammari**

Email: [nour.alshammari@student.riyadh.edu.sa](mailto:nour.alshammari@student.riyadh.edu.sa)

### Abstract

Loss of alveolar bone may be attributed to various factors, such periodontal diseases, endodontic pathology, facial trauma, and traumatic tooth extraction. Different techniques such as ridge preservation procedures have been proposed to maintain the ridge dimension to a certain amount. However, applying these methods to extraction sockets could not completely preserve the coronal part of facial bone walls which were comprised almost entirely of bundle bone. The socket shield technique (SST) with immediate implant in esthetic zone provides a promising treatment to better manage these risks and preserve the post-extraction hard and soft tissues. This case report demonstrates the 3-year follow up of the treatment of non-restorable maxillary lateral incisor with the socket shield technique in conjunction with immediate implant placement.

**Keywords:** Socket-shield technique, Dental implant, Ridge preservation, Immediate implant, Alveolar ridge resorption, Buccal bone, Esthetic zone.

### Introduction

Tooth extraction followed by dimensional alterations in the residual alveolar ridge and its more pronounced in the buccal bone plate than the palatal. Bundle bone theory mean the presence of bundle bone is dependent on functional of periodontal fiber, when these fibers lost, bundle bone will resorb leading to ridge resorption.<sup>1</sup> There are a lot of techniques have been discussed in the literature to overcome the remodeling after tooth extraction, all techniques cannot prevent ridge alteration after extraction, also the placement of an immediate implant cannot prevent these alterations.<sup>2</sup> This hard and soft tissue alteration cause apical migration of soft tissue, resulting in collapse of the papilla and black triangles between the teeth.<sup>3</sup> To prevent this resorption, SST by Partial extraction technique was performed by preserving the bundle bone-periodontal fiber complex and it has demonstrated highly promising histological and clinical results to aesthetic implant placement<sup>3-9</sup> SST was first described in 2010 by Hurzeler et al. Their histologic study demonstrated new bone formation in the small gap between implant in contact with the tooth fragment and new cementum formed on the implant surface. They also presented clinical case report of SST by retaining the facial section of root intact and placing implant on the palatal aspect of that facial tooth section with immediate implant for 6 months follow up and concluded that this retained root section function like a shield and prevent the ridge from collapsing thus improving the aesthetics especially during implant in the aesthetic zone and in patients with high lip line.<sup>4</sup> Although the SST has been becoming more popular among clinicians all over the world in the past few years, only few documented clinical studies available and most of the case reports and series in the literature have less than 2 years follow up, so little is known about the results of this technique and long-term fate of buccal shield has not yet been completely clarified.

Aim of this case report is to demonstrate the 3-year follow up of the treatment of non- restorable maxillary lateral incisor using the SST in conjunction with immediate implant placement.

### Case Report

A 38-year-old non-smoker female patient with non-contributory medical history, presented to Department of Periodontology of Riyadh Elm University with non-restorable tooth #12. The preoperative clinical and radiographic assessment showed thin buccal bone plate (Fig. 1). After discussing the treatment options, benefits, possible complication and surgical procedure, patient signed an informed consent to do socket shield technique with immediate implant placement.

### Surgical Procedure

First, local anesthesia with infiltration (1 carpule of lidocaine 2% with epinephrine 1:100,000) was administered. The technique consists of sectioning the root of the tooth mesiodistally along its long axis with a long-tapered fissure diamond bur followed by conservative removal of palatal root portion using periotome and forceps without disturbing or mobilize the facial root portion and retaining it to the tooth socket to support the facial tissues. The retained facial portion was reduced to the level of alveolar ridge and thinned in a concave contour to 2mm. Then debridement any infective tissue remnants in the palatal wall of the tooth sockets. This retained root called socket shield. Consecutively ostectomy was performed to place immediate implant palatal to the retained portion. Thereafter Immediate implant (Nobel BioCare 3.5x13mm, Conical implant with Cover screw) was placed with cover screw and nonfunctioning provisional acrylic restoration (Fig. 2).

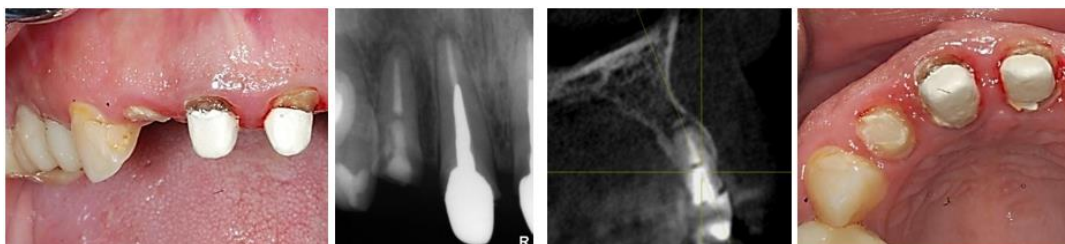


Fig. 1: Examination of tooth # 12

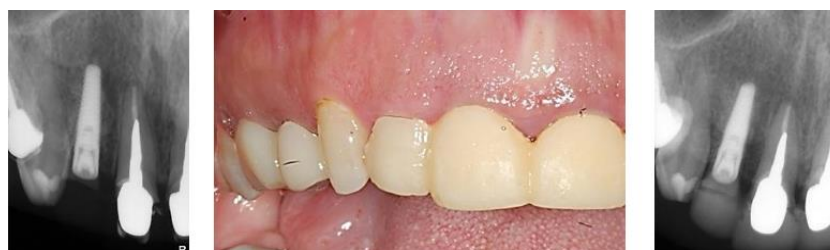
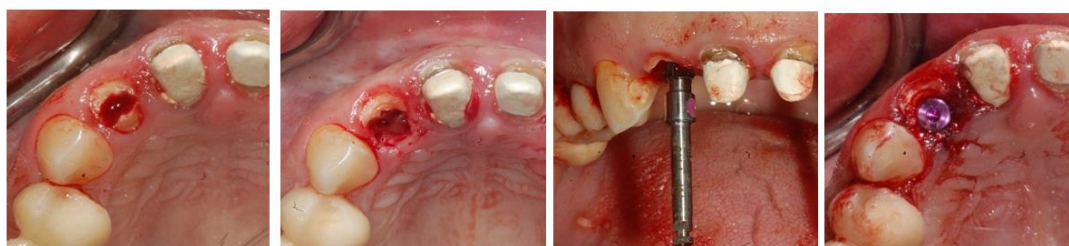
Fig. 2: Implant placement with provisional acrylic restoration

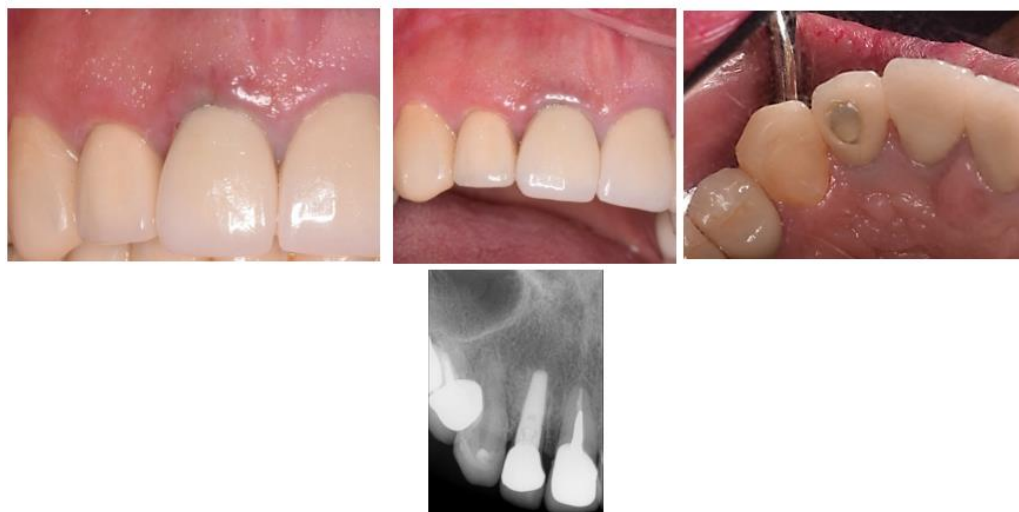

Fig. 3: Final restoration

For the postoperative instruction, patient was advised to rinse with 0.12% Chlorhexidine mouthwash two daily for two weeks. Nonsteroidal anti-inflammatory drugs (ibuprofen 400 mg four times daily for 3 days than as needed) and oral antibiotics (amoxicillin 500 mg three times daily for seven days) were prescribed after surgery.

Initial follow up after two weeks, then after 3 months final restoration by screw retained crown inserted (Fig. 3). At 6 months, 1, 2 and 3 years post loading follow up by radiographical assessment for evaluation bone remodeling

and clinical evaluation of soft tissue changes around implant, esthetically evaluated based on pink esthetic score.<sup>10</sup>

**Results**

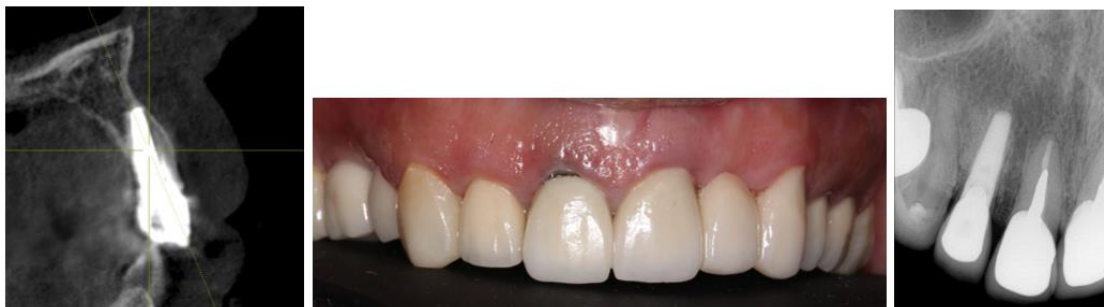In the present case report, all the follow up visits after implant placement showed uneventful postoperative healing with a pleasing esthetic result.

At the 3-year post loading follow up, absence of inflammation, bleeding on probing, erythema, swelling and suppuration was noted. Pink esthetic score was 12.

Healthy peri implant soft tissue without any probing depth greater than 3 mm in depth. Palpation of the buccal tissues didn't cause any subjective symptoms or reveal any sign of root displacement. No adverse events were reported by the patient and the implant was diagnosed as peri implant

health as classified by the 2017 world workshop for classification of peri-implant diseases and conditions.<sup>10</sup>

The clinical and radiographical assessment revealed, that retaining root fragment adjacent to the buccal crestal bone and placing an implant engaged to the palatal socket wall immediately are able to maintain the contour of the ridge without an interference with the osseointegration for 3 years post loading.<sup>11</sup>



**Fig. 4:** 3 years follow up

The clinical and radiographical assessment revealed, socket shield technique with immediate implant in #12 can maintain the contour of the ridge without an interference with the osseointegration for 3 years post loading.

## Discussion

In this case report, socket shield technique with immediate implant placement showed successful esthetic and functional treatment without complication up to 3 years postoperatively. Socket shield technique with immediate implant placement is a cost-effective procedure, less invasive and has short treatment duration but it's a technique-sensitive and the success require a precise case selection.<sup>4</sup> The past studies have been observed that retaining non-vital and vital root as technique to preserve alveolar ridge.<sup>12</sup> Moreover, Salama demonstrated that the root submergence technique maintains the natural periodontium in the pontic site, thereby completely preserving the alveolar bone and lead to aesthetic result.<sup>7</sup> Similar results were obtained in various recent studies that confirmed the effectiveness of socket shield technique in minimizing post extraction remodeling.<sup>3,6,8,13-15</sup> Baumer et al reported 5-years retrospective study treated by socket shield technique and they demonstrated that the average recession at the implant ( $-0.33 \pm 0.23\text{mm}$ ) was comparable to the adjacent teeth ( $-0.38 \pm 0.27\text{mm}$ ) and concluded that socket shield technique had high esthetic outcomes with effective preservation of facial tissue contours.<sup>16</sup> To this day, the maximum cases of socket shield technique reported is 250 cases and the follow up was 10 years, the authors reported a 98% survival rate and 87.9% success rate and they concluded that the root membrane technique is safe and very reliable with very low biologic complications.<sup>13</sup> Bramanti et al reported a randomized controlled trial of 40 patients comparing socket shield technique with immediate implant placement with the conventional implant placement technique after three years follow up and showed that socket

shield technique showed better esthetic results and less marginal bone resorption ( $0.605 \pm 0.06$ ) compared with the conventional technique ( $1.115 \pm 0.131$ ).<sup>15</sup> Similarly, Abadzhev et al. compared the conventional approach for immediate implant placement including soft and hard tissues grafting with the socket shield technique and they found that the conventional approach was clearly inferior regarding the outcome of esthetic and tissue changes.<sup>17</sup> A study conducted by Schwimmer et al. presented the first human histologic case report and they found that the bone occupied the space between root dentin and the implant surface.<sup>18</sup> Mitsias et al presented a 5 years human histological evidence of an immediate implant with the root membrane technique in the maxillary lateral incisor and they demonstrated healthy PDL and without any buccal bone plate resorption. The apical and medial 3rd space between implant and root membrane was filled with compact mature bone and the coronal 3rd space was colonized by non-infiltrated connective tissue.<sup>19</sup> Gluckman et al reported 128 socket-shield cases with 4 years follow up and showed 96.1% survival rate and they concluded that socket-shield performs competitively when compared to conventional immediate and delayed implant survival rates.<sup>14</sup> Schwimer et al demonstrated that SST may be effective at molar sites but it was very difficult due to the root curve and divergent nature and should be attempted by clinicians experienced in SST at the anterior region.<sup>20</sup> In the present case report the distance between the implant surface and the shield was less than 1mm and there was no bone graft placed. Mourya et al concluded in their recent systematic review that bone graft between the implant and shield should be restricted to cases where the jumping distance is more than 1 mm.<sup>10</sup> This case report has presented the jumping distance less than 1 mm for that's no bone graft used. This case report is consistent with most studies and shows successful aesthetic and functional outcomes for socket shield with immediate implant placement in the aesthetic zone.

## Conclusion

After three years follow up, Socket shield technique can prevent soft and hard tissue changes that happens during healing of alveolar socket after tooth extraction. Routine treatment option of SST with immediate implant placement requires prudent participation of clinician in further histological evidence and long-term follow up with large sample size.

## Conflict of interest and source of funding

The authors declare that there was no conflict of interest for this study. This study did not receive any funding.

## Acknowledgments

Authors would like to thank and fully appreciate Dr. Sharifa Abdulwahab Amer for her kind efforts and tremendous help.

## References

1. Araújo MG, Lindhe J. Dimensional ridge alterations following tooth extraction. An experimental study in the dog. *J Clin Periodontol* 2005;32:212–8.
2. Araújo MG, Sukekava F, Wennström JL, Lindhe J. Ridge alterations following implant placement in fresh extraction sockets: An experimental study in the dog. *J Clin Periodontol* 2005;32:645-52.
3. Bäumer D, Zuhr O, Rebele S. The socket-shield technique: first histological, clinical, and volumetric observations after separation of the buccal tooth segment - A pilot study. *Clin Implant Dent Relat Res* 2015;17:71-82.
4. Hürzeler MB, Zuhr O, Schupbach P, Rebele SF, Emmanouilidis N, Fickl S. The socket-shield technique: a Proof-of-principle report. *J Clin Periodontol* 2010;37(9):855-62.
5. Glocker M, Attin T, Schmidlin PR. Ridge Preservation with Modified "Socket Shield" Technique: A Methodological Case Series. *Dent J* 2014;2:11-21.
6. Gluckman H, Du Toit J, Salama M. The socket shield technique to support buccofacial tissues at immediate implant placement: A case report and review of the literature. *Int Dent Africa Ed* 2015;5:1-7.
7. Salama M, Ishikawa T, Salama H, Funato A, Garber D. Advantages of the root submergence technique for pontic site development in esthetic implant therapy. *Int J Periodontics Restor Dent* 2007;27:521–7.
8. Koshak H, Alsayed A. Is Alveolar Ridge can be Completely Preserved by Socket Shield Technique (SST)? A Case Report. *J Clin Periodontol* 2018;45(S19).
9. Akanksha Mourya, Sunil Kumar Mishra, Reetika Gaddale, Ramesh Chowdhary. Socket-shield technique for implant placement to stabilize the facial gingival and osseous architecture: A systematic review. *J Invest Clin Dent* 2019;10(4):e12449.
10. Furhauser R, Florescu D, Benesch T, Haas R, Mailath G, Watzek G. Evaluation of soft tissue around single-tooth implant crowns: the pink esthetic score. *Clin Oral Impl Res* 2005;16:639–44.
11. Berglundh T, Armitage G, et al. Peri-implant diseases and conditions: Consensus report of workgroup 4 of the 2017 World Workshop on the Classification of Periodontal and Peri-Implant Diseases and Conditions, pages S286-S291.
12. Garver DG, Fenster RK. Vital root retention in humans: A final report. *J. Prosthet Dent* 1980;43:368–73.
13. Siormpas KD, Mitsias ME, Kotsakis GA, Tawil I, Pikos MA, Mangano FG. The root membrane technique: a retrospective clinical study with up to 10 years of follow-up. *Implant Dent* 2018;27:564-74.
14. Gluckman H, Salama M, Du Toit J. A retrospective evaluation of 128 socket-shield cases in the esthetic zone and posterior sites: partial extraction therapy with up to 4 years follow-up. *Clin Implant Dent Relat Res* 2018;20:122-9.
15. Bramanti E, Norcia A, Cicciù M. Postextraction dental implant in the aesthetic zone, socket shield technique versus conventional protocol. *J Craniofac Surg* 2018;29:1037-41.
16. Baumer D, Zuhr O, Rebele S, Hürzeler M. Socket shield technique for immediate implant placement- clinical, radiographic and volumetric data after 5 years. *Clin Oral Implants Res* 2017;28:1450-8.
17. Abadzhiev M, Nenkov P, Velcheva P. (2014) Conventional immediate implant placement and immediate placement with socket-shield technique – Which is better. *Int J Clin Med Res* 2014;1:176–80.
18. Schwimer C, Pette GA, Gluckman H, Salama M, Du Toit J. Human histologic evidence of new bone formation and osseointegration between root dentin (unplanned socket-shield) and dental implant: case report. *Int J Oral Maxillofac Implants* 2018;33:e19-e23.
19. Mitsias ME, Siormpas KD, Kotsakis GA, Ganz SD, Mangano M, Iezzi G. The root membrane technique: human histologic evidence after 5 years of function. *Biomed Res Int* 2017;2017:1-8.
20. Schwimer CW, Gluckman H, Salama M, Nagy K, Du Toit J. The socket-shield technique at molar sites: a proof-of-principle technique report. *J Prosthet Dent* 2019;121:229-33.

**How to cite:** Alshammari NM, Alhawiti IA, Koshak H. Socket shield technique for optimizing aesthetic results of immediate implants. *IP Int J Periodontol Implantol* 2020;5(1):29-32.