



Original Research Article

Spectrum of neoplastic and non neoplastic skin lesions: A histopathological institutional study

Deepthi K.N¹, Shilpa Karamchedu^{1,*}, Saritha G¹¹Dept. of Pathology, SVS Medical college, Yenugonda, Telangana., India

ARTICLE INFO

Article history:

Received 09-01-2020

Accepted 24-01-2020

Available online 29-02-2020

Keywords:

Neoplastic skin lesions

Epidermal cyst

Squamous cell carcinoma

Benign

malignant neoplasm

ABSTRACT

Introduction: Skin lesions are complex due to wide range of neoplastic and non-neoplastic lesions. Several studies showed high prevalence of skin disorders in developing countries. Clinical presentation is restricted to hyperpigmentation, hypopigmentation, macules, papules and nodules but histopathology is highly variable. Accurate diagnosis is needed due to disease specific treatment and prognosis. Aim of the study is to evaluate different histopathological patterns of skin lesions for accurate diagnosis and to analyze age and sex distribution of skin lesions.

Materials and Methods: The study included a total number of 125 skin biopsies from July 2018 to June 2019 sent for histopathological examination to pathology department, SVS Medical College, Mahabubnagar, Telangana, India.

Results: In our study total 125 cases were analyzed. Out of which majority of the lesions (38.97 %) were in the age group of 21-40 years. Present study showed cutaneous cysts being the most common non-neoplastic lesion. In malignant tumors, out of 20 cases, 50% cases were Squamous cell carcinoma followed by basal cell carcinoma (30%).

Conclusion: Even though clinical features are few biopsy shows varied pathology and it is crucial for accurate diagnosis and differential diagnosis of skin lesions. Skin biopsy is a simple, inexpensive and gold standard method for definitive diagnosis and treatment of skin lesions. In the present study, non neoplastic lesions are more common than neoplastic skin lesions. Non neoplastic lesions more common in younger males of 21-40 yrs and neoplastic lesions in older age group. Epidermal cyst is most common non neoplastic lesion followed by trichilemmal cyst. Squamous papilloma is the most common benign neoplasm & Squamous cell carcinoma is the most common malignant neoplasm.

© 2020 Published by Innovative Publication. This is an open access article under the CC BY-NC-ND license (<https://creativecommons.org/licenses/by/4.0/>)

1. Introduction

The skin is a complex organ with many functions and three anatomic components: epidermis with skin adnexa, melanocytic system, and dermis and subcutis.¹ Dermatological lesions are commonly encountered in all countries and it encompasses a wide spectrum.² It varies from country to country and various regions within a country. This variation is also influenced by sex, age and associated systemic disorders, economy, literacy, racial and social customs.³ Majority of skin lesions are diagnosed on the basis of clinical presentation and history. The

histological diagnosis in turn is used by clinicians to aid in the management of patients and most appropriate clinical interventions.⁴ Clinical diagnosis of different entities is often difficult, as most of the appendageal tumors present as asymptomatic papules or nodules. Anatomical location, number and distribution of lesions provide important clue but histopathology is invaluable in confirmation of the diagnosis.⁵

The present study was carried out with an aim of describing the spectrum of various dermatological lesions in different ages groups and sexes during a period of one year.

* Corresponding author.

E-mail address: suresh.harithasa@yahoo.com (S. Karamchedu).

2. Material and Methods

In the present study, prospective study was done in Department of Pathology, SVS Medical College, Mahabubnagar, from July 2018 to June 2019.

All skin biopsies received were diagnosed based on routine histological examination on haematoxylin and eosin stained tissue sections. Clinical history and relevant data were recorded. Relative frequency of different lesions, age and sex distribution were analysed.

2.1. Inclusion criteria

All skin biopsies that showed specific pathology were included.

2.2. Exclusion criteria

Oral mucosal biopsies, inadequate and inconclusive biopsies were excluded.

3. Results

The present study was a prospective study of skin lesions from July 2018 to June 2019. A total of 125 cases were included in the study, out of which 77(61.60%) were non-neoplastic and 48(38.40%) were neoplastic. There were 73(58.40%) males and 42(41.60%) female with male: female ratio of 1.7:1. Among both males and females, the most common lesion was epidermal inclusion cyst (n=19, 15.2 % & n=13, 10.4 % respectively). The second most common lesion in both males and females was Squamous cell carcinoma (n=6, 4.8 % & n=4, 3.2 % respectively). Age and sex wise distribution of skin lesions is tabulated in Table 1.

Maximum number of cases belong to 21 – 30 years age group with males predominating the group (n=10). Maximum number of cases in the present study were cutaneous cysts (41.6 %) followed by benign skin tumors (22.4 %) and malignant skin tumors (16.0 %) (Table 3).

Cutaneous cysts comprise majority of non-neoplastic lesions (n=52, 41.6%) followed by infectious skin lesions (n=9, 7.2%). Most common cutaneous cyst was epidermal cyst (n=32, 41.55%) with male preponderance. Epidermal cysts (41.55%) and Trichilemmal cysts (Figure 1) (10.38%) were more common in males and dermoid cysts (11.68%) were more common in females.

Among the non-neoplastic lesions of skin, one case of Darries disease (Figure 1) (1.30%) and Discoid lupus erythematosus (1.30%) were reported and both were females. One case of Bullous pemphigoid was reported in a male patient. \$ cases of Hansen's, 3 cases of Lichen planus (3.90%) and 2 cases of Psoriasis (2.60%) were reported, all showed male preponderance. 3 cases of calcinosis cutis (3.90%) and implantation dermoid (3.90%) were diagnosed, both showed male preponderance. 2 cases

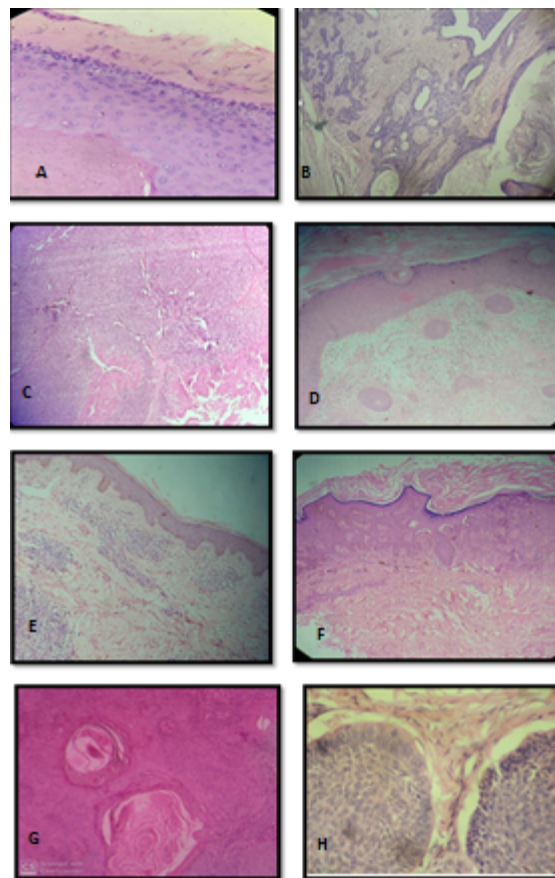


Fig. 1: A. H&E showing trichilemmal cyst. B. H&E showing Trichoepithelioma. C. H&E showing Proliferating trichilemmal tumor. D. Discoid lupus erythematosus. E. H&E showing Hansens. F. H&E showing Darrier's disease. G. H&E showing SCC. H. H&E showing Basal cell carcinoma.

of hypertrophic scar (2.60 %) and pyogenic granuloma (2.60%) were reported and showed equal sex distribution. One case of corn(1.30%) was reported in female patient (Table 4).

2 cases of seborrheic keratosis, verruca vulgaris, proliferating trichilemmal cyst, blue nevus and dermatofibroma were reported which showed equal sex distribution. 2 cases on intradermal nevus were reported and both were females. One case of Bowen's disease and Nevus sebaceous of Jadossahn each was reported and all were males. One case of Trichoepithelioma (Figure 1), Trichilemmoma and Spitz nevus were reported and all were females.

In the present study, maximum number of benign skin tumors (42.86%) were seen between 31 – 50 years and female predominance with male to female ratio of 0.7:1. Among 28 benign tumors, squamous papilloma (28.59 %) was the most common lesion followed by pilomatrixoma (10.72 %) and both showed male predominance (Tables 4 and 5).

Table 1: Age and sex wise distribution of skin lesions

S. No	Age in years	Non-neoplastic				Benign				Malignant			
		M	F	Total	%	M	F	Total	%	M	F	Total	%
1	0 - 10	4	3	7	9.10%	1	0	1	3.57%	-	-	-	-
2	11 – 20	5	4	9	11.68%	1	1	2	7.14%	-	-	-	-
3	21 – 30	10	6	16	20.78%	3	1	4	14.29%	1	0	1	5%
4	31 – 40	8	6	14	18.19%	3	4	7	25.00%	0	1	1	5%
5	41 – 50	7	5	12	15.58%	2	3	5	17.86%	3	1	4	20%
6	51 - 60	5	4	9	11.68%	3	1	4	14.29%	2	1	3	15%
7	61 – 70	4	2	6	7.80%	2	1	3	10.71%	3	4	7	35%
8	71 – 80	3	1	4	5.19%	1	1	2	7.14%	2	2	4	20%
	Total	46	31	77		16	12	28		11	9	20	

Table 2: Classification of skin lesions based on histopathological examination

Nature of skin lesion	Diagnosis	No. of Cases	Percentage (%)
Non infectious erythematous macula-papular lesions	Lichen planus, Discoid lupus erythematosus	4	3.2 %
Vasculitis	-	0	0
Non-infectious vesiculobullous lesions	Bullous pemphigoid, Psoriasis	3	2.4 %
Infectious skin lesions	Tuberculous verruca cutis, Leprosy, Condyloma accuminatum, Actinomycosis	9	7.2 %
Congenital lesions	Darrier 's disease	1	0.8 %
Cutaneous cysts	Epidermal cyst, Trichilemmal cyst, Dermoid cyst, Implantation dermoid	52	41.6 %
Benign Tumors	Squamous papilloma, Seborrheic keratosis, Verruca vulgaris, Bowens disease, Pilomatrixoma, Trichoepithelioma, Trichilemmoma, Proliferating trichilemmal cyst, Nevus sebaceous of Jadossahn, Intradermal nevus, Blue nevus, Spitz nevus, Dermatofibroma	28	22.4 %
Malignant	Squamous cell carcinoma, Basal cell carcinoma, Malignant melanoma, Sebaceous carcinoma, Eccrine adenocarcinoma,	20	16.0 %
Others	Hypertrophic scar, Corn, Calcinosis cutis, Pyogenic granuloma	8	6.4 %

In the present study, maximum number of malignant tumors were seen between 41 – 80 years and showed female preponderance with male to female ratio of 1.25:1. Among 20 cases of malignant tumors, squamous cell carcinoma was most common (50 %) followed by basal cell carcinoma (Figure 1).

4. Discussion

In the present study, a total number of 125 cases were included, out of which 77 cases were non-neoplastic and 48 cases were neoplastic. There was male preponderance in our study when compared to females similar to the study done by Grover et al (2008)⁶, C.Sushma et al (2018)⁷ and Gaikwad SL et al (2016)⁸. Among all cases included in the study, non-neoplastic cases outnumbered neoplastic cases, similar findings were noted with studies done by Das KK

et al (2003)⁹ and Sushma et al (2018)⁷. On the contrary, Gaikwad SL et al (2016)⁸ and Sonu Yadav et al (2018)¹⁰ reported higher number of neoplastic cases.

In the present study, most of the non-neoplastic lesions were under the age of 50 years, similar findings were noted with studies done by Gulia et al (2014)¹¹ and Sushma et al (2018)⁷. Most of the non-neoplastic lesions in the present study were epidermal cysts, which is similar to study done by Dr. Sheela L Gaikwad et al (2016)¹² and in contrast to studies done by Das et al (2005)¹³ and Sarkar SK et al (2010)¹⁴.

In the present study, most common malignant tumor reported was squamous cell carcinoma followed by basal cell carcinoma. Similar findings were noted with the studies done by Dr. Sheela L Gaikwad et al (2016) and Abubakar et al (2016)¹⁵. The prevalence of various skin diseases varies according to geographical area and is related

Table 3: Distribution of Non-neoplastic lesions of skin

Non-neoplastic lesions	No. of cases		Total	Percentage (%)
	M	F		
Lichen planus	2	1	3	3.90%
Psoriasis	2	0	2	2.60%
Bullous pemphigoid	1	0	1	1.30%
Darrier disease	0	1	1	1.30%
Discoid lupus erythematosus	0	1	1	1.30%
Tuberculous verruca cutis	1	1	2	2.60%
Leprosy	3	1	4	5.19%
Condyloma accuminatum	2	0	2	2.60%
Actinomycosis	1	0	1	1.30%
Epidermal cyst	19	13	32	41.55%
Trichilemmal cyst	5	3	8	10.38%
Dermoid cyst	4	5	9	11.68%
Implantation dermoid	2	1	3	3.90%
Hypertrophic scar	1	1	2	2.60%
Corn	0	1	1	1.30%
Calcinosis cutis	2	1	3	3.90%
Pyogenic granuloma	1	1	2	2.60%

Table 4: Distribution of Benign tumors of skin

Benign Tumors	No. of Cases		Total	Percentage (%)
	M	F		
Squamous papilloma	5	3	8	28.59 %
Seborrheic keratosis	1	1	2	7.14 %
Verruca vulgaris	1	1	2	7.14 %
Bowen's disease	1	0	1	3.57 %
Pilomatrixoma	2	1	3	10.72 %
Trichoepithelioma	0	1	1	3.57 %
Trichilemoma	0	1	1	3.57 %
Proliferating trichilemmal cyst	1	1	2	7.14 %
Nevus sebaceous of Jadossahn	1	0	1	3.57 %
Intradermal nevus	0	2	2	7.14 %
Blue nevus	1	1	2	7.14 %
Spitz nevus	0	1	1	3.57 %
Dermatofibroma	1	1	2	7.14 %

Table 5: Distribution of malignant tumors of skin.

S. No	Malignant Tumors	No of cases		Total	Percentage
		M	F		
1	Squamous cell carcinoma	6	4	10	50 %
2	Basal cell carcinoma	3	3	6	30 %
3	Malignant Melanoma	1	1	2	10 %
4	Sebaceous carcinoma	0	1	1	5 %
5	Apocrine Duct Carcinoma	1	0	1	5 %

to racial, environmental and socioeconomic factors of the population.¹⁶

5. Conclusion

In our study, wide spectrum of skin lesions were diagnosed, though less in number but were noticeable. Non-neoplastic lesions were the major entity with epidermal cyst being the predominant one. Squamous cell carcinoma was the major malignant lesion.

Histopathological examination combined with clinical findings help in proper diagnosis, predicting the treatment and prognosis. As the skin biopsy is fast, simple and done at little inconvenience to the patient, the entire spectrum of disease process can be correlated clinically and pathologically. Thus, timely reporting of skin diseases is of great importance for reducing disease burden and improving quality of life.

6. Source of funding

None.

7. Conflict of interest

None.

References

- Li M, Urmacher CD. Urmacher CD: Normal skin. In: Mills SE, ed. *Histology for pathologists*. Lippincott Williams & Wilkins ; 2007, . p. 1-1272.
- Narang S, Jain R. An evaluation of histopathological findings of skin biopsies in various skin disorders. *APALM*. 2015;2(1):A42-A46.
- Agarwal D, Singh K, Saluja SK, Kundu PR, Karma H. Histopathological Review of Dermatological Disorders with a Keynote to Granulomatous Lesions: A Retrospective Study. *Int J Sci Stud*. 2015;3(9):66-69.
- Mehar R, Jain R, Kulkarni CV, Narang S, Mittal M, et al. Histopathological study of dermatological lesions - A retrospective approach. *Int J Med Sci Public Health*. 2014;3:1082-1085.
- Saha A, Das NK, Gharami RC. A Clinico-Histopathological Study Of Appendageal Skin Tumors, Affecting Head And Neck Region In Patients Attending The Dermatology OPD of A Tertiary Care Centre In Eastern India. *Indian J Dermatol*. 2011;56:33-36.
- Grover S, Ranyal RK, Bedi MK. A cross section of skin diseases in rural Allahabad. *Indian J Dermatol*. 2008;53(4):179-179.
- Sushma C, Sekhar BHPC, Faheem MK, Sujatha C, Lavanya G, et al. Histomorphological Motif of skin lesions - A model analysis in a tertiary care teaching hospital. *IOSR J Dent Med Sci*. 2018;p. 70-76.
- Gaikwad SL, Kumawat UD, Sakhare NA, D'costa GF. Histopathological Spectrum of Skin Lesions- Experience at Rural Based Hospital. *Int J cur Res*. 2016;8(8):36223-36227.
- Das KK. Pattern of dermatological diseases in Gauhati Medical College and Hospital Guwahati. *Indian J Dermatol, Venereol Leprol*. 2003;69(1):1618-1618.
- Yadav S, Sharma U, Raghava V, Ball IK. Histopathological spectrum of skin lesions among patients in a rural community. *Int J Curr Adv Res*. 2018;.
- Gulia SP, Wadhai SA, Lavanya M, Menon R, Chaudhary M, et al. Histopathological Pattern of Skin Diseases in Teaching Hospital Puduchery. *Int J Recent Trends Sci Technol*. 2014;11:45-50.
- Gaikwad SL, Kumawat UD, Sakhare NA, Grace F, D'costa, et al. Histopathological spectrum of skin lesions experience at rural based hospital". *Int J Curr Res*. 2016;8(08):36223-36227.
- Das A, Halder S, Das J, Mazumdar G, Biswas S, et al. Dermatologic disease pattern in an urban institution in Kolkata. *Indian J Dermatol*. 2005;50:22-24.
- Sarkar SK, Islam AKMS, Sen KG. Patterns of skin diseases in patients attending OPD of Dermatology & Venereology at Faridpur Medical College. *Faridpur Med Coll J*;2010(1):14-16.
- Abubakar SD, Tangaza AM, Sahabi SM, Legbo JN. Histopathological pattern of skin lesions in UsmanuDanfodiyo University Teaching Hospital Sokoto. *Nigeria*. 2016;6.
- Renuka A, Purandare CS, Suresh K, Kulkarni AP. Study of Pattern of skin diseases among patients attending OPD of Dermatology, Venereology & Leprosy Department at Bharati Vidhyapeeth Deemed University Medical College & Hospital. *Int J Healthcare Biomed Res*. 2016;4(04).

Author biography

Deepthi K.N Associate Professor

Shilpa Karamchedu Assistant Professor

Saritha G Post Graduate

Cite this article: Deepthi K.N , Karamchedu S, Saritha G . Spectrum of neoplastic and non neoplastic skin lesions: A histopathological institutional study. *IP J Diagn Pathol Oncol* 2020;5(1):25-29.