

Comparative evaluation of 2.0mm miniplates over Champy's miniplates in mandibular fractures in rural population of Chhattisgarh

Abhishek Agrawal¹, Deepshri Agrawal^{2*}

^{1,2}Assistant Professor, Dept. of Dentistry, Raipur Institute of Medical Sciences, Raipur, Chhattisgarh, India

*Corresponding Author: Deepshri Agrawal

Email: deepshri.agrawal@gmail.com

Abstract

Introduction: Mandible is the largest and strongest facial bone, by virtue of its position on the face and its prominence, it is commonly fractured when maxillofacial trauma has been sustained. The main disadvantage of conventional bone plate/screw systems is that the plate must be perfectly adapted to the underlying bone to prevent alterations in the alignment of the segments and changes in the occlusal relationship during screw tightening.

Introduction of 2.0 mm locking plate/screw plating systems for the treatment of mandibular fractures works on the principle of restricted backout and function as internal fixators, achieving stability by locking the screw to the plate with unique advantage of obviating the need of intimate contact of the plate with the underlying bone. So the study was planned with an aim for comparative evaluation of use of 2.0-mm stainless steel locking miniplates with Champy's miniplates in mandibular fractures in terms of stability, postoperative healing & associated complications.

Materials and Methods: This cross sectional prospective interventional analytical study was carried out in Department of Dentistry at Raipur Institute of Medical Sciences, Raipur over a period of 10 months from September 2016 to July 2017. A total of 60 patients were enrolled in two study groups of 30 each. Detailed clinical, laboratory and radiological examination was followed by standard operative procedures described by the various authorities using two different Miniplates. The results were documented in Microsoft Excel and statistical analysis was done using Epi-info.

Results: Both the study groups were having 30 patients each. 26 males and 4 females in group I whereas 28 males and 2 females in group II. A total of 54/60 patients were male and 6 females. Road traffic accident was the most common cause of mandibular fractures in 37/60 (61.66%). Parasymphysis was the most common site of fracture (40%). There is no significant difference in working time, post-operative infections but significant difference is observed in terms of post-operative occlusion, mobility of fractured segments, pain at various point of time measured on visual analogue scale when tested with various tests of significance

Conclusion: The use of 2.0mm locking plate system with its advantages of improved handling characteristics, increased stability, less occlusive discrepancy, low infection rate, less mobility, less pain appear to be an effective and reliable alternative to Champy's miniplates in mandibular fractures.

Keywords: Locking plate system, Working time, Postoperative occlusion, Post-operative mobility.

Introduction

Mandible is the largest and strongest facial bone. By virtue of its position on the face and its prominence, it is commonly fractured when maxillofacial trauma has been sustained. Its peculiar curved pattern and prominent contour, forming the so called jaw line makes it very susceptible to trauma.¹ It has been observed, that fractures of the mandible occur twice as often as mid-facial fractures even though almost four times as much force is required to fracture the mandible versus the maxilla.¹ The mandible is amongst the most significant bones of the face. Its fracture deserves special attention as it prevents the patient from performing life's normal activities like speech, mastication, and deglutition as well as maintaining aesthetics. In complicated cases, the airway and hence the breathing of the patient may also be hampered.²

Techniques for treatment of mandibular fractures have evolved significantly in the past decade which ranges from closed reduction with maxilla-mandibular fixation (MMF), to open reduction with wire osteosynthesis, to open reduction with either rigid internal fixation or adaptive miniplate fixation.

External appliances fixed to a head cap and semi-rigid immobilization by wire suspensions were cumbersome to

the patients and entailed long period of immobilization. Many failures resulted from early attempts at plate and screw fixation, probably owing to the lack of knowledge of the biomechanics of these systems. These plates had many disadvantages like risk of injury to the neurovascular bundle and teeth due to bicortical screws. They were bulky and uncomfortable for the patients and resulted in subsequent complications like exposure, infection etc. which often entailed a second surgery for their removal.²

Transoral placement of noncompressive miniplates has recently gained popularity by using the principles of Champy and are commonly referred to as the 'miniplates'. The main disadvantage of conventional bone plate/screw systems is that the plate must be perfectly adapted to the underlying bone to prevent alterations in the alignment of the segments and changes in the occlusal relationship during screw tightening. These plates may even rebound after bending, resulting in screw loosening.³

Introduction of locking plate/screw plating systems for the treatment of mandibular fractures works on the principle of restricted back out and function as internal fixators, achieving stability by locking the screw to the plate with unique advantage of obviating the need of intimate contact

of the plate with the underlying bone, making plate adaptation easier. So the study was planned with an aim for comparative evaluation of use of 2.0-mm stainless steel locking miniplates with Champy's miniplates in mandibular fractures in terms of stability, postoperative healing & associated complications.

Materials and Methods

This cross sectional prospective interventional analytical study was carried out in Department of Dentistry at Raipur Institute of Medical Sciences, Raipur over a period of 10 months from September 2016 to July 2017. After obtaining the institutional ethics committee approval a total of 60 patients of minimally displaced mandibular fracture were enrolled after taking the informed consent form patients with an inclusion criteria of age above 14 years, no history of Diabetes, hypertension or Ischemic heart disease, reporting within 7 days of trauma without any other associated fracture in facial skeleton. All the patients not complying to the above criteria as well as patients with poor dental hygiene, gross infection at site of fracture, smokers and tobacco chewers, as well as patients with less mandibular vertical height between root apex of teeth and lower border of mandible were excluded.

A thorough history was taken that included the time and date of accident, time of reporting, mechanism of injury and history of bleeding from ear, nose and oral cavity. The patient was also questioned about the history of unconsciousness, vomiting and convulsions as well as the history of amnesia. This was followed by a detailed clinical examination. The oral cavity was cleaned of blood clots, fractured tooth edges and other debris. A temporary stabilization was provided when deemed necessary. The face and the oral cavity were examined for signs of soft tissue injuries. All wounds were debrided and lacerated wounds were sutured with 3-0 silk. Inj TT 0.5 ml IM was administered and patient were started on antibiotics and analgesics.

The patients were grouped into two groups based on the miniplates used

Group I: 2.0-mm locking miniplates.

Group II: Champy's miniplates.

All patients were investigated for routine blood parameters like Haemoglobin estimation, CT, BT, TLC and DLC as well as for radiological assessment by orthopantomogram (OPG) was done. An OPG was taken preoperatively, while more OPGs followed postoperatively, one just after surgery and one after six months.

Evaluation Parameters

The patients were assessed on 8 different parameters namely -1) Working time period in minutes, 2) Postoperative occlusion, 3) Postoperative pain (according to "visual analogue scale"), 4) Postoperative mobility of fractured segments, 5) Postoperative infection, 6) Incidence of tooth damage, 7) Incidence of plate failure & 8) Sensory disturbances.

All the patients were evaluated on the first post-operative day, 1 week post operatively and after 1 month. Patients were further kept on a follow up for a period of 6 month and evaluated clinically as well as radiographically.

Operative technique

The method of surgical exposure of the fracture site and reduction of the fracture was similar to both groups of patients. All the plates and screws were placed through an intraoral approach or extraoral approach either under general anesthesia or local anesthesia. All the patients were kept under appropriate antibiotic cover pre-operatively and upto 5 days postoperatively. Intermaxillary fixation was achieved to settle the occlusion before surgery. Patients were sedated with diazepam 10 mg. I.V. and regional anesthesia was achieved with lignocaine 2% and adrenaline 1:100000, an inferior alveolar nerve block and infiltration anaesthesia.

Group I: Plate osteosynthesis was performed using 2.0 mm locking stainless steel miniplates with 2.0 mm self tapping locking screws. 4 hole plates with bar (gap) were used and 2 x 8 mm screws were used for symphysis, parasymphysis and body region and 2 x 6 mm screws were used for angle region. As the locking design did not mandate passive adaptation of the plate to the bone surface, exact contouring of the plate was not done and an offset of 1.0 to 2.0 mm was allowed.⁴

Group II: Following reduction, miniplates were applied along the osteosynthesis line as described by Champy. In symphyseal or parasymphyseal fractures, two plates were placed to overcome the torsional forces. One plate is placed above the imaginary line joining the mental foramina and one below the line with a 5 mm distance between the two plates. The plate below the line was placed first, followed by the plate above the line, to prevent development of diathesis at the lower border due to action of masticatory muscles. In angle region a single plate was adapted on the flat vestibular area of bone adjacent to the external oblique ridge or at the inferior border of the mandible. The stainless steel miniplates were adapted over the surface of the mandible with the help of modeling pliers and bar modeling levers. During drilling, the adapted plate was held firmly against the bone with the plate holding forceps. The drilling was then performed by 1.5mm stainless steel drill bit perpendicular to the surface of bone. Plates were fixed with 2 x 10 mm stainless steel screws at symphyseal or parasymphyseal fractures and with 2 x 6 mm stainless steel screws at angle region.^{5,6}

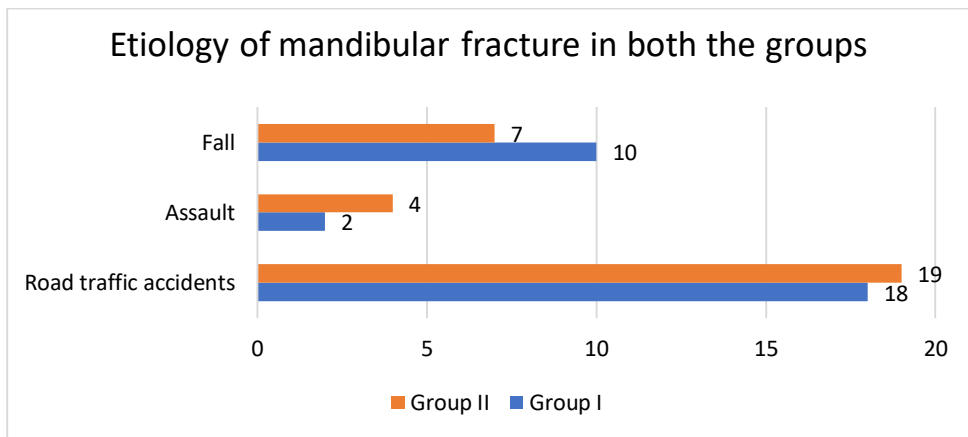
Irrigation and Closure

After plate fixation, surgical site was copiously irrigated with 5% Povidone iodine and followed by normal saline. Hemostasis was achieved and suturing was done with 3-0 vicryl & 3-0 silk in layers. Pressure pack was applied and patients were prescribed antibiotics and analgesics for 7 days. The intermaxillary fixation was removed and the patient was advised to maintain the oral hygiene and to perform oral rinses with betadine. Patient was also advised soft diet for the first week. The patient was followed

up on weekly interval for a month and then at 3 months and 6 months.

Observation and Results

Both the groups were having 30 patients each. 26 males and 4 females in group I whereas 28 males and 2 females in group II. A total of 54/60 patients were male and 6 females. Out of the 60 patients in the study 37/60(61.66%) were because of fractures, 17/60(28.33) because of road traffic accident whereas 6/60(10%) were because of assault. The distribution of which in each group is as in Graph 1.



Graph 1: Etiology of mandibular fracture in both the study groups

Distribution of patients in both the groups according to the site of the fracture is as shown in Table 1

Table 1: Distribution of patients in study groups according to the fracture site.

Site	Group I	Group II	Total
Symphysis	2	4	6(10%)
Parasymphysis	13	11	24(40%)
Body	6	10	16(27%)
Angle	9	5	14(23%)

Comparison of various parameters in both the study groups with mean and standard deviation and test of significance using student t test is as shown in Table 2 and 3.

Table 2: Comparative evaluation of working time, post-operative occlusion, post-operative infection at 1 week and 1 month and post operative mobility of fracture segments

Groups	Working Time in minutes	Post-Operative Occlusion		Post Operative Infection at 1 st Week		Post operative Infection at 4 th Week		Post operative mobility of fracture segments	
		No Disturbance	Disturbance	Infection	No Infection	Infection	No Infection	No mobility	Mobility
Group I	48.83±4.48	27	03	26	4	29	01	28	02
Group II	47.17±4.48	21	09	20	10	26	04	22	08
Test of significance	T test -1.43	Mann Whitney Value-357		Mann Whitney Value-360		Mann Whitney Value-405		Mann Whitney Value-355	
P value	0.15	0.03		0.0689		0.1666		0.0382	
Comparative evaluation	Not Significant	Significant		Not Significant		Not Significant		Significant	

Pain was recorded based on the visual analogue scale for patients preoperatively and post operatively on day of surgery (Day 1), at 1 week and at 1 month post-operatively as in Table 3.

Table 3: Mean post-operative pain score based on visual analog scale with standard deviation and comparison of same in both the study groups.

	Pain at 24 Hrs	Pain at 1 week	Pain at 1 month
Group I	2.50±0.57	0.33±0.49	0.06±0.25
Group II	2.06±0.73	0.86±0.73	0.10±0.30
Mann Whitneytest	314.50	282	435
P value	0.0139	0.029	0.647
Comparative evaluation	Significant	Significant	Not Significant

Iatrogenic damage caused by the screws was evaluated on radiographs and graded as minor and major contact. Minor contact was seen in 1 case of Group II and 0 case of Group I. None of the Group showed the incidence of Major contact.

1/30(3.33%) patients in group I and 4/30(13.33%) patients in group II showed plate failure due to chronic infection and loosening of hardware. No patient in any of the groups showed plate failure due to fracture of the plate.

In group I, 3/30(10%) patients showed temporary paresthesia preoperatively, 4/30(13.33%) patients at 1 week and 1/30(3.33%) patient at 4 weeks whereas in group II, 2/30(6.66%) patients showed temporary paresthesia preoperatively, 2/30(6.66%) patients at 1 week and 1/30(3.33%) patient at 4 weeks.

Discussion

The only permanent thing in this world is change. Over the years the methods to treat mandibular fractures have undergone many refinements. The strategic position of the mandible on the facial skeleton and its unique role in Mastication, Deglutition, Phonation and Esthetics compels the clinician to give immediate attention whenever it is fractured.

The male dominance as observed in our study was also reported by Haug et al⁷ who did a 5 years retrospective review of facial fractures. This may be justified by the fact that the males are generally more prone to situations in which there is higher risk of trauma.

Road traffic accident was the cause of mandibular fractures in 37 cases (61.66%), fall in 17 cases (28.33%) and in 6 cases (10%) it was interpersonal violence. This distribution could be compared favorably with the results obtained by Schuchardt et al⁸ who found road traffic accidents to be the cause in 35.6% cases, fist fights in 31.8% and work related accidents and sports accidents in 11.6% and 3.3% cases respectively. Higher incidence of Road traffic accident can be explained by the fact that there are no comprehensive rules for traffic safety in our country.

In this study parasymphysis was the most common site of fracture (40%) followed by body (27%), angle (23%) and symphysis (10%). This result was contradictory to the findings of Huag et al⁷ who found body of mandible to be the most common site (29.5%) and Schuchardt et al⁸ who had condylar fractures (25%) having the highest frequency. This difference could be explained on the basis of the selection criteria's of this study which excluded grossly displaced fractures of the mandible.

In the present study, 27 patients of 2.0mm locking plate osteosynthesis (90%) had normal pre-morbid occlusion postoperatively. Only 3/30(10%) patients had postoperative occlusal discrepancy which was treated successfully by employing intermaxillary fixation for a period of 7 days in 1 patient and selective occlusal grinding in 2 patients. Sauerbier S, Kuenz J and Hauptmann S⁹ reported 6% incidence of minor occlusal discrepancy postoperatively in 53 mandibular fractures treated with locking plates and this finding is consistent with our study. Ayman C et al¹⁰ assessed 2.0 mm locking Miniplate screw system in the treatment of mandibular fractures with a 1 week period of maxillomandibular fixation.

On the other hand, 21 patients (70%) of Champy's miniplate osteosynthesis had normal postoperative occlusion. Of the remaining 9 patients (30%) with occlusal discrepancy, 7 patients had to undergo intermaxillary fixation for 1 week along with selective occlusal grinding and 2 patients were put on intermaxillary fixation for 2 weeks. In the prospective study by Cawood¹¹ 5.7% of mandibular fractures, treated by miniplates osteosynthesis had malocclusion detected on review. The higher percentage of malocclusion (30%) in group II in our study could be because all patients with postoperative occlusal discrepancy were patients with displaced fractures.

This incidence of occlusal discrepancy was compared and showed statistically significant difference with significantly less occlusal disturbances postoperatively with 2.0 mm locking plates. The first biomechanical comparison of locking plates to appear in the maxillofacial surgical literature was made by Gutwald¹² He concluded that a higher stability was achieved with the locking plates.

Mandibular fractures are often contaminated by oral bacteria.¹³ The propensity of infection is increased with the natural reluctance of patient to swallow or move his tongue freely so that stasis develops with consequent accumulation of debris in the region of fracture. This encourages multiplication of bacteria and the greater delay in obtaining reduction and immobilization; the more likely it is that infections will result.¹⁴ Iizuka T and Lindquist C have shown that post reduction infection at the fractured site is not only the result of contamination, but is also related to reduced stability of fracture i.e. mobility of fractured segments.¹⁵ Zachariades N et al stated that stability is considered as the best protection against infection, as movement in the presence of foreign bodies (i.e. loose screws) usually leads to infection and pseudoarthrosis. Infection rate is also shown to be less with intra oral

approach.¹⁶ Avascularity is shown to be one of the primary risk factor and so is the presence of teeth in fracture line.¹⁷

Patients were evaluated preoperatively, and postoperatively at 1 week, 1 month and 6 months after surgery for the signs of infection. Swelling, local rise in temperature, local inflammation and pus discharge were considered indicators for the presence of infection. The rate of infection was compared between the two groups at 1 week and at 1 month interval by using Mann Whitney test. There was no significant difference between the two groups, however the infection was reported to be higher in group II.

The incidence of infection for Group I was 13% at 1 week and 3% at 1 month. The incidence of infection for Group II was 32% at 1 week and 13% at 1 month. Edward Ellis III¹⁸ has shown that with the use of open reduction and internal fixation, the reported incidence of infection ranged from 3% to 32%. Sauerbier et al⁹ treated 56 mandibular fractures with locking plates in 53 patients and reported 7.5% patients with minor complications like infection and dehiscence. Ellis and Graham,¹⁹ a total of 80 fractures in 59 patients were treated with the 2.0 mm locking plate/screw system, 6 (9%) patients developed postsurgical Infections. The data in our study was in accordance with the above studies.

Mobility at the fracture site was examined in Group I and Group II patients preoperatively and during various follow up stages. Preoperatively 3 out of 30 patients of Group I had no mobility, 18 patients had mobility in one plane and 9 patients had mobility in two plane. In Group II, 1 patient showed no mobility, 19 patients showed mobility in one plane and 10 patients showed mobility in two planes. In the present study, it was observed that at 1 week, 2(7%) out of 30 patients in group I had postoperative mobility present at the fracture site and in group II, 8(27%) out of 30 patients had postoperative mobility present at the fracture site.

Out of those 10 patients reported with mobility, 7 patients were put on intermaxillary fixation for 1 week, 3 patients for 2 weeks and then selective occlusal grinding was done if necessary. After 4 weeks, functional occlusion was restored in all patients. Mann Whitney test was applied to study the association between the mode of treatment and postoperative mobility. The results however showed statistically significant differences between the 2 groups, Group II having higher postoperative mobility between fractured segments.

Saikrishna D et al²⁰ in their study compared 2.0mm standard miniplates with locking miniplates and concluded that Locking plate/screw system proved to be more rigid than conventional plate/screw system. Favoring the other similar studies, group I patients in our study showed increased stability after fracture reduction and fixation obviating the need for IMF. Rigidity of fractured segments produces a stable foundation for better vascularity and soft tissue growth, thus allowing better healing of wound.

Pain associated with the procedure was recorded for Group I and Group II patients preoperatively and during various follow up stages based on a visual analogue scale.

(Table 3) Group I procedure was associated with significantly higher pain scores on the day of surgery but the pain was reported to be significantly higher in Group II at 1 week. However there was no significant difference between the pain scores of the two groups 1 month postoperatively, though the pain was still higher in group II.

The higher pain scores on day 1 for Group I patients was perhaps due to the wide surgical exposure and soft tissue retraction required for the placement of perpendicular screws and on 1 week for Group II was due to higher incidence of infection and mobility at the fracture segments.

One of the rare but most important complications associated with semi rigid fixation osteosynthesis is iatrogenic tooth damage. Post-operative OPG was evaluated to determine the incidence of tooth contact. The contacts were classified as major contact and minor contact. In present study, 1/30(3%) and first patient operated under Group II reported with minor contact. The damage occurred due to oblique placement of the screw to avoid screw insertion in the fracture line. The injured tooth was examined postoperatively for tooth vitality. Vitality testing was done by thermal tests using hot guttapercha points and ethyl chloride spray. Endodontic treatment was carried out for the management of injured tooth. No incidence of tooth injury was reported in Group I patients.

Postoperatively, complication like plate failure was evaluated in follow up period for both the Groups. In Group I, 1 (3%) out the 30 patients and in Group II, 4 (13%) out the 30 patients reported with infection at the fracture site.

2 patients in group II had a draining sinus tract postoperatively at 3 months. On radiographic examination it was revealed that the infection was due to loosening of the hardware and inter-fragmentary movement. Plate removal was done under higher antibiotic coverage in all of the patients reported with recurrent infection.

Hayter and Cawood²¹ showed mental paresthesia in 8% of cases of mandibular fractures treated by Miniplate osteosynthesis while in another study by Gabrielli²² postoperative paresthesia was found to be 31.52%. In our present study temporary paresthesia was noted to be present in 3(10%) patients preoperatively and 5(17%) patients postoperatively in group I and 2(7%) patients preoperatively and 3(10%) patients postoperatively in group II. In each one of the groups, 1 patient sustained the sensory disturbance for more than 4 weeks and they were managed conservatively. Although there was no significant difference between the postoperative sensory disturbances in both the groups, higher incidence of sensory disturbances in group I can be attributed to need for more tissue retraction for placement of perpendicular screws.

We could see the following advantages of 2.0 mm miniplates in that it was unnecessary for the plate to have intimate contact with the underlying bone in all areas and also decreases necrosis of fracture segments and produces less stress shielding due to non-compression. Locking bone plate/screw systems is that the screws are unlikely to loosen from the bone plate with greater amount of stability across the fracture gap. The study suggest that fixation of

mandibular fracture with locking plates provides extra stability and carries low morbidity and infection rates. The only probable limitations of these plates may be the slight technical sensitivity and the cost which is marginally higher in locking plates.

Conclusion

During the course of present study the 2.0mm locking miniplate was found to be standard in profile, strong yet malleable, facilitating reduction and stabilization giving additional stability at fracture site. The use of 2.0mm locking plate system with its advantages of improved handling characteristics, increased stability, less occlusive discrepancy, low infection rate, less mobility between fractured segments, less pain and preservation of bony perfusion appear to be an effective and reliable alternative to Champy's miniplates in mandibular fractures.

The small sample size and limited follow-up could be considered as the limitations of this study. It is recommended to have a multi-centric study with large number of patients and correlation among these studies to authenticate our claims.

Source of funding

None.

Conflict of interest

None.

References

1. Heulke DF Association between mandibular fractures related to teeth and edentulous regions. *J Oral Surg* 1964;22:396.
2. Gear A, Apasova E, Schmitz J, Schubert W. Treatment modalities for mandibular angle fractures. *J Oral Maxillofac Surg* 2005;63:655-63.
3. Ayman C, Stewart K, Julius R. Transoral 2.0-mm Locking Miniplate Fixation of Mandibular Fractures Plus 1 Week of Maxillomandibular Fixation: A Prospective Study. *J Oral Maxillofac Surg* 2005; 63:1737-41.
4. Ellis E III, Graham J. Use of a 2.0-mm locking plate/screw system for mandibular fracture surgery. *J Oral Maxillofac Surg* 2002;60:642.
5. Champy M, Pape HD. The Strasbourg Miniplate Osteosynthesis, Cited from Kruger E. and Schilli W. *Oral and Maxillofacial Traumatology* 1986;2:19-43.
6. Champy M. Mandibular osteosynthesis by miniaturized plates via a buccal approach. *J Oral Surg* 1978;6:14-21.
7. Haug R, Street C, Goltz M. Does plate adaptation affect stability? A biomechanical comparison of locking and non-locking plates. *J Oral Maxillofac Surg* 2002;60:1319.
8. Schuchardt K, Schwenzer N, Rottke B and Lentrodt J. Ursachen, Häufigkeit und Lokalisation der Frakturen des Gesichtsschadels. Cited from Kruger E and Schilli W. *Oral Maxillofac Traumatol* 1982;1:49-52
9. Sauerbier S, Kuenz J, Hauptmann S. Clinical aspects of a 2.0-mm locking plate system for mandibular fracture surgery. *J Craniomaxillofacial Surgery* 2010;38(7):501-4.
10. Ayman C, Stewart K, Julius R. Transoral 2.0-mm Locking Miniplate Fixation of Mandibular Fractures Plus 1 Week of Maxillomandibular Fixation: A Prospective Study. *J Oral Maxillofac Surg* 2005; 63:1737-41.
11. Cawood JI. Small plate osteosynthesis of Mandibular Fractures. *Br J Oral Maxillofac Surg* 1985;23:77-9.
12. Gutwald R, Alpert B, Schmelzeisen R. Principle and stability of locking plates. *Keio J Med* 2003;52:21-8.
13. Stephen L, Remy H. Mandibulotomy Fixation: A Laboratory Analysis. *J Oral Maxillofac Surg* 2003;61:1297-1301.
14. Bochlogyros P. A retrospective study of 1521 mandibular fractures. *J Oral and Maxillofac Surg* 1985;43:597-9.
15. Iizuka T, Lindquist C, Hallikainen D, Pauku P. Infections after rigid internal fixation of mandibular fractures: A clinical and radiological study. *J Oral Maxillofac Surg* 1991;49:585-90.
16. Zachariades N, Papademetriou I, Rallis G. Complications associated with Rigid Internal fixation of facial bone fractures. *J Oral Maxillofac Surg* 1993;51:275-8.
17. Bochlogyros P. A retrospective study of 1521 mandibular fractures. *J Oral Maxillofac Surg* 1985;43:597-9.
18. Ellis E 3rd. Treatment methods for fractures of the mandibular angle. *Int J Oral Maxillofac Surg* 1999;28:243-52.
19. Ellis E 3rd, Graham J. Use of a 2.0-mm locking plate/screw system for mandibular fracture surgery. *J Oral Maxillofac Surg* 2002;60:642.
20. Saikrishna D, Shetty SK, Marimallappa TR. A comparison between 2.0-mm standard and 2.0-mm locking miniplates in the management of mandibular fractures. *J Maxillofac Oral Surg* 2009;8(2):145-9.
21. Hayter JP, Cawood JI. The functional case for miniplates in maxillofacial surgery. *Int J Oral Maxillofac Surg* 1993;22(2):91-6.
22. Cabrini Gabrielli MA, Real Gabrielli MF, Marcantonio E, Hochuli-Vieira E. Fixation of Mandibular Fractures With 2.0 mm Miniplates Review of 191 Cases. *J Oral Maxillofac Surg* 2003;61(4):430-6.

How to cite the article: Agrawal A, Agrawal D. Comparative evaluation of 2.0mm miniplates over Champy's miniplates in mandibular fractures in rural population of Chhattisgarh. *J Dent Specialities* 2019;7(2):66-71.