

Repositioning of inferior alveolar nerve and implant placement in atrophic mandible -How far justified?

Biswajit Kumar Biswas^{1*}, Biswajit Das², Anindya Chakrabarty³

¹Chairman, ^{2,3}Consultant, Avinash Institute of Craniofacial and Reconstructive Surgery, Kolkata, West Bengal, India

***Corresponding Author: Biswajit Kumar Biswas**

Email: doc135798@yahoo.co.in

Abstract

Bone resorption in posterior mandibular region creates a challenge in placement of dental implants and prosthetic rehabilitation due to presence of inferior alveolar nerve (IAN). Several alternatives treatment modalities are suggested: the use of short implants, cortical implants, guided bone regeneration, appositional bone grafting (both autogenous and allograft), distraction osteogenesis, inclined implants tangential to mandibular canal, and the lateralization of the inferior alveolar nerve. In this paper, we will present IAN repositioning cases and simultaneous implant placement and assess the success of implants, severity of neurosensory disturbances and its impact on present day implant dentistry.

Keywords: Inferior alveolar nerve (IAN), Nerve repositioning, Dental implants, Mandibular atrophy, Neurosensory disturbances.

Introduction

Dental implant is a widely accepted treatment option for edentulous posterior mandible. But with the loss of teeth, the alveolar ridge undergoes a continuous and irreversible process of bone resorption in height and width. Severe atrophy of the mandible becomes a challenge to install dental implants of adequate height due to presence of inferior alveolar nerve (IAN).¹ IAN repositioning is a surgical procedure performed during placement of dental implants in atrophied posterior mandibular ridge without damaging the contents of inferior alveolar canal. First case of IAN repositioning was performed by Alling² (1977) but he used it for rehabilitate patients with severe atrophy for dentures. Later in 1987, Jenson and Nock³ carried out IAN repositioning for dental implants placement. In this surgical procedure, after buccal cortical osteotomy, IAN is identified and released from its canal and carefully retracted aside during implant placement under direct vision. Then neurovascular bundle is placed passively disto-lateral side of the implants. During surgical manoeuvre, traction and compression injuries to IAN causes variable neurosensory disturbances which takes to resolve 1-3months³ postoperative periods.

Case Presentation

Case 1

A 65 yrs old female presented with an old distorted Fixed Partial Denture (FPD) in mandibular posterior region on right side. We removed the bridge. Intraoral examination showed multiple decayed teeth. Radiographic examination (IOPA X RAY, OPG) confirmed the intraoral findings and severe atrophied ridge on that side. All the surgical options along with its advantages and demerits were discussed thoroughly with the patient; right inferior alveolar nerve repositioning was decided, with implant placement on that side, in the same surgical step.

Preoperative pertinent exams were undertaken for the patient, informed consent explained and signed. IAN repositioning and implant placement in 46, 47 regions were

done under local anaesthesia. She was given prophylactic antibiotics orally one hour before the procedure.

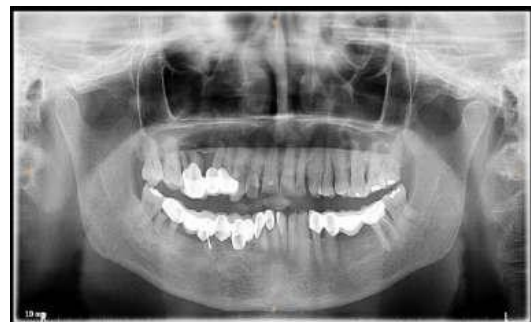

Fig. 1: Preoperative OPG

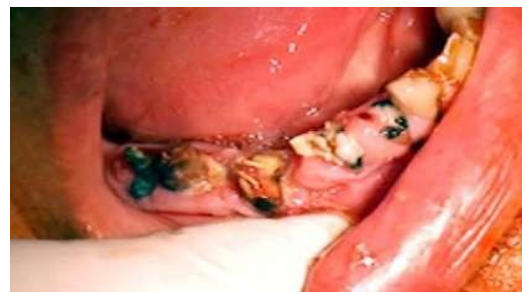

Fig. 2: Preoperative I/O view

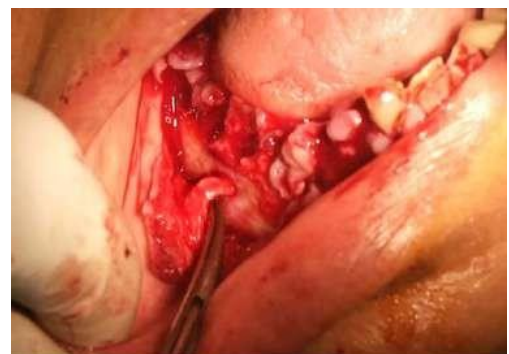

Fig. 3: Identification of mental nerve

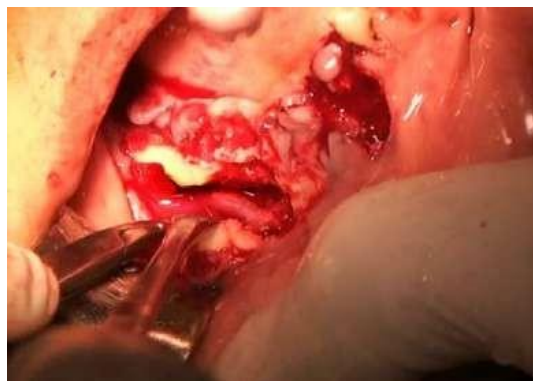

Fig. 4: Osteotomy cut

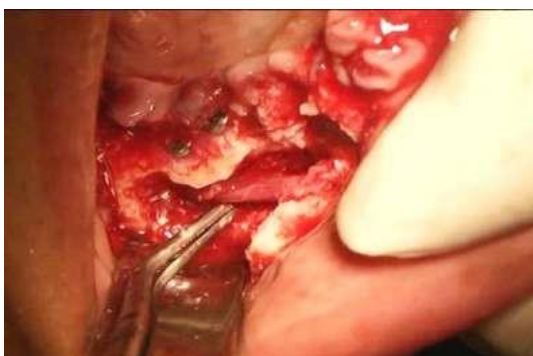

Fig. 5: implant placed retracting IAN safely

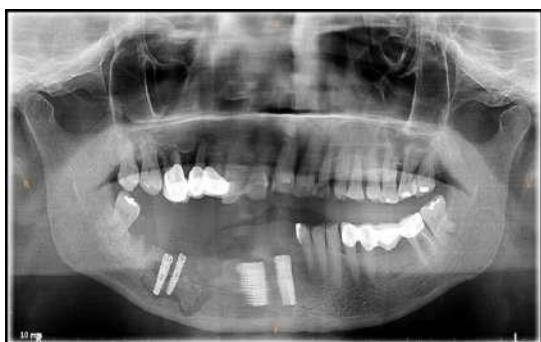

Fig. 6: Postoperative OPG

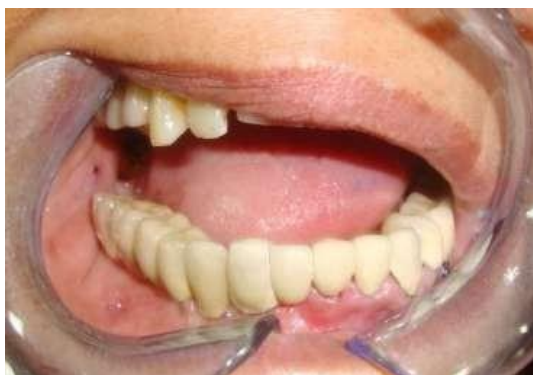

Fig. 7: Implant supported prosthesis

Case 2

A 55 years old man reported to our clinic with edentulous space in mandibular posterior region on right side.

Radiographic examination (IOPA X- RAY) confirmed the intraoral findings and severe atrophied ridge on that side. We explained all the options to him. Finally, he decided to undergo IAN repositioning and implant placement. Preoperative pertinent exams were undertaken for the patient, informed consent explained and signed. Two implants in 46, 47 regions were installed along with IAN repositioning under local anaesthesia. Antibiotic prophylaxis was given one hour before the procedure.

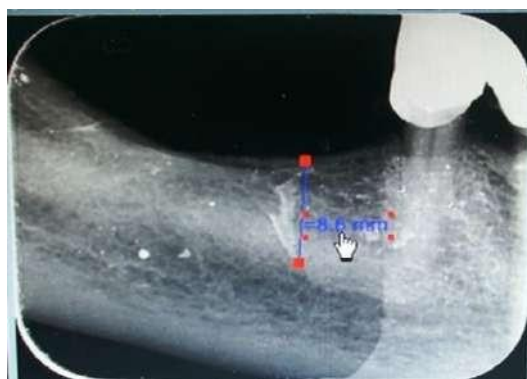


Fig. 8: Preoperative IOPA X Ray

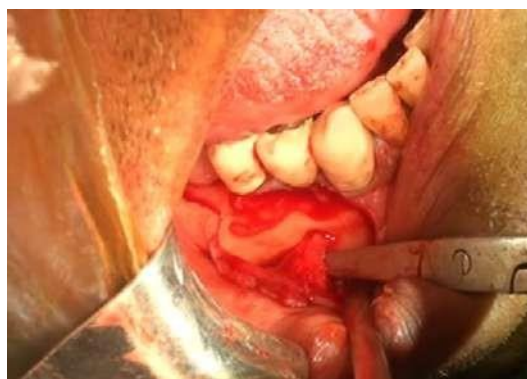

Fig. 9: Mental nerve identification

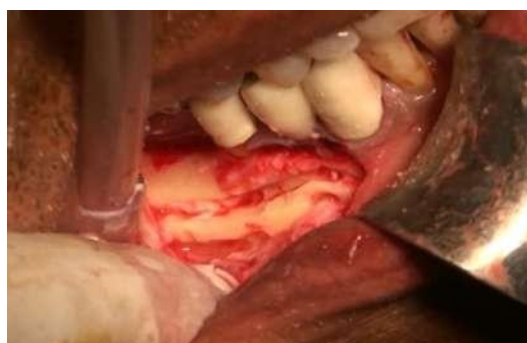

Fig. 10: Buccal osteotomy cut

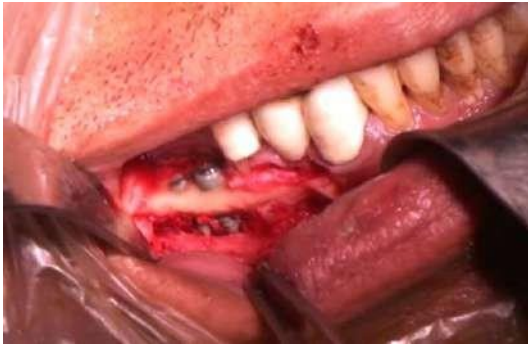

Fig. 11: Implant placement

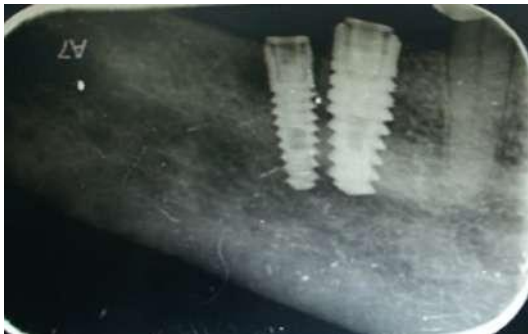

Fig. 12: Post-operative IOPA X ray

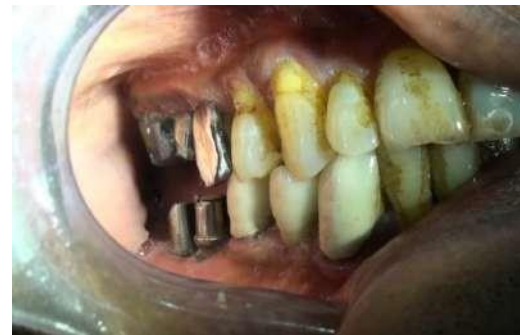

Fig. 13: Postoperative I/O view after 3 month

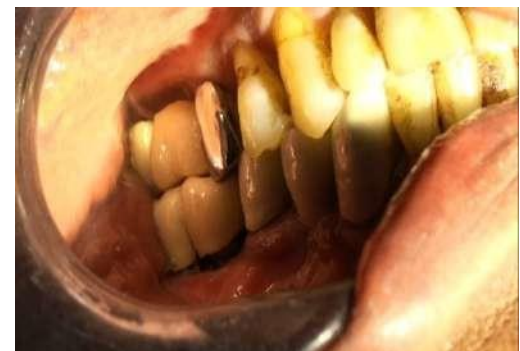

Fig. 14: Implant supported prosthesis

Case 3

A Lady of 46years old reported to the clinic with four (4 number) mono-cortical implants supported over denture (in the year 2001). Patient wanted fixed prosthesis for her lower Jaw. Her jawbones were severely resorbed. She was explained about bicortical implants and probable

complication of transposition of inferior dental nerve, which would be required during insertion of implants. Under general anaesthesia with five (5) number of single stage bicortical implants were inserted bilaterally in canine, premolar and molar region and one two stage conventional implant was inserted on right molar region.

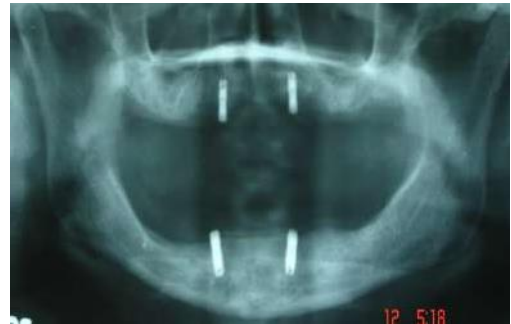

Fig. 15: Preoperative OPG

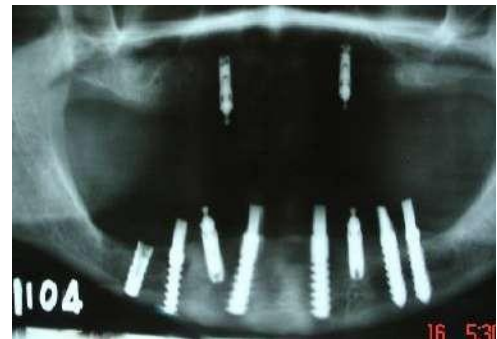


Fig. 16: Postoperative OPG

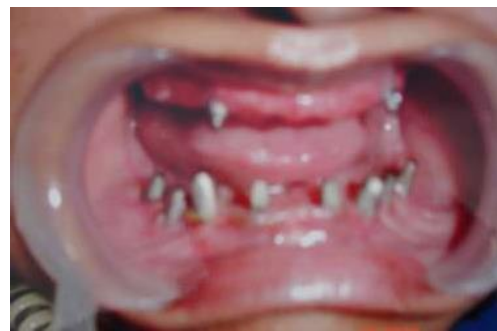

Fig. 17: I/O view after implant

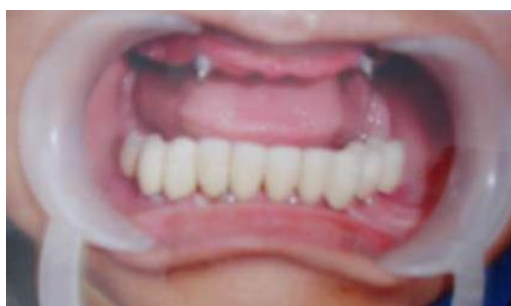

Fig. 18: Implant supported prosthesis

Surgical Procedure

The area was anaesthetized with 2% lignocaine with adrenaline (1:80000) in case no 1 and 2. No local anaesthesia was given in case no 3. A crestal incision given from 2nd molar region to distal to 2nd premolar region and a crevicular incision (where needed) was given along with the tooth surface (premolar teeth) and the releasing incision was extended up-to the mesial surface of the canine. Anterior based mucoperiosteal flap was carefully raised in the Canine-premolar region and the mental foramen was exposed and the neurovascular bundle indentified, flap extended up to the lower border of the mandible inferiorly. An oval shaped bur cut was given around the mental foramen keeping 5-6 mm distance anteriorly and distally extended upto 2nd molar.

Buccal cortical Osteotomy was performed with surgical bur (No.703) under copious irrigation. Cortical bone was separated with fine chisel. One piece cortical bone kept laterally within the soft tissue along with the IAN whereas in case of two piece osteotomy small fragment was kept along with the nerve and rest of the bony fragment kept in the normal saline. Nerve was made free from the canal very carefully with the help of specially designed instruments. Under direct vision the implants were installed keeping the nerve lateralized with periosteal elevator. The IAN was repositioned distolateral aspect of the implants passively. Additionally one groove were made distal to last implant, so that IAN can lodge in that groove. Buccal bone fragment was repositioned carefully without pressurising the IAN. Incision was closed with 4-0 resorbable suture.

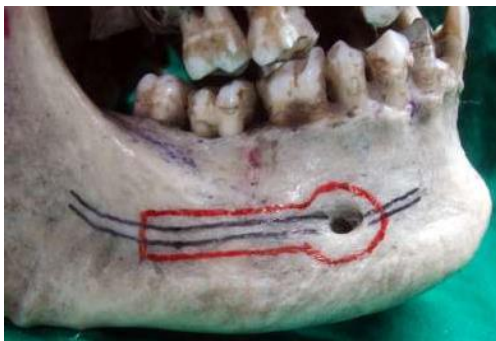


Fig. 19: Osteotomy cut design

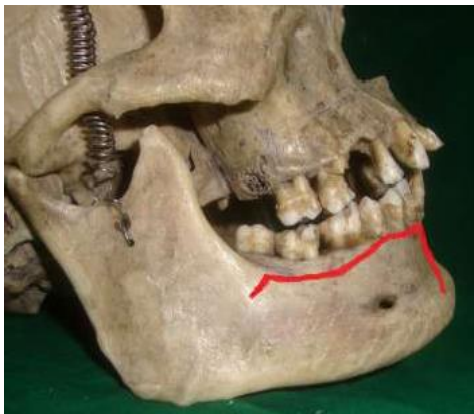


Fig. 20: Incision line

The patient was prescribed tab. (Amoxicillin 500 mg +

clavulanic acid 125mg). 1 tab 8 hourly for 7 days, tab. Paracetamol 1gm, 1 tab 8 hourly for 3 days, tab. Prednisolone 10mg, 1 tab 12 hourly with tapering dose for 5 days, chlorhexidine mouthwash thrice daily.

Twenty four hours postoperative follow up, patient had no complain of pain—localized edema was there. In the evaluation of sensorineural disorder, the patient suggested a mild paraesthesia in anterior part of lower lip. All the complaints subsided after 3 months postoperative period (case no. 1 & 2). In case no 3, the only complication, which occurred, was stiffness of the lower lip for the first 3 months which disappeared totally within 6 months of time, but no neurosensory deficiency or disturbances occurred. Till now she is doing well.

Discussion

Insertion of implants in posterior atrophic mandibular ridge is a challenge for surgeon due to anatomical presence of vital structures (IAN).

Some alternative treatment options can be used to avoid or bypass IAN: guided bone regeneration, short implants, laterally tilted implants installed near the nerve, cortical implants, distraction osteogenesis, and IAN repositioning.⁴⁻⁶ But in case of autogenous bone grafting, second surgical site is exposed to harvest graft.

Moreover, end result of bone grafting is unpredictable.⁷ Whereas, allogeneous bone graft is also suffering with unpredictable outcomes. Short implants have higher failure rates in terms of biomechanical properties⁸ and long term success rate is also in question. Tilted implants are used very rarely due to lack of availability of desired angulated abutments. Distraction osteogenesis is a long period complicated treatment procedure.⁹ Cortical implants also have lots of limitation and long-term data is not available. Therefore, IAN repositioning can be a viable alternative, but surgically challenging.

Besides implant installation in atrophic edentulous posterior mandible IAN repositioning is used for the following procedures:

- In orthognathic surgeries, such as lower border shaving and total mandibular subapical osteotomy.
- In the pre-prosthetic surgery.
- In the anastomosis and repairing of a disrupted IAN.
- Preservation of IAN in cancer surgery in the posterior mandible.

IAN repositioning has the following advantages while used for implant installation in atrophic posterior mandible:

- Longer implants can be placed
- Bicortical engagement by the implants provide better primary stability which reduces time for healing and loading.
- Desired number of implants can be placed as per requirement.

Disadvantages include mandible fracture, osteomyelitis and most importantly nuerosensory disturbances.

In case 1& case 2, nuerosensory disturbances (numbness of the concerned side) subsided within 3 months postoperative period. No other complications like

hyperesthesia, hypoesthesia etc. occurred in these two cases. The main reasons for nerve injury were traction injury, perineural oedema, disruption of microcirculation of the nerve during manipulation.¹⁰

Case no.3 was done under general anaesthesia, where bilateral nerve repositioning were undertaken. Following postoperative day though there was swelling, but no neurosensory deficiency was detected on either side of the nerve distribution area of the anterior mandible and lip. Therefore, we can say that general anaesthesia can reduce the chances of neurosensory disturbances in IAN repositioning cases. Local anaesthesia deposition to the site and needle injury during administering local anaesthesia close to the IAN may cause neurosensory disturbances.¹¹

Many authors suggested the use of piezoelectric bone cutting instruments with minimal damage to the neurovascular bundle.¹² A controversial topic is placing any biocompatible barrier like collagen membrane in between the nerve and implant placement. The rationality is that the membrane prevents thermal conductivity or biomechanical impact over the nerve.¹³ In our case, we didn't use any membrane or bonegraft in the nerve implant interface but placed in such a way so that adequate distance can be maintained. Additionally one groove were made distal to last implant, so that IAN can lodge in that groove. Some studies argue about the fixation of buccal cortical plate may compress the neurovascular bundle which may lead to paraesthesia.¹⁴ In our procedure, we have placed the buccal plate passively, not active fixation done.

For the analysis of the neurosensory function of IAN, the most commonly used test is two-point discrimination, as reported by several authors.¹⁵⁻¹⁷ Other objective tests were used such as the light touch test, the heat and cold test, pin prick test, and the pressure test, as reported by several authors.

In this study, a sensorineural disorder patient was assessed by the light touch test (with fine head of light cure bonding applicator) and needle prick test (no.26 gauge) to diagnose the severity of nerve fibers damaged by the surgical procedure. The tactile discrimination test was also conducted to delimit the area affected by sensory damage in case of hypoesthesia. Monitoring during the postoperative period was performed using the two-point discrimination test.

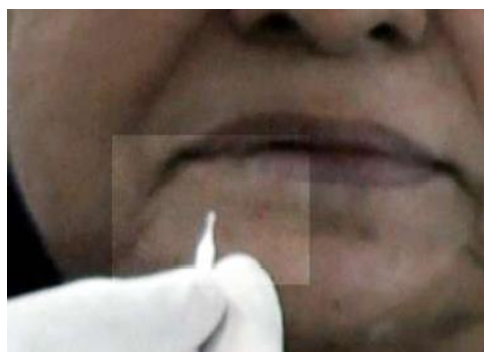

Fig. 21: Fine touch test

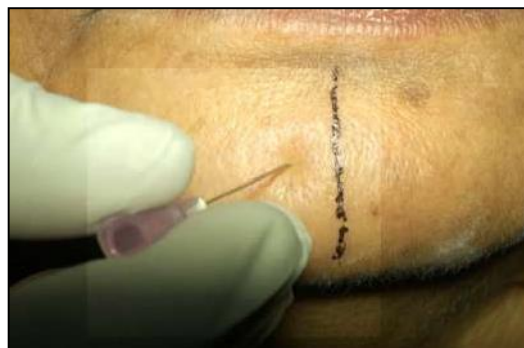

Fig. 22: Needle prick test

Conclusion

Demand for implant is increasing day by day, where patient wants fixed prosthesis even for the posterior mandible. Atrophic mandible require special attention where different implant systems are available but none of them are satisfying the requisite long term successful outcome. Therefore different surgical alternatives like bone grafting (both autogenous and allograft), fracture and repositioning of IAN, cortical implant, angular implant, short implant were introduced with limited success in the present scenario, IAN repositioning can be a viable option if it is done judiciously and probably general anaesthesia can be the better choice for desired predictable result.

Source of funding

None.

Conflict of interest

None.

References

1. Friberg B, Ivanoff CJ, Lekholm U. Inferior alveolar nerve transposition in combination with Br'anemark implant treatment," *International J Periodontics Restorative Dent*, 1992;12(6):440-9.
2. Alling CC. Lateral repositioning of inferior alveolar neurovascular bundle. *J Oral Surg* 1977;35(5):419.
3. Jensen O, Nock D. Inferior alveolar nerve repositioning in conjunction with placement of osseointegrated implants: a case report. *Oral Surg Oral Med Oral Pathol* 1987;63(3):263-8.
4. JYK Kan, J L Lozada, C J Goodacre, W H Davis, O Hanisch. Endosseous implant placement in conjunction neurosensory disturbance. *The Int J Oral Maxillofac Implants* 1997;12(4):463-71.
5. O. Jensen and D. Nock, "Inferior alveolar nerve repositioning in conjunction with placement of osseointegrated implants: a case report. *Oral Surg, Oral Med, Oral Pathol* 1987;63(3):263-8.
6. N. Ferrigno, M. Laureti, and S. Fanali. Inferior alveolar nerve transposition in conjunction with implant placement. *The Int J Oral Maxillofacial Implant* 2005;20(4):610-20.
7. R. M. S. Blahout, S. Hienz, P. Solar, M. H. Matejka, and C. W. Ulm. Quantification of bone resorption in the interforaminal region of the atrophic mandible. *Int J Oral Maxillofac Implant* 2007;22(4):609-15.
8. P. Proussaefs, "Inferior alveolar nerve transposing in a situation with minimal bone height: a clinical report. *J Oral Implantol*, 2005;31(4):180-5.
9. X.-X. Wang, X. Wang, and Z.-L. Li. Effects of mandibular distraction osteogenesis on the inferior alveolar nerve: an

- experimental study in monkeys. *Plast Reconstr Surg* 2002;109(7):2373–83.
10. Ali Hassani, Sarang Saadat, Roya Moshiri, Solaleh Shahmirzad, Amin Hassani. Nerve retraction during inferior alveolar nerve repositioning procedure: A new simple method and review of the literature. *J Oral Implantol* page 391; DOI: 10.5163/AAID-JOI-D-13-00108
 11. Harn SD, Durham TM. Incidence of lingual nerve trauma and postinjection complications in conventional mandibular block anesthesia. *J Am Dent Assoc* 1990;121:519.
 12. Kfoury FA, Duailibi MT, Bretos JLG. Piezoelectric surgery in implant dentistry: clinical applications. *RGO* 2009;57:121-6.
 13. Sethi A. Inferior alveolar nerve repositioning in implant dentistry: a preliminary report. *Int J Periodontics Restorative Dent* 1995;15(5):474-81.
 14. Mozsary PG, Syers CS. Microsurgical correction of the injured inferior alveolar nerve. *J Oral Maxillofac Surg* 1985;43(5): 353-8.
 15. JYK Kan, JL Lozada, CJ Goodacre, WH Davis, O Hanisch. Endosseous implant placement in conjunction with inferior alveolar nerve transposition: an evaluation of neurosensory disturbance. *Int J Oral Maxillofac Implant* 1997;12(4):463–71.
 16. A Morrison, M Chiarot, S Kirby. Mental nerve function after inferior alveolar nerve transposition for placement of dental implants. *J Can Dent Assoc* 2002;68(13):46–50.
 17. T T Dao, A Mellor. Sensory disturbances associated with implant surgery. *Int J Prosthodont* 1998;11(5):462–9.

How to cite this article: Biswas BK, Das B, Chakrabarty A. Repositioning of inferior alveolar nerve and implant placement in atrophic mandible -How far justified?. *J Oral Med, Oral Surg, Oral Pathol, Oral Radiol* 2019;5(4):106-11.