

Management of lower jaw avulsion with reconstruction of floor of mouth as a sequel-A case study

Sudhir Singh

Hon. IMA Professor (Academy of Medical Specialities- IMA) & Senior Consultant plastic surgery, Getwell Hospital, Varanasi Uttar Pradesh, India

***Corresponding Author: Sudhir Singh**

Email: s.sulekha@gmail.com

Abstract

The present report describes the planning and surgery as well as pitfalls and management of a patient with a rare near total mandibular avulsion injury. Avulsion injury of lower jaw can be managed by reposing it to normal site anatomically due to rich blood supply. However sometimes due to severe necrotizing infection or damaged vascular supply, we may lose some part as it gets devitalized specially at floor of mouth leading to oro cervical fistula. For reconstruction there are many techniques but still pectoralis major myocutaneous flap with skin grafting on other side is not only versatile but it is easy to perform and demands less skill. Such one case sequel is being discussed here which I came across.

Keywords: Lower avulsed jaw, Pectoralis major myocutaneous flap, Oro cervical fistula, Aesthetic, Floor of mouth reconstruction.

Aim

This article aimed to present a case of near total avulsion of mandible with attached soft tissue which occurred accidentally by getting injured falling in the well while being drunk. We see the importance of immediate stabilization and airway care and then going for facial reconstruction as required and to manage later complication like loss of floor of oral cavity due to infection. The reconstructive plastic surgeon has to properly assess the through and through defect of floor of mouth and even the tongue can be seen finding way through the defect to protrude out. Oral function may severely cripple the patient in terms of speech, mastication, oral transport and swallowing. The patient has deformity with loss of oral competence, drooling, and a very poor cosmetic outcome. We have to determine how best to restore form and function i.e. mandibular integrity and contour, and oral competence, mastication, oral transport, swallowing and speech. Mobility of the tongue is key to oral function. It is important always to maintain tongue mobility with a flap applied at base. Tongue length is more important than width. Avoid tethering of the tip of the tongue. Never suture the edge of the tongue to the gingiva. Avoid postoperative orocervical fistulae. Optimise cosmesis and function. Avoid pooling of secretions and food in the reconstructed portion.

The Case History

The 40 years male local petty shopkeeper fell in the well as he was drunk and had the avulsed lower jaw

due to severe facial trauma which was fixed back by us after tracheostomy preserving the airway and proper resuscitation. The wound was thoroughly cleaned and devascularised tissue were debrided to minimum extent and mandibular bone fractures were plated and soft tissue were brought back and sutured in layers. Patient was alright and was discharged after two weeks after removal of tracheostomy tube.

However after few days started developing serous then purulent discharge from floor of mouth and within a week time had loss of the complete floor of mouth due to infection leading to necrosis. Tongue used to protrude from cervico oral fistula which needed immediate repair.

Floor of the mouth was reconstructed after one month of previous surgery of reposition of the avulsed jaw and miniplating to fix the mandibular fracture bilaterally at extreme ends. Now the island pectoralis major myocutaneous flap was harvested and passed under the tunnel of cervical skin flap to form the floor of mouth. The raw area of PMMC flap on exposed outer surface was skin grafted. Proper antibiotic care and Ryles tube feeding was done for three weeks more and the result was good in both functional and cosmetic wise. Long follow up after one and half years has been excellent.

Surgical anatomy

The Floor of mouth is a horseshoe-shaped area that is confined peripherally by the inner aspect (lingual surface) of the mandible. It extends posteriorly to where the anterior tonsillar pillar meets the tonsillo

lingual sulcus, and merges medially with under-surface of the oral tongue. It has a covering of delicate oral mucosa through which the thin walled sublingual/ranine veins are visible. The frenulum is a mucosal fold that extends along the midline between the openings of the submandibular ducts. The mylohyoid muscle forms the diaphragm of the mouth.

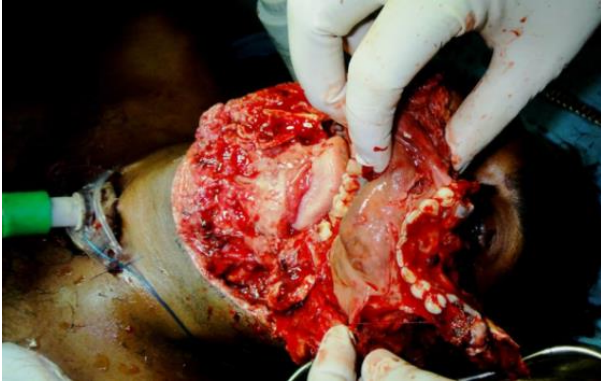

Fig. 1: Near total avulsion of lower jaw

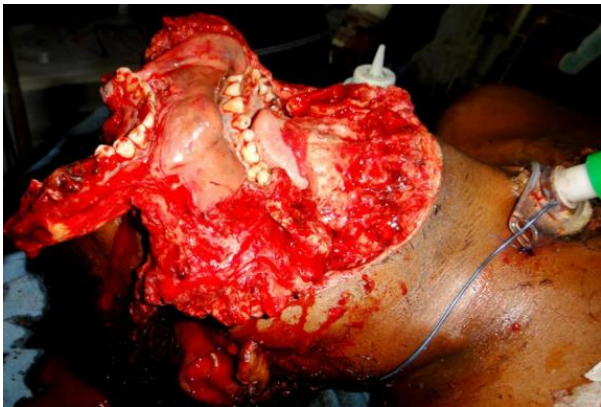

Fig. 2: Near total avulsion of lower jaw- preoperative

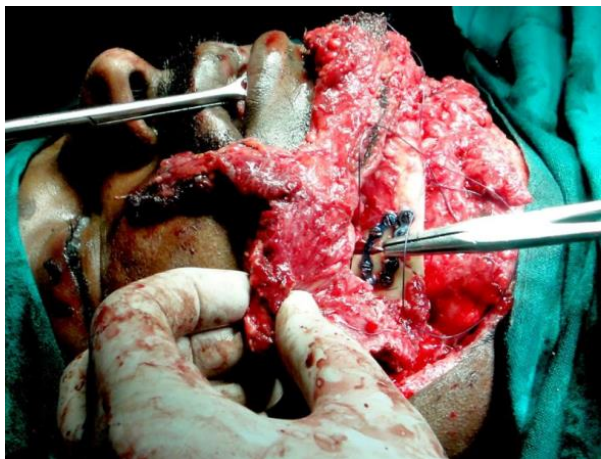


Fig. 3: Repositioning of avulsed tissue and plating of fractures both sides

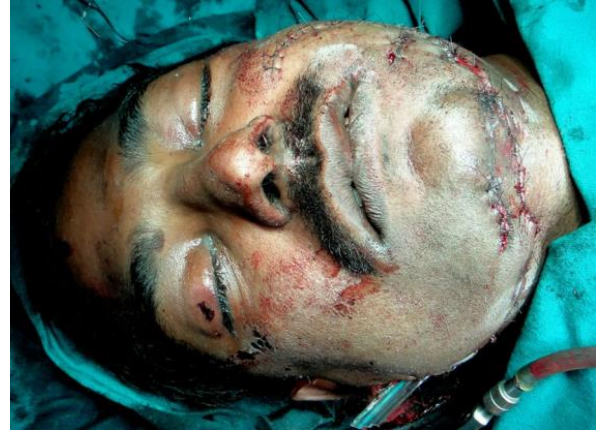

Fig. 4: Post op after reconstruction of avulsed lower jaw

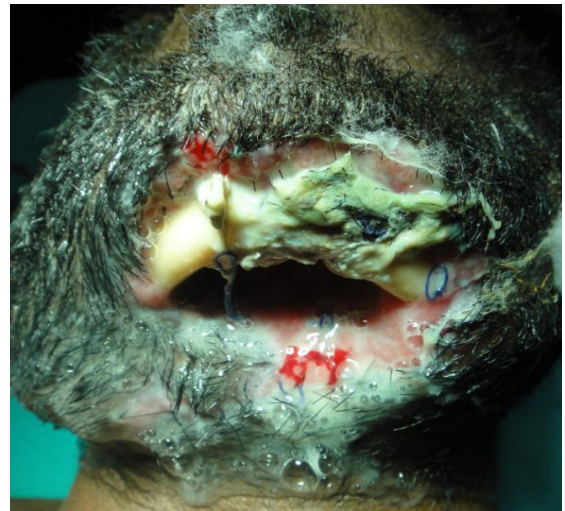

Fig. 5: Floor of mouth necrosed and lost

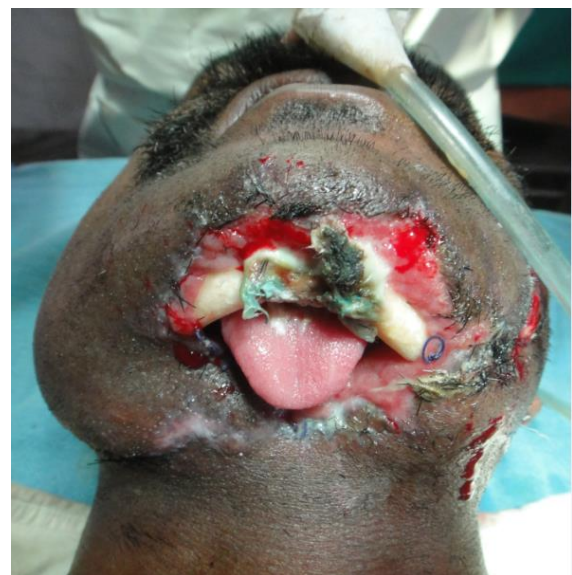

Fig. 6: Tongue protruding from orocervical fistula

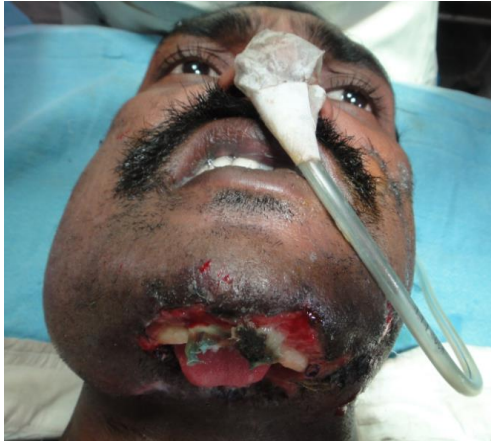

Fig. 7: The oro cervical fistula complication

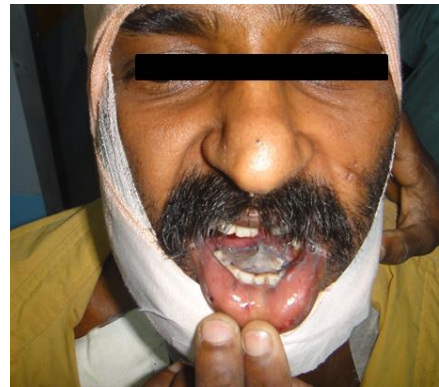

Fig. 11: After 2 months

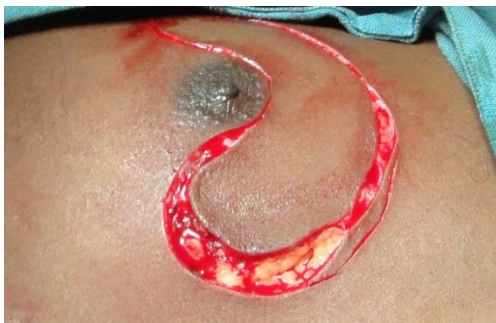

Fig. 8: Design of PMMC

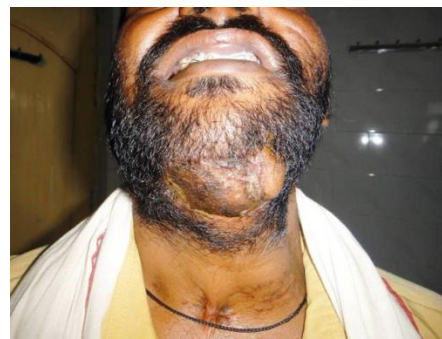

Fig. 12: After 1 year

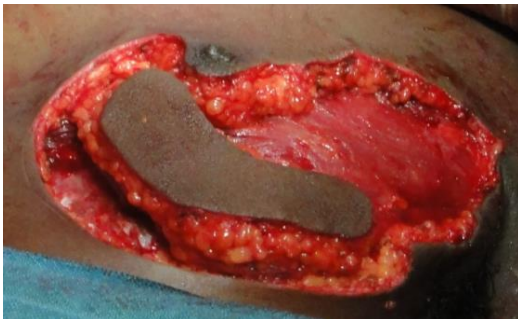

Fig. 9: PMMC harvesting

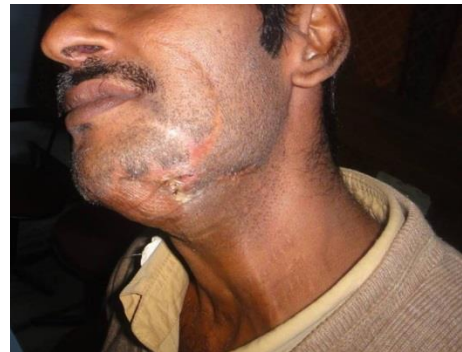

Fig. 13: After 2 years

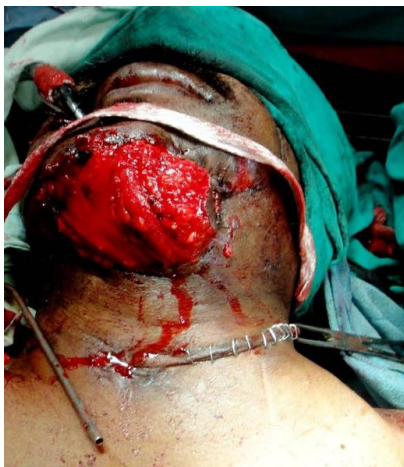

Fig. 10: Floor of mouth Reconstructed with PMMC

Discussion

Avulsions of mandible are among the most devastating lesions observed in maxillofacial traumas. They present an important health problem because of the high risk of morbidity related to deformities that cause functional limitations and aesthetic result from high energy effects, which cause complete or partial separation of the mandibular bone of the face. Maxillofacial injuries range from simple to complex and can involve the skin, soft-tissues as well as bone, resulting in fractures. Although, several cases of severe crush injury of the lower jaw have already been presented in literature but near total avulsion of mandible with attached soft tissue with its innate blood

supply and its later sequel of any occurring complication managed successfully of restoring fully the patient aesthetic profile has been reported very rarely.

The surgical team must master a wide array of reconstructive techniques to secure the best functional and cosmetic outcomes. We have reconstructive ladder according to severity of loss of floor of mouth.

No repair: Small and/or superficial resections above the mylohyoid that do not communicate with the neck dissection may be left open to heal like a tonsillectomy wound. Resist the temptation to suture such defects as it may alter the shape of the tongue or fix the tongue to the anterior FOM.

Primary closure: Avoid tethering or distorting the tongue.

Split skin graft: This may be used to cover a defect that could otherwise be left open. The skin is sutured to the margins of the defect with absorbable sutures, the ends of which are left a few centimetres long. A bolster of antiseptic impregnated gauze is placed over the skin graft and tied down with the long sutures. The bolster is removed after about 5 days.

Buccinator myomucosal flap: This is an excellent flap for both anterior and lateral FOM defects as it has the same physical qualities as tissues of the FOM. The pedicle however crosses the mandible and is therefore best suited for edentulous patients, patients with missing teeth, or who have undergone marginal mandibulectomy.

Anterolateral free thigh flap: It is less pliable than the radial free forearm flap and is only suitable for oral reconstruction in patients with thin thighs.

Nasolabial flap: The nasolabial flap can be used both for lateral and anterior FOM defects reconstruction. An inferiorly based pedicled NLF is a reliable flap for the reconstruction of small and medium sized defects in the oral cavity. The flap can be best utilised for old edentulous and high risk patients where it can be used as a single stage procedure which is particularly useful in those types of patients.

Submental artery island flap: This has no option here.

Supraclavicular flap: This has excellent properties for the floor of mouth, being thin and pliable like a radial free forearm flap.

Radial free forearm flap: This is a popular choice for FOM repair as the flap is thin and pliable.

Pectoralis major flap: This flap is a reliable and versatile flap for head and neck reconstructions. When

microvascular reconstruction is not available, it is the most important reconstruction tool, and it is also very useful in elderly patients or in those with poor clinical conditions.

Conclusion

Mandibular traumas are frequent injury of maxillofacial skeleton due to the mandible's prominence and relative lack of support. Maxillofacial injuries can be complex and can involve the skin and soft-tissues as well as bones resulting in fractures. Although, several cases of severe crush injury of the lower jaw have already been presented but this type of avulsion of mandible with later reconstruction of floor of mouth as a complication has rarely been reported. As with any facial fracture, consideration must be given for the need of emergency treatment to secure the airway or to obtain hemostasis if necessary before initiating definitive treatment. We present this case of lower jaw avulsion with soft-tissue attached and its later complication in forty years male patient following trauma, which was managed and reconstructed successfully.

Source of funding

None.

Conflict of interest

None.

References

1. Deleyiannis F, Dunklebarger J, Lee E, Gastman B, Lai S, Ferris R et al, Reconstruction of the marginal mandibulectomy defect: an update. *Am J Otolaryngol Head Neck Med Surg* 2007;28(6): 363-6.
2. Chen W, Dong Z, Cao G, Liu B, Meng Z, Zhang S et al. Reconstruction of anterior floor of mouth defects by the local mandible myofascial flap following cancer ablation: a pilot study. *J Plast Reconstr Aesthet Surg* 2013;66(9):1238-42. doi:10.1016/j.bjps.2013.04.008. Epub 2013 May 10.
3. McLean JN, Carlson GW, Losken A. The pectoralis major myocutaneous flap revisited: a reliable technique for head and neck reconstruction. *Ann Plast Surg* 2010;64:570-3.
4. Passi D. Total avulsion of mandible in maxillofacial trauma. *Ann Maxilla fac Surg* 2014;4(1):115-8.
5. Ivo cava Icante Pita Neto. A patient with severe lower face degloving injury. *J Craniofac Surg* 2018;29(6).

How to cite: Singh S. Management of lower jaw avulsion with reconstruction of floor of mouth as a sequel- A case study. *IP Int J Aesthet Health Rejuvenation* 2020;3(1):29-32.