

## A study of tumours, tumour like lesions and cysts of epidermis and its appendages

Neela Patel<sup>1</sup>, Tarul Suthar<sup>2,\*</sup>, Hiren Suthar<sup>3</sup>, Anisha Arora<sup>4</sup>

<sup>1</sup>Professor and Head, <sup>2,3</sup>rd year Resident, <sup>4</sup>2nd Year Resident, Dept. of Dermatology, AMC MET Medical College, Ahmedabad, Gujarat, India

**\*Corresponding Author:**  
Email: tarulsuthar@gmail.com

### Abstract

**Introduction:** Skin tumors arise due to proliferation of group of cells having differentiation towards single or multiple components of skin. Based on their primary site of involvement, they can be divided into neoplasms with epithelial differentiation, melanocytic neoplasms, soft tissue neoplasms, neural tumors and tumors of subcutaneous tissue.

**Aims:** 1. To evaluate the demographic and clinico-pathological patterns of tumors, tumor like lesions & cysts of epidermis and its appendages; 2. To compare the profile of patients with appendageal tumors against the total epidermal tumors.

**Materials and Methods:** Prospective study, from July 2012 to November 2014, done at tertiary care center.

**Results:** During the period of three years, there were 306 cases which presented as skin tumors and out of these, 57 happened to be cysts and the remaining 249 were tumors of skin. Out of 249 cases, 205 were diagnosed as benign, 23 were of premalignant and 21 as malignant tumors of skin constituting 82.32%, 9.24% and 8.43% respectively. There was male predominance with male to female ratio of 1.28:1. In this study benign keratinocytic tumors formed majority (49.27%) followed by melanocytic (31.32%) and appendageal tumors (10.44%). Among keratinocytic tumors maximum cases were of seborrheic keratosis (32.19%), among melanocytic tumors maximum cases were of acquired melanocytic nevus (21.40%) while nevus sebaceous (4.87%) formed majority among appendageal tumors. In present study malignant keratinocytic tumors formed majority (95.23%) followed by melanocytic (4.76%). Among keratinocytic tumors maximum cases were of BCC (57.14%).

**Conclusion:** The diagnosis of skin tumors presents unique difficulties due to wide variety of tumors and the complicated nomenclature. The study of the adnexal tumours is interesting, fascinating and challenging because of wide range of differentiation.

**Keywords:** Skin tumours, Benign tumors, Cysts, Benign keratinocytic tumors, Melanocytic tumors, Appendageal tumors.

### Introduction

The complexity of the cellular composition of the skin means that the range of tumors that can arise within it is very wide. Based on their primary site of involvement, they can be divided into keratinocytic, melanocytic, appendageal and soft tissue tumors. The epidemiology, pathology and course of tumors vary depending on the origin of the cells.

The ultraviolet radiation (UVR) in sunlight is the primary etiologic agent for all skin carcinomas. The powerful carcinogenic activity of UVR is attributable to its ability to damage DNA and cause mutations. Petroleum products and grease, as well as insecticides, herbicides, and fungicides are particularly pathogenic for SCC, while fiberglass and dry cleaning agents increase the incidence of BCC.<sup>1</sup>

Keratinocytic tumors are derived from epidermal and adnexal keratinocytes. They account for approximately 90% of all skin malignancies of which approximately 70% are basal cell carcinoma.<sup>2</sup> Non-melanoma skin cancer (NMSC) is the most common human cancer, comprises of basal cell carcinoma (BCC) and squamous cell carcinoma (SCC) of the skin. Ultraviolet radiation (UVR) is by far the most important and best understood risk factor for NMSC development. Cysts are common cutaneous lesions. The definitive diagnosis of a cyst requires histologic examination, as many other dermal and subcutaneous tumors can form cyst-like nodules. Cysts can be classified by anatomic

location (as they may occur in virtually any organ of the body), by embryologic derivation, or by histologic features.

The skin appendageal tumors encompass a wide variety of tumors clinically presenting as papules and nodules and with histologically distinct features. They originate from undifferentiated pluripotent stem cells and finally differentiate to specific tumors influenced by genetics, local vascularity, and microenvironment of epidermis and dermis.<sup>3-5</sup> They are basically classified into four groups: tumors with differentiation towards hair follicles, sebaceous glands, eccrine or apocrine glands.<sup>6</sup> They are usually missed clinically and often confirmed by histopathology. Immunohistochemistry may help in confirmation of the diagnosis.<sup>7</sup>

### Materials and Methods

The present study was conducted in the outpatient department of dermatology, venereology & leprology of a teaching hospital. 306 patients presenting with clinical impression of tumor, tumor like lesion and cyst of epidermis and appendages during July 2012 to November 2014 were included in the study.

In all the patients, detailed clinical history in form of age, sex, duration of disease and site of lesion was taken and was recorded. Also detailed clinical examination was carried out and clinical photographs were taken in all patients. Before doing any intervention informed consent was obtained from all

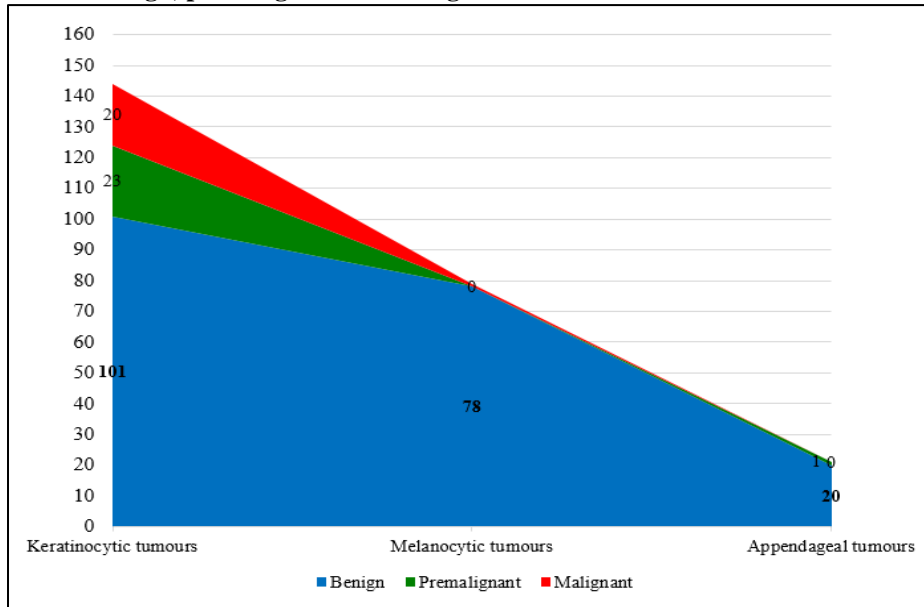
patients. Biopsy was taken to confirm diagnosis in case of clinical diagnostic difficulty and also to rule out malignant transformation in some tumors.

cases which presented as skin tumors and out of these, 57 happened to be cysts and the remaining 249 were tumors of skin. The study showed male predominance with the male to female ratio of 1.28:1.

**Results**

During the period of three years, there were 306

**Chart 1: Incidence of benign, premalignant and malignant skin tumors**



Out of 249 cases, 205 were diagnosed as benign, 23 were diagnosed as premalignant and 21 as malignant tumors of skin constituting 82.32%, 9.24% and 8.43% respectively. The ratio of benign to malignant tumors was 9.76:1. Out of 249 skin tumors, benign keratinocytic tumors were most common (40.56%),

followed by benign tumors of melanocytes (31.32%), benign tumors of appendages (10.44%), premalignant keratinocytic tumors (9.24%), malignant keratinocytic tumors (8.03%) and malignant melanoma (0.4%).

The study showed there was male predominance with the male to female ratio of 1.28:1.

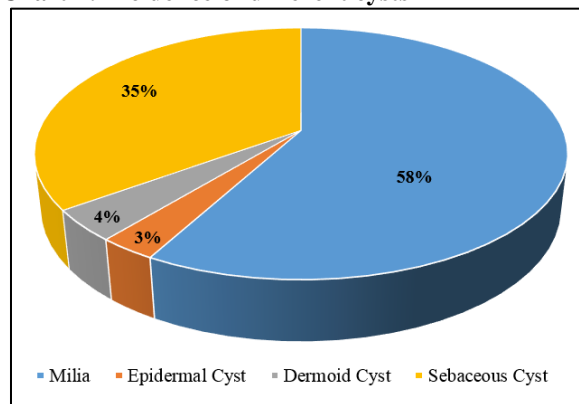
**Table 1: Incidence of different benign tumors**

Incidence of Different Benign Tumors	No of Cases	Percentage (%)
<b>Keratinocytic Tumors</b>	<b>101</b>	<b>49.27</b>
Seborrheic keratosis	66	32.19
Lichen striatus	12	5.85
Keratoacanthoma	2	0.98
Verrucous epidermal nevus	12	5.85
Ichthyosis hystrix	1	0.48
Becker's nevus	7	3.41
ILVEN	1	0.48
<b>Melanocytic Tumors</b>	<b>78</b>	<b>38.04</b>
Acquired melanocytic nevus	44	21.46
Congenital melanocytic nevus	29	14.14
Lentigo simplex	5	2.43
<b>Appendageal Tumors</b>	<b>26</b>	<b>12.68</b>
Sebaceous adenoma	3	1.46
Syringoma	10	4.87
Eccrine poroma	1	0.48
Trichoepithelioma	1	0.48
Chondroid syringoma	1	0.48
Nevus sebaceous	9	4.39
Apocrine hydrocystoma	1	0.48
<b>Total</b>	<b>205</b>	<b>100</b>

In present study benign keratinocytic tumors formed majority (49.27%) followed by melanocytic (31.32%) and appendageal tumors (10.44%). Among keratinocytic tumors maximum cases were of seborrheic keratosis (32.19%), among melanocytic tumors maximum cases were of acquired melanocytic nevus (21.40%) while syringoma (4.87%) formed majority among appendageal tumors.

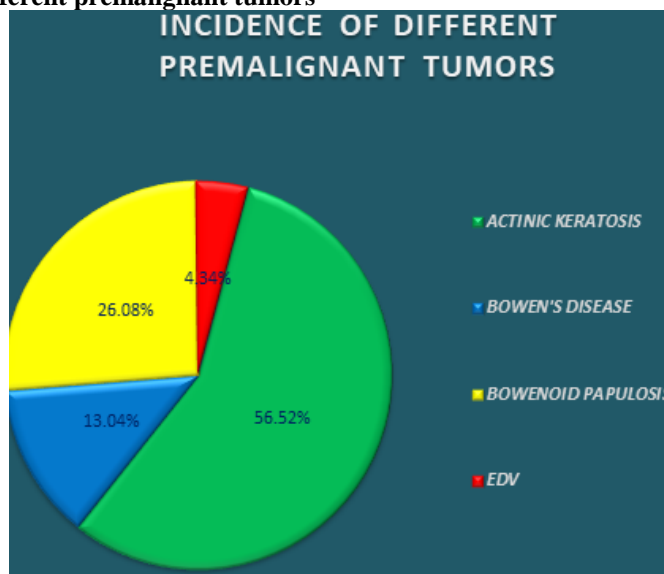
Amongst premalignant skin lesions, maximum cases were of actinic kearatosis (56.52%) followed by bowenoid papulosis (26.08%).

**Chart 2: Incidence of different cysts**



Amongst cysts, maximum cases were of milia (57.89%) followed by sebaceous cyst (20%), epidermal cyst (3.50) and dermoid cyst (3.5%).

**Chart 3: Incidence of different premalignant tumors**



Amongst premalignant skin lesions, maximum cases were of actinic kearatosis (56.52%) followed by bowenoid papulosis (26.08%).

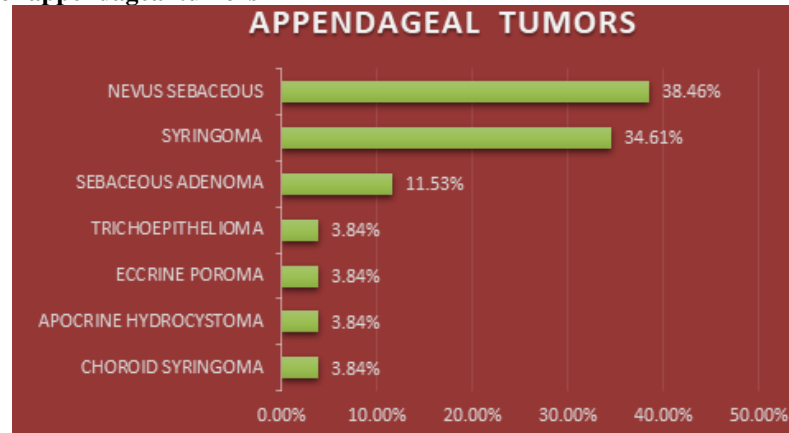
**Table 2: Incidence of different malignant tumors**

	Number of cases	Percentage
Keratinocytic Tumors	20	95.23
Squamous Cell Carcinoma	8	38.09
Basal cell carcinoma	12	57.14
Melanocytic Tumors	1	4.76
Malignant melanoma	1	4.76
<b>Total</b>	<b>21</b>	<b>100</b>

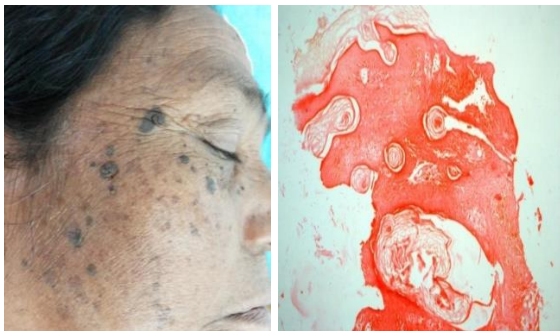
In present study malignant keratinocytic tumors formed majority (95.23%) followed by melanocytic

(4.76%). Among keratinocytic tumors maximum cases were of BCC (57.14%) followed by SCC (38.09).

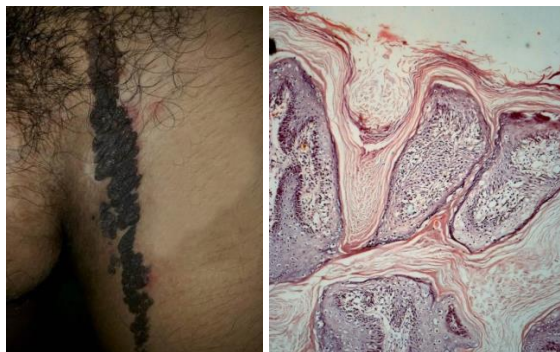**Chart 4: Incidence of appendageal tumors**



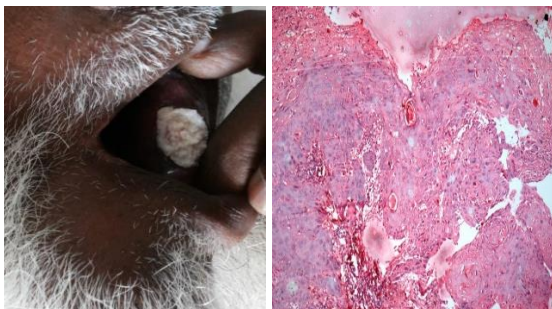In present study maximum cases were of nevus sebaceous (38.46%) and syringoma (34.61%).



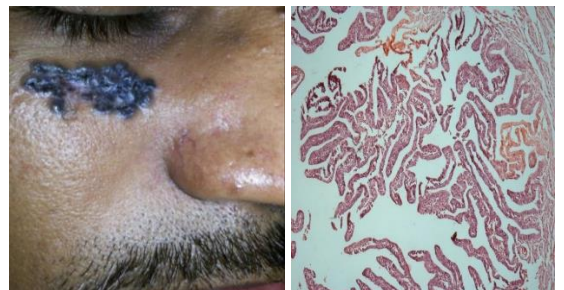
**Fig. 1: Seborrheic keratosis**



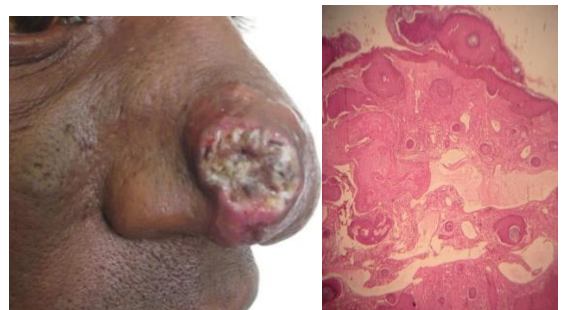**Fig. 2: Inflammatory linear verrucous epidermal nevus**



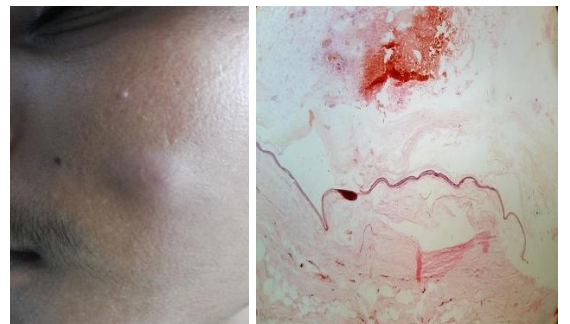
**Fig. 3: Squamous cell carcinoma**



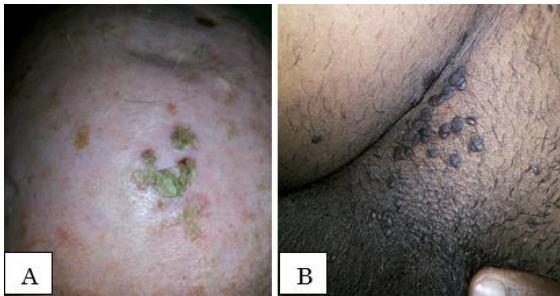**Fig. 4: Basal cell carcinoma**



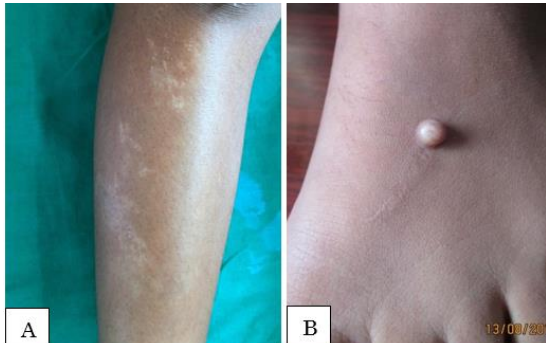**Fig. 5: Keratoacanthoma**



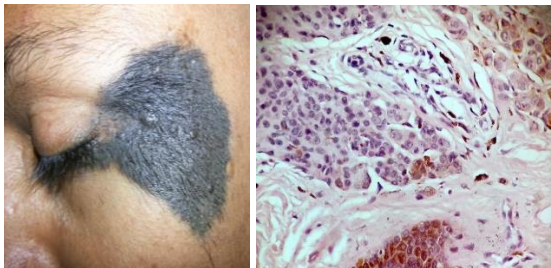
**Fig. 6: Sebaceous cyst**



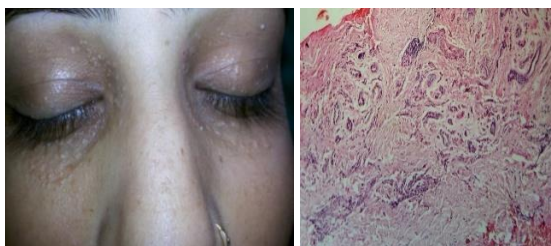
**Fig. 7A: Actinic keratosis; (B) Bowenoid papulosis**



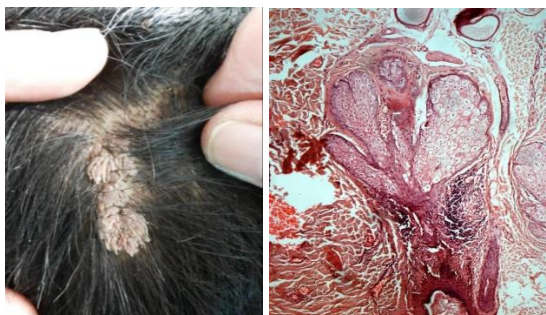
**Fig. 8A: Lichen striatus; (B): Implanted dermoid cyst (Epidermal inclusion cyst)**



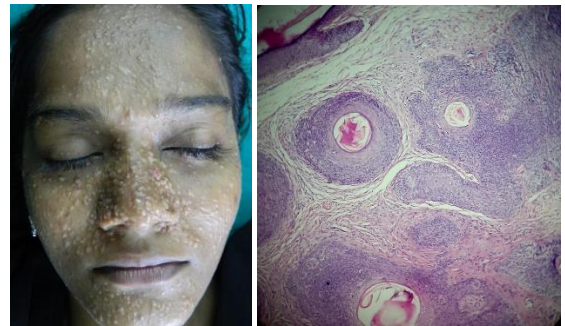**Fig. 9: Congenital melanocytic nevus**



**Fig. 10: Syringoma**



**Fig. 10: Nevus sebaceous**



**Fig. 11: Trichoepithelioma**

**Discussion**

Due to complexity of nomenclature of skin tumours, sometimes it is very difficult to categorize them. Certain skin tumours are easily identified clinically, while others can only be diagnosed by histopathology, immunohistochemistry or other techniques.

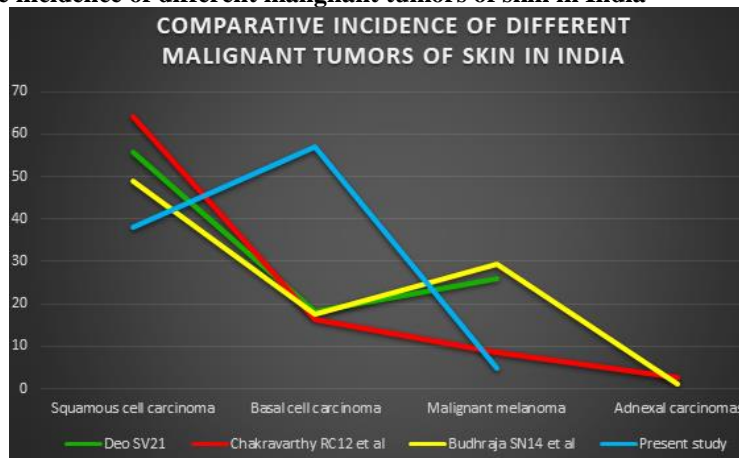
During the study period, there was a total of 249 cases of skin tumours and 57 cases of cysts. Among these, skin cancers were 21 constituting 8.43%. The ratio of benign (205) to malignant tumours (21) was 9.7:1, which is similar to a study done by Dr Balaji Govindan.<sup>8</sup> The ratio of benign keratinocytic (101) to malignant counterpart (20) was 5:1. The ratio of benign melanocytic (78) to malignant (1) counterpart was 78:1.

Out of 249 skin tumours, benign keratinocytic tumours were most common (40.56%), followed by benign tumours of melanocytes (31.32%), benign tumours of appendages (10.44%), premalignant keratinocytic tumours (9.24%), malignant keratinocytic tumours (8.03%) and malignant melanoma (0.4%).

Among benign keratinocytic tumours maximum cases were of seborrheic keratosis (65.34%) and most cases were seen after 40 years of age (78.78%). Among benign melanocytic tumours maximum cases were of acquired melanocytic nevus (56.41%) and most cases were seen between 3<sup>rd</sup> and 4<sup>th</sup> decade (54.54%).

Appendageal tumours are relatively rare and in some instances it is important to diagnose them as their presence may indicate association with genetic syndrome, like Muir-Torre syndrome associated with sebaceous tumours, Cowden's syndrome with trichilemmomas.<sup>9</sup> The clinical features of appendageal tumours are perplexing many times, when histopathology is the only way to get it differentiated from similar types. In present study, among benign adnexal tumours maximum cases were of syringoma (34.61%). Most cases were seen in 3<sup>rd</sup> decade.

**Chart 5: Comparative incidence of different malignant tumors of skin in India**



Out of all malignant tumors, the incidence of basal cell carcinoma was highest (57.14%) in our study, which was consistent with the study done by Shivanand Gundalli et al,<sup>10</sup> Shilpa V. Uplaonkar et al.<sup>11</sup> & Dr Balaji Govindan.<sup>8</sup> BCC is common in elderly population. The reason behind more number of BCC cases in our study was that peak incidence was between 5<sup>th</sup> & 6<sup>th</sup> decade. The incidence of BCC in other studies ranged from 12% (Chakravarthy RC et al)<sup>12</sup> to 30% (Paymaster et al).<sup>13</sup>

In the present study majority of cases (91.6%) were seen on head and neck which was consistent with the

findings of Solanki RL98 et al (94%), Chakravarthy RC et al.<sup>12</sup> (90%) and Budhraja SN et al<sup>14</sup> (78%). Majority of these were seen on infraorbital region.

In the present study male to female ratio was 2:1. Soalnki RL et al<sup>15</sup> found a male to female ratio of 1.26:1 and Budhraja SN et al.<sup>14</sup> found a male to female ratio of 2.6:1.

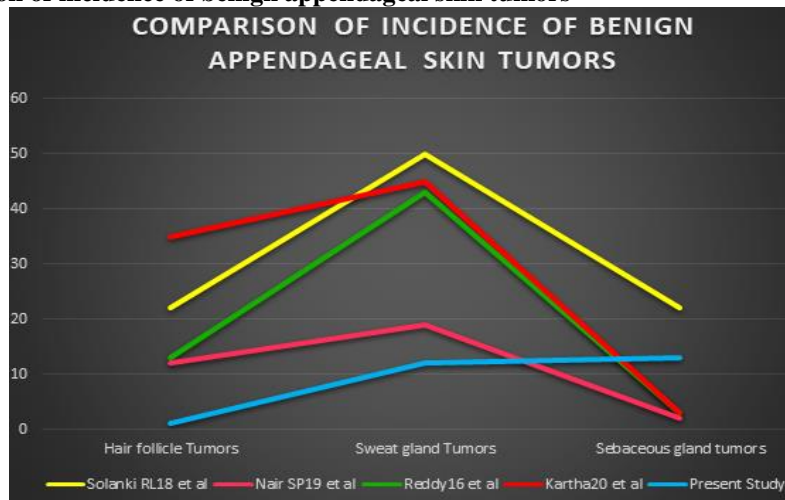
The average age was 60.9 years and peak incidence was in 7th decade in the present study. In the study by Solanki et al<sup>15</sup> the average age was 54 years and peak incidence was in 5th decade.

**Table 3: Comparison of incidence of adnexal tumours**

	Benign		Malignant		Total No of cases
	No	%	No	%	
Reddy 16 et al	59	69.4	26	30.6	85
Vaishnav and Dharkar 17	43	89.6	5	10.4	48
Present study	26	100	-	-	26

In the present study, benign tumors formed the majority (100%). In the study by Vaishnav and Dharkar<sup>17</sup> and Reddy<sup>16</sup> et al, benign tumors formed the majority.

**Chart 6: Comparison of incidence of benign appendageal skin tumors**



The occurrence of sweat gland tumors (50%) was higher in the present study which was similar to the studies done by Solanki RL et (53.2%), Nair SP et al<sup>19</sup> (57.56%) and Kartha et al<sup>20</sup> (54.2%).

In present study there were 57 cases of cysts. Among these maximum cases were of milia (57.89%) and most cases were seen in 2nd and 3rd decade (72.72%).

### Conclusion

Skin tumors constitute a small but significant proportion of patients with cancer. The skin is a complex organ. Because of its complexity a wide range of diseases can develop from the skin including tumors from surface epidermis, epidermal appendages and dermal tissue.

Histopathological study is one of the most valuable means of diagnosis and classification in dermatopathology and the diagnosis of skin tumours can be done by correlating clinical features, gross and histological appearances. Assessment of architectural and cytomorphologic characteristics as well as determination of which normal adnexal structures; the differentiation of the tumor most closely resembles are the cornerstones of microscopic evaluation.

The diagnosis of skin tumors presents unique difficulties, in part, related to the wide variety of tumors and the complicated nomenclature. The study of the adnexal tumours is interesting, fascinating and challenging because of wide range of differentiation.

### References

- Ziegler A. Mutation hotspots due to sunlight in the p53 gene of nonmelanoma skin cancers. *Proc Natl Acad Sci U S A*. 90:4216,1993 [PMID:8483937].
- LeBoit PE, Burg G, Weedon D and Sarasin A. Pathology and genetics of skin tumours. In World health organisation classification of tumours. IARC press. Lyon, 2006.p.9-164.
- Mehregan AH. The origin of the adnexal tumors of the skin: A viewpoint. *J Cutan Pathol*. 1985;12:459-67.
- Wong TY, Suster S, Cheek RF, Mihm MC Jr. Benign cutaneous adnexal tumors with combined folliculosebaceous, apocrine and eccrine differentiation: Clinicopathological and immunohistochemical study of eight cases. *Am J Dermatopathol*. 1996;18:124-8.
- Brownstein MH. The genodermatology of adnexal tumors. *J Cutan Pathol*. 1984;11:457-65.
- Requena L. Neoplasms with Apocrine Differentiation. Philadelphia, Lippincott-Raven, Ardor Scribendi, 1997.
- Penneys NS. Immunohistochemistry of adnexal neoplasms. *J Cutan Pathol*. 1984;11:357-60.
- Balaji Govindan, Clinico-Pathological Study of Skin Epidermal and Appendageal tumors, *IJSR*. 2016;5(2).
- Khandpur S, Ramam M. Skin Tumors. In: Valia RG, Valia AR, editors. IADVL Text book of Dermatology. 3rd ed. Mumbai: Bhalani Publishing House; 2008. pp. 1475–38.
- Gundalli S, Kolekar R, Kolekar A, Nandurkar V, Pai V, Nandurkar S. Study of basal cell carcinoma and its histopathological variants. *Our Dermatol Online*. 2015;6(4):399-403.
- Shilpa V. Uplaonkar. Histopathological Study of Tumours of Epidermis and Epidermal Appendages. *Indian Journal of Pathology*. 2017;6(2).
- Charkravorthy RC and Choudhuri DR. Malignant neoplasms of the skin in Eastern India. *The Indian Journal of Cancer*. 1968;5:133-144.
- Paymaster, J.C., Talwalkar, G.V. & Gangadharan, p. (1971) Carcinomas and malignant melanomas of the skin in Western India *J R Coll Surg Edinb.*, 16, 166.
- Budharaja SN, Pillai VCV, Periyannagam WJ, Kaushik SP and Bedi BMS. Malignant neoplasms of skin in Pondicherry- a study of 102 cases. *The Indian Journal of Cancer*. 1972:284-295.
- Solanki RL, Arora HL, Anand VK, Gaur SK, Gupta R. Basal cell epithelioma (A clinicopathological study of 172 cases), *Indian J Dermatol Venerol Leprol*. 1989(55):33-43.
- Reddy KM, Veliath AJ, Nagarajan S, Arora AL. A clinicopathological study of adnexal tumours of skin. *Indian J Med Res*. 1982;75:882-889.
- Vaishnav VP, Dharkar DD. Adnexal tumors of skin. *Indian J Pathol Bacteriology*. 1974;17:33-8.
- Solanki RL, Anand VK. Neoplasms of sweat gland. *Indian J of Dermatol Venerol Leprol*. 1989;55:108-112.
- Nair SP. A clinicopathological study of skin appendageal tumours. *Indian J of Dermatol Venerol Leprol*. 2008;74:108-550.
- Kartha CC, Shankar SK, Bhuyan UN. Benign mixed tumor of skin—a histopathologic study of 7 cases. *Indian J Pathol Microbiol*. 1980;23:1-6.
- Deo SV, Samaiya A, Shukla NK, Mohanti BK, Raina V, Purkayastha J, Bhutani M, Kar M, Hazarika S, Rath GK. Breast conservation therapy for breast cancer: patient profile and treatment outcome at a tertiary care cancer centre. 2005;18(4):178-81.

**How to cite this article:** Patel N, Suthar T, Suthar H, Arora A. A study of tumours, tumour like lesions and cysts of epidermis and its appendages. *Ind J Clin Exp Dermatol*. 2018;4(3):194-200.