

## Evaluation of efficacy and safety of modified technique of auto wart implantation in the treatment of multiple, recurrent and recalcitrant warts

Mukunda Ranga Swaroop<sup>1,\*</sup>, Belagola Dasegowda Sathyanarayana<sup>2</sup>, Periasamy Vasudevan<sup>3</sup>, Aneesa<sup>4</sup>, Priyanka Kumari<sup>5</sup>, Jigalikoppa Raghavendra<sup>6</sup>

<sup>1</sup>Associate Professor, <sup>2</sup>Professor & Head, <sup>3,4,5,6</sup>Junior Resident, Department of Dermatology, Adichunchanagiri Institute of Medical Sciences, BG Nagara Nagamangala Taluk, Mandya

**\*Corresponding Author:**

Email: mrswaroop79@gmail.com

---

### Abstract

**Background:** Multiple recurrent warts affect patient's quality of life by causing physical and psychological discomfort. Common treatment modalities are painful, cause scarring, have high recurrence rates and are impractical for treatment of multiple lesions. Immune stimulation by exposing the viral antigens to body's immune system forms an ideal modality of treatment. Auto wart implantation works under this principle.

**Aim:** To evaluate the safety and efficacy of modified technique of auto wart implantation in the treatment of multiple recurrent recalcitrant warts.

**Methods:** A total of 40 patients with multiple recurrent cutaneous warts were enrolled in this prospective open labelled study. The donor tissue was harvested by just paring the wart, instead of taking a part of wart tissue. The pared tissue was implanted into the sub cutis. Patients were followed up once in 2 weeks for one month and then monthly for 3 months. Patients were evaluated with lesion count at each visit and the response to the treatment was assessed at the end of 12 weeks. The resolution of all warts within 3 months after the procedure was considered successful.

**Results:** All 40 patients with multiple warts (male: female = 29:11) were available for follow-up. At the end of 3 months, 28 patients (75%) showed complete clearance of warts, 9 patients (22.5%) had partial clearance and one patient showed no improvement. One patient developed erythematous nodule at the implantation site.

**Conclusion:** Modified technique of auto implantation of wart employing the pared stratum corneum tissue from the wart is a simple, safe and effective therapeutic modality with rapid resolution of warts in the treatment of multiple, recurrent, recalcitrant warts.

**Key Words:** Auto wart implantation; Immune stimulation; Paring; Multiple, Recurrent, Recalcitrant warts.

---

### Introduction

Warts are benign proliferation of the skin and mucosa caused by various strains of double stranded-DNA containing human papilloma virus (HPV). They clinically manifest as common warts (*verruca vulgaris*), filiform warts (digitate wart), flat warts (*verruca plana*), plantar warts, genital warts (*condyloma accuminata*), oral and laryngeal papillomas and epidermodysplasia *verruciformis*.<sup>1</sup>

Multiple recurrent warts are associated with significant morbidity by causing physical and psychological discomfort.<sup>2</sup> Common modalities of treatment (electro cautery, radiofrequency, laser and cryotherapy) ablate the wart tissue but do not stimulate the immune system against the pathogen.<sup>3</sup> These procedures are painful, cause scarring, secondary infection, have high recurrence rates and are impractical for treatment of multiple lesions. Hence for effective treatment of warts, stimulation of the immune system by exposing the virus to immune mediators forms an ideal modality of treatment, causing spontaneous regression of wart with long lasting immunity. Auto wart implantation is one such novel, single visit procedure which treat the warts by stimulation of immune response against the virus.<sup>4</sup>

In our study, the donor tissue was harvested by paring the wart instead of removing part of wart tissue under local anesthesia. This modification was adopted to reduce the discomfort thereby minimizing the discomfort and risk of infection.<sup>5</sup> The present study was taken up to evaluate the safety and efficacy of modified technique of auto wart implantation in the treatment of multiple recurrent recalcitrant warts.

### Materials and Methods

This study was carried out between September 2013 to September 2014 in the dermatology out-patient department of a tertiary care rural hospital as a prospective open labelled study. Ethical clearance was obtained before starting the study. Forty patients with multiple (more than five warts), recurrent (warts which have recurred after any modality of treatment) and palmoplantar warts were enrolled in the study. Our exclusion criteria were patients less than 10 years, pregnancy and lactation, immunocompromised individuals (HIV) and patients on immunosuppressive drugs. Written informed consent was obtained from all the patients.

A detailed history was taken as per the pre-tested semi structured questionnaire. An elaborate general and

systemic examination was done and recorded in the standard proforma.

### Procedure of modified technique of auto wart implantation

Under aseptic precautions, donor tissue for auto graft was harvested by paring a well-developed verrucous lesion or palmoplantar wart. The lesion to be pared was cleansed with spirit-povidone iodine-spirit followed by paring using a sterile surgical blade no.11 (Fig. 1). The pared tissue was transferred onto the sterile surgical gauze. The wart tissue was then auto grafted on the flexural aspect of left forearm around 2 inches below the antecubital crease. The site for engraftment was cleansed with spirit-povidone iodine-spirit and infiltrated with about 0.5ml of lignocaine with adrenaline (1:2,00,000). A subcutis deep stab incision of about 3-5mm was made using the same 11size surgical blade used for paring the wart. The wart tissue was then introduced deep into the subcutis using Adson's forceps or an insulin syringe used for infiltration followed by dressing of the wound (Fig. 2 & 3). Patient was then put on systemic antibiotics for 5 days, dressing were removed after 5 days.

Patients were assessed every 4 weeks for 3 months. At each follow-up visit, lesion count and percentage

reduction in number of warts were undertaken. Resolution of all the warts within three months was considered as complete clearance. Patients were followed up for one more month after clearance for any recurrence.

### Results

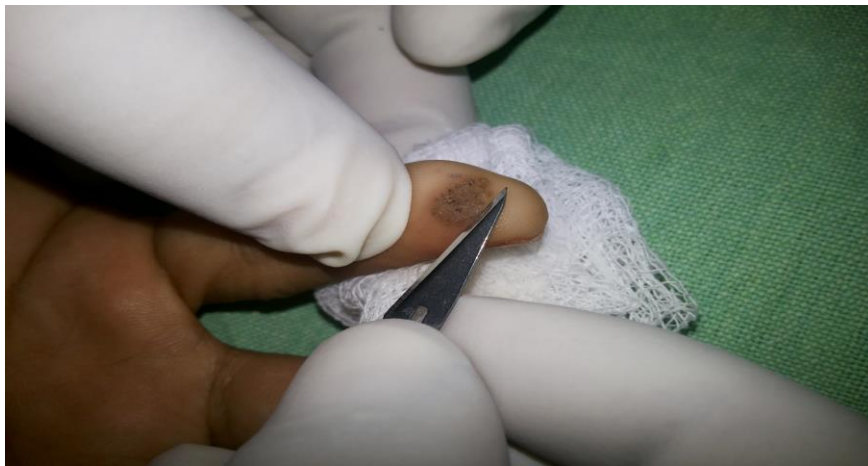All 40 patients were available for follow-up. In the present study males outnumbered females (M:F = 29:11) with commonest age of presentation being 24-28 years.

Out of 40 patients, 23 had verruca vulgaris and the remaining 17 had palmo-plantar warts. Majority of the patients (75%, 30 patients) had warts persisting for more than 6 months. At week 4 of post treatment evaluation, 60% (24 patients) had 50-75% clearance of warts and 10% (4 patients) had more than 75% clearance of warts. At week 12, total of 28 patients (75%) showed complete clearance of warts (Fig. 4 & 5), 9 patients (22.5%) had partial clearance and one patient showed no improvement.

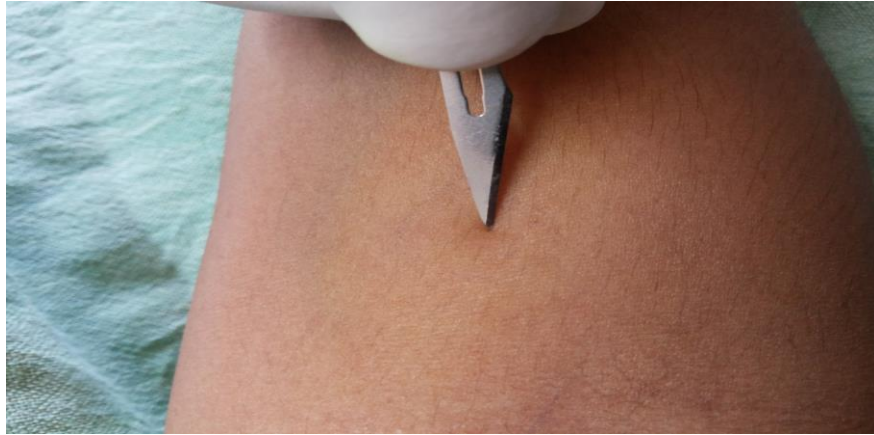
At the auto implantation site, one patient had developed erythematous nodule with purulent discharge, which subsequently resolved with systemic and topical antibiotics.

**Table 1: Comparison of the present study with previous studies**

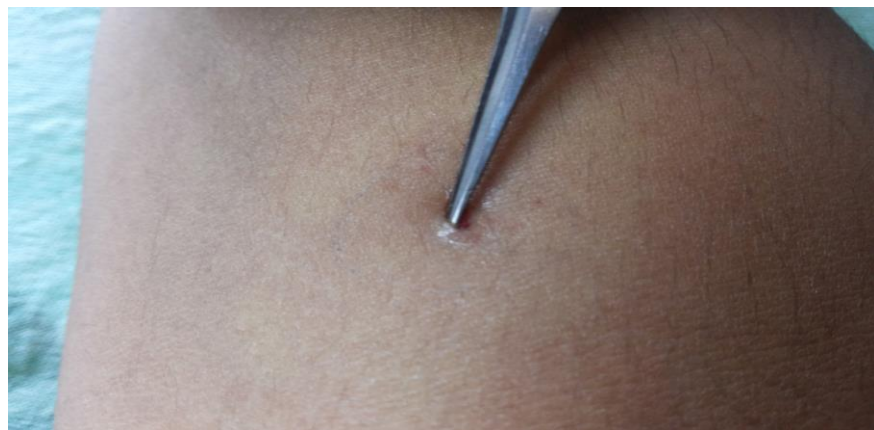Author	Shiva Kumar et al. <sup>4</sup>	Nischal et al. <sup>5</sup>	Lal et al. <sup>7</sup>	Present study
Technique adopted	Auto implantation using a sub cutis deep wart tissue	Auto implantation of the pared wart tissue (modified technique)	Autoinoculation of the full thickness wart tissue	Auto implantation of the pared wart tissue (modified technique)
Complete clearance (%)	73.3	74.1	62.5	70
Partial clearance (%)	NA	3.7	NA	30
Non responders (%)	26.7	18.5	NA	0



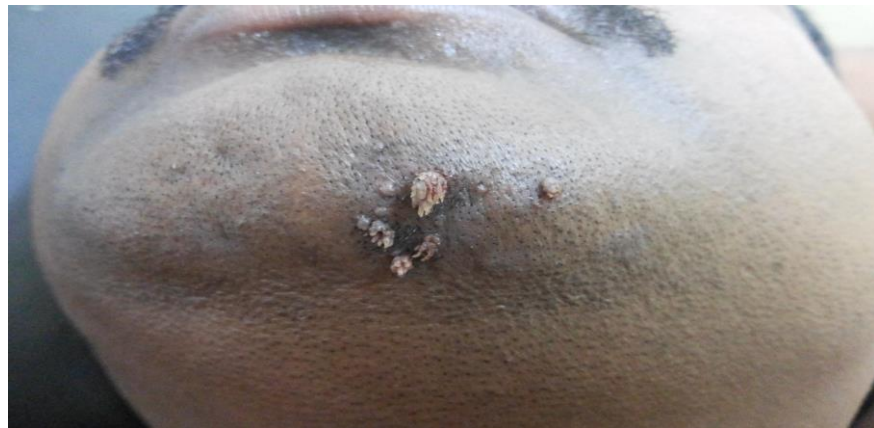**Fig. 1: Paring of wart tissue using 11 no. surgical blade**



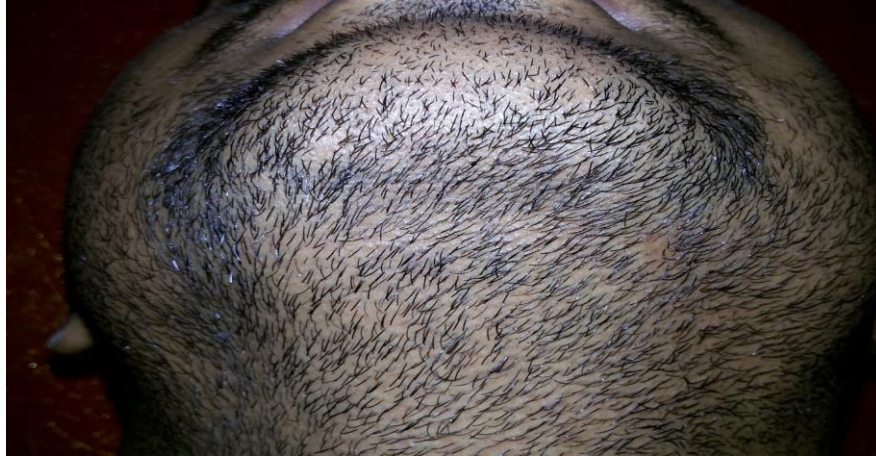**Fig. 2:** Stab incision over the flexor aspect of left arm using 11 no. surgical blade



**Fig. 3:** Implanting the pared wart tissue deep into the sub cutis



**Fig. 4:** Recurrent warts over the chin



**Fig. 5: Complete resolution of warts at the end of 3 months**

### Discussion

Warts are benign proliferation of the skin and mucosa caused by various strains of double stranded-DNA containing human papilloma virus (HPV). The common modalities of treatment namely electrocautery, cryotherapy, radiofrequency and laser are based on ablation of the viral growth but do not stimulate the immune system against the pathogen.

Immunotherapy by exposing the virus to immune mediators forms an ideal modality of treatment for multiple, recurrent, recalcitrant warts. Auto wart implantation works under this principle.<sup>4</sup> Intralesional antigen therapy was found to be associated with increase in production of Th1 cytokines wherein TNF- $\alpha$  and IL-1 down regulates the transcription of HPV genes; INF- $\gamma$  and IL-2 stimulates the cytotoxic T cells and NK cells.<sup>6</sup> In a study done by Shiva Kumar et al.<sup>4</sup> and Lal et al.<sup>7</sup> on the auto implantation technique substantial amount of wart tissue was harvested and implanted, thereby creating two wounds. In our study we performed the procedure with some modification i.e., the donor tissue was harvested by just paring the wart since HPV is an epidermal infection. By this method, wound at donor site was avoided and also eliminating the unwanted dermal tissue.

In our study, males outnumbered the females with male to female ratio being 29:11 and common age of presentation being 24-28 years which is in concordance with studies done by Shiva Kumar et al.<sup>4</sup> and Nischal et al.<sup>5</sup>

A complete clearance of warts was observed in 75% of patients (Table 1), which is similar to a study done by Nischal et al.<sup>5</sup> Nine patients (22.5%) had partial clearance and one patient (2.5%) showed no improvement at all. Partial clearance of warts was not observed by Usman et al.<sup>8</sup> and Shiva Kumar et al.<sup>4</sup> One patient had developed erythematous nodule with purulent discharge at the site of implantation which subsequently resolved with systemic and topical antibiotics. Lal et al.<sup>7</sup> in his randomized double blind placebo controlled study on autoinoculation therapy of

warts observed adverse effects in 11 patients which includes infection of the donor site, keloid formation and hypopigmentation. Shiva Kumar et al.<sup>4</sup> observed inflammatory nodule and post inflammatory hypopigmentation at the site of implantation.

### Conclusion

The modified technique of auto implantation using the pared stratum corneum tissue of the wart instead of the sub cutis deep wart tissue for auto grafting is a safe, efficacious, less traumatic and rapid procedure for the treatment of multiple, recurrent and palmoplantar warts.

Limitations of our study include small sample size, lack of HPV serotyping to measure type specific differences in therapeutic outcomes and lack of tests to check the levels of relevant Th1 cytokines to ascertain their role in resolution of warts.

### References

1. Laxmisha C, Thappa DM, Jaisankar TJ. Viral warts-A clinico-epidemiological study. *Indian J Dermatol* 2003;48:142-5.
2. Ciconte A, Campbell J, Tabrizi S, Garland S, Marks R. Warts are not merely blemishes on the skin: A study on the morbidity associated with having viral cutaneous warts. *Australas J Dermatol* 2003;44:169-73.
3. Sterling JC, Hans field-Jones S, Hudson PM. Guidelines for the management of cutaneous warts. *Br J Dermatol* 200;144:4-11.
4. Shiva Kumar V, Okade R, Raj Kumar V. Auto implantation therapy for multiple warts. *Indian J Dermatol Venereol Leprol* 2009;75:593-5.
5. Nischal KC, Sowmya CS, Swaroop MR, Agrawal DP, Basavaraj HB, Sathyanarayana BD. A novel modification of the auto implantation therapy for the treatment of multiple, recurrent and palmoplantar warts. *J. Cutan. Aesthet. Surg.* 2012;5:26-9.
6. Nofal A, Salah E, Nofal E, Yosef A. Intralesional antigen immunotherapy for the treatment of warts: Current concepts and future prospects. *Am J Clin Dermatol* 2013;14:253-60.
7. Lal NR, Sil A, Gayen T, Bandyopadhyay D, Das NK. Safety and effectiveness of autoinoculation therapy in cutaneous warts: a double--blind, randomized, placebo--

- controlled study. *Indian J Dermatol Venereol Leprol* 2014;80:515-20.
8. Usman N, Udayashankar K, Subramanian S, Thyagarajan SP. Auto implantation technique in the treatment of anogenital warts: A clinic-immunological study. *Int J STD AIDS* 1996;7:55-7.