

The prevalence, profile and outcomes of traumatic optic nerve injury in the neurosurgical patients admitted to a tertiary care centre in south India in one year

Deepti R¹, Liji Menon M^{2,*}, Blessy Thankom Mathew³, Thomas K Joy,⁴ Anna Mathew⁵

^{1,5}Professor, ^{2,3}Assistant Professor, ⁴Interne, ¹⁻⁴Dept. of Ophthalmology, ⁵Dept. of Pharmacology, MOSC Medical College, Kolenchery, Kerala, India

***Corresponding Author:**

Email: mosc.research@gmail.com

Abstract

Objectives: To find the prevalence of traumatic optic nerve injury in neurosurgical patients admitted to this rural tertiary care hospital and to assess the clinical profile and visual outcomes in these patients.

Materials and Methods: This case series of the prevalence, profile and outcomes of patients with Traumatic optic nerve injury (TONI) admitted to the neurosurgical department of this rural teaching hospital during the year 2014 received the approval of the Institutional Review Board and the Institutional Ethics Committee. Data was accessed from the medical records of these patients for one year.

Results: Of the 3466 neurosurgical admissions, 15 were found to have traumatic optic nerve injury making the prevalence of TONI in this institution 0.43%. Of the 15 patients with TONI, 14 (93%) were males and the mean age was 33 years and more than half were over the age of 30 years. Road Traffic Accidents remained the main cause for TONI (93%). Ten of these patients (66.7%) presented with fracture skull or orbit and 5 (33.3%) had no fractures. Most of the bony injuries were lateral orbital wall fractures accounting for 7 (70%). None of the patients had evidence of optic nerve compression. Fourteen of the 15 patients with TONI (93%), received intravenous and oral corticosteroids and one patient was treated conservatively. Twelve patients showed improved visual acuity on discharge while three did not improve.

Conclusion: Traumatic optic nerve injury is a vision-endangering condition which is a comorbidity of blunt head trauma. Most of the patients with optic nerve injury presented with periorbital edema, subconjunctival haemorrhage and orbital wall fracture, lateral orbital wall fracture being the commonest. Patients treated with intravenous corticosteroids followed by oral route of the same were found to have good visual outcomes. There is a great need to develop clinical databases for better understanding of the natural history and management of this condition.

Keywords: Head injury, Orbital fracture, Road traffic accidents, Traumatic optic nerve injury, Visual acuity.

Introduction

Traumatic optic nerve injury (TONI) resulting from an impact injury to the optic nerve presents with loss of visual function. This visual loss can manifest as abnormal visual acuity, visual field loss or colour vision dysfunction. Trauma induced injury to the optic nerve can occur anywhere along the intraorbital or intracranial course of the nerve and mostly occurs in young adult males, though 20% occur in childhood.¹ It can be classified depending on the site of injury (optic nerve head, intraorbital, intracanalicular, or intracranial) or according to the mode of injury (direct or indirect).² Direct trauma will result in optic nerve transection secondary to a penetrating injury or to compression from orbital or optic canal fracture. The mechanism for indirect traumatic optic nerve injury is transmission of shearing forces to the optic nerve, concentrated at the optic canal without disruption of structures around the optic nerve.³

Lee et al found the leading causes of TONI in the UK were falls (25.6%), road traffic accidents (21.5%), and assaults (20.7%). Motor vehicle and bicycle accidents are the main cause of TONI.⁴ Patients with poor visual acuities at presentation have poorer visual prognosis. Intravenous methylprednisolone is the line of management since it was proposed by the Optic neuritis treatment trial (ONTT). This trial concluded

that intravenous steroids was the effective treatment for traumatic optic nerve injury, provided the visual acuity prior to treatment is not less than counting fingers.⁵

In the ophthalmology department of our tertiary care centre, we encounter traumatic optic nerve injury from patients directly presenting to this hospital and in patients referred from other institutions. Our aim in doing this study was to evaluate the clinical profile of TONI and to assess the visual outcome in patients mostly managed by using corticosteroids.

Objectives

1. To find the prevalence of traumatic optic nerve injury in neurosurgical patients admitted to this rural tertiary care hospital.
2. To assess the clinical profile and visual outcome of traumatic optic nerve injury in neurosurgical patients admitted to this tertiary care centre.

Materials and Methods

After obtaining approval from the Institutional Review Board and the Institutional Ethics Committee, the records of 3466 patients admitted to the neurosurgical department of this rural teaching hospital during the year 2014 (1st January 2014 to 31st December 2014) were accessed. As the data was obtained from the records without any direct contact with patients waiver

of informed consent was granted by the Ethics committee. All cases of Traumatic optic nerve injury (TONI) in patients admitted to the neurosurgical department during the year 2014 were serially recruited to the study, excluding only patients with previous history of optic atrophy or ocular injuries.

Demographic data was collected from the patient records. A detailed history regarding the cause of visual loss like time and nature of the trauma, level of consciousness after trauma, site of injury, onset and duration of symptoms and time of presentation were noted. History of prior diminished vision was also obtained. History of systemic illness, surgical interventions such as sinus/cranial surgeries were also noted as it would influence the diagnosis.

Visual acuity, refraction, pupillary reaction, slit lamp examination, and fundus and tonometry examination were done. X-ray skull lateral view, orbit PA view, X-ray other parts and CT scans were taken when found necessary and possible. Patient's visual acuity, pupillary reaction, colour vision, visual fields and fundus were assessed during follow up examination.

The data collected was collated and entered into an Excel spreadsheet and analysed statistically using the Excel statistical package.

Results

Of the 3466 admissions to the neurosurgical wards of this tertiary care centre, 15 were found to have traumatic optic nerve injury making the prevalence of TONI in this institution 0.43%. Of the 15 patients with

TONI, 14 (93%) were males, reflecting the greater number of male drivers on our roads. The mean age was found to be 33 years, while 7 (46.7%) were below the age of 30 years. Of these 15 patient-eyes, Road Traffic Accidents remained the main cause for TONI, accounting for about 93% of all cases followed by alleged history of fall in 6% of cases, one of which was a sports related injury. The baseline characteristics of the 15 patients included in the study with TONI are given in table 1.

Of the 15 patients with TONI, 10 (66.7%) of patients presented with fracture skull or orbit and 5 (33.3%) had no fractures. Of the bony injuries, most were lateral orbital wall fractures accounting for 7 (70%) of the fractures, while one (10%) each had medial orbital wall, orbital roof and floor fractures. None of the patients had evidence of optic nerve compression on computer tomography (CT) or magnetic resonance imaging (MRI). Of the 15 patients with TONI, 14 (93%) received intravenous and oral corticosteroids and one patient was treated conservatively. None of the patients were treated with oral corticosteroids alone. Regarding outcome, though more than two thirds of the patients had less than 6/6 visual acuity (Snellen) at the time of presentation, 12 (80%) patients showed improved visual acuity on discharge while three did not improve.

The baseline characteristics of the study patients in relation to their visual outcome is given in table 1 and the details of the injury in relation to visual outcome in table 2.

Table 1: Baseline data of patients with traumatic optic nerve injury in relation to outcome

Characteristic	Total (n=15)	Visual outcome improved (n=12)	Visual outcome No change (n=3)
Age			
< 30 years	7 (46.7%)	5 (41.7%)	2 (66.7%)
>30years	8 (53.3%)	7 (58.3%)	1 (33.3%)
Gender			
Male	14 (93.3%)	11 (91.6%)	3 (100%)
Female	1 (6.7%)	1 (8.4%)	0 (0)
Etiology			
Road traffic Accident	14 (93.3%)	7 (58.3%)	3 (100%)
Falls	1 (6.7%)	5 (41.7%)	0 (0)
Treatment			
Corticosteroids	14 (93.3%)	11 (78.5%)	3 (21.5%)
Conservative	1 (6.7%)	1 (100%)	0 (0)

Table 2: Profile of injury in patients with traumatic optic neuropathy in relation to outcome

Feature	Total (n=15)	Visual outcome improved (n=12)	Visual outcome No change (n=3)
Associated bony injury			
Fracture	10 (66.7%)	8 (66.7%)	2 (66.7%)
No fracture	5 (33.3%)	4 (33.3%)	1 (33.3%)
Associated ocular adnexal findings			
Periorbital haematoma / Subconjunctival haemorrhage	7 (53.3%)	7 (53.3%)	NIL

Site of Fracture on MRI	7(70%)	7(70%)	NIL
Lateral orbital wall	1(10%)	1(10%)	
Medial orbital wall	1(10%)	1(10%)	
Roof of orbit	1(10%)	1(10%)	
Floor of orbit	1(10%)	1(10%)	

At presentation only 5 patients had 6/60 vision, 10 had less than 6/60 and one patient had no perception of light. On discharge 12 patients had 6/60 or more acuity of vision, one had visual acuity less than 6/60, one perceived light while one had no perception of light (NoPL).

11 (78.5%) of cases treated with intravenous and oral corticosteroids have shown one line improvement of visual acuity by the Snellen's chart. Three (21.5%)

of patients remained NoPL. The one eye that was treated conservatively showed one line of improvement of visual acuity on Snellen's chart. The patients treated with intravenous corticosteroids followed by oral corticosteroids had significant visual improvement on discharge compared to their visual acuity on presentation. ($p=0.0005$). None of the patients underwent surgical decompression of optic nerve.

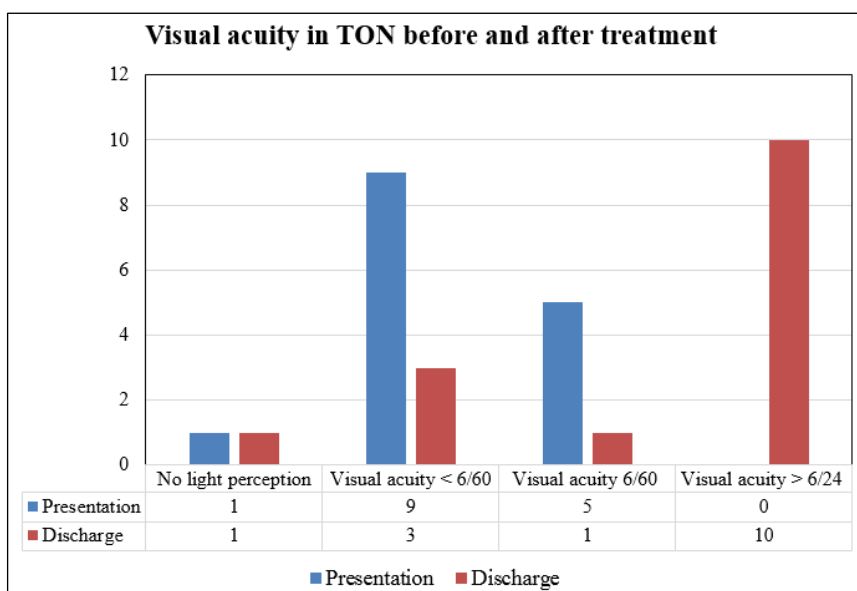


Fig. 1: Visual acuity of patients before and after treatment

Legend: After treatment with corticosteroids 12 out of 15 (80%) showed significant improvement of visual acuity while there was no change in 3 patients.

Discussion

The natural history of traumatic optic nerve injury is difficult to characterize because each patient is different. Visual loss is usually instantaneous with impact. Delayed visual loss is also reported. The affected individual is left with permanent visual loss in half of the cases. Visual prognosis and likelihood of spontaneous improvement are independent of the initial visual acuity. Even patients who had a return of normal central visual acuity did not regain an entirely normal vision. Persistence of visual field, colour defect and APD are typical. Optic nerve pallor or nerve fibre layer changes also develop over the months following the injury. Patients with only light perception on presentation can sometimes recover useful vision without intervention.

A study conducted by Lee Ford et al on traumatic optic neuropathy in the UK, minimum estimated incidence was 1.005/ million. The leading causes for TONI included falls (25.6%), road traffic accidents (21.5%) and assaults (20.7%). And the median age was 31 years.⁶

In another study on TONI in pediatric patients (< 18 years; mean age, 11.6 years; 43 affected eyes) yielded similar results to adult studies.⁷ Overall, 60% were males, common etiologies included motor vehicle accidents (62%) and sports injuries (22%). About 78% of cases were because of blunt trauma.⁸

In our study, 15 patients (15 eyes) were included. 14 cases involved were males accounting to about 93% of the total cases. Median age was 33 years. Road Traffic Accidents were the main cause for traumatic optic neuropathy (93%).

Patients with lateral orbital wall fractures usually present with periorbital swelling and ecchymosis along with variable degrees of mid facial deformity.⁹

In a study by Kok Foo Lee et al, periorbital haematoma was present in all cases with skull and/or

orbital fractures.¹⁰ In our study, most of the eyes had poor vision on presentation (66%) with associated periorbital edema of eyes and subconjunctival hemorrhage in 8 cases.

In a study by Lee et al, majority of the patients (79.2%) presented with more than one bony fracture of skull and/or orbit and 20.8% patients had no fractures¹⁰.

In a study by Bodanapally et al, it was found that isolated orbital wall fractures were the single most common type of fracture found in the study, followed by equal numbers of zygomatico-maxillary complex and Le Fort fractures.¹ In our study, 86.6% of patients presented with fracture skull or orbit and 13.4% had no fractures. Out of bony fracture most of them had lateral orbital wall fracture accounting for 61% of patients.

In our study, 14 of them received intravenous and oral corticosteroids accounting to 93% of the total cases and one was treated conservatively. None of the patients were treated with oral corticosteroids alone.

In a study by Sundeep et al, patients with initial visual acuity (pre-treatment with intravenous and oral corticosteroids) of counting fingers or better had more than two line improvement in Snellen's chart after one month post treatment with the same.¹² In our study, 78.5% of patients treated with intravenous and oral corticosteroids have shown one line or more improvement in visual acuity on the Snellen's Chart. Three patients remained with no perception of light. The one patient treated conservatively showed one line improvement of visual acuity on the Snellen's chart. In our patients treated with intravenous corticosteroids followed with oral corticosteroids we found there was significant visual improvement ($p=.0005$). None of the patients had evidence of optic nerve compression on computer assisted tomography or magnetic resonance imaging and needed surgical decompression of optic nerve.

Thus these studies show that, fracture skull or orbit was associated with traumatic optic nerve injury. Among them, lateral wall orbital wall fracture accounted to the most number of bony fractures.

Conclusion

In our study the prevalence of traumatic nerve injury was 0.43%. Traumatic optic nerve injury is a vision- endangering condition, which is a comorbidity of blunt head trauma. Most of the patients with TONI presented with periorbital edema, sub-conjunctival haemorrhage and orbital wall fracture. Lateral orbital wall fracture was the commonest type of fracture in this cohort of patients with TONI. Patients treated with intravenous corticosteroids followed by oral route of the same were found to have improvement of their visual acuity on discharge. Thus the author strongly supports the development of clinical databases for the better understanding of the natural history of the condition and further, modalities of management of traumatic optic nerve injury.

Acknowledgement: We would like to acknowledge our institution, MOSC Medical College, Kolenchery for the encouragement and support we received to do this study. We are also indebted to the departments of Ophthalmology, Research and Medical records for providing the necessary resources to accomplish this research. We would like to thank especially the Head of the Department of Ophthalmology, Dr. T.A. Alexander, Professor of Ophthalmology and Dr Soman Mani, Associate Professor of Ophthalmology for their valuable advice and encouragement.

References

1. Patrick Yu-Wai-Man. *Taiwan J Ophthalmol.* 2015 Jan-Mar;5(1):3–8. doi:10.1016/j.tjo.2015.01.003.
2. Sarkies N. Traumatic optic neuropathy. *Eye.* 2004;18:1122–1125. [PubMed: 15534597]
3. Singh A, Parihar JKS, Maggon R, S.K. Mishra MS, Kumar S. Traumatic Optic Neuropathy Management Protocol from Textbook of Management Protocols: *Neuro-Ophthalmol.* Available at <http://www.dos-times.org/pulsar9088/20150507173856145.pdf>
4. Lee V, Ford RL, Xing W, Bunce C, Foot B. Surveillance of traumatic optic neuropathy in the UK. *Eye.* 2010;24:240–250.
5. Pula JH, MacDonald CJ. Current options for the treatment of optic neuritis. *Clinical Ophthalmology (Auckland, NZ).* 2012;6:1211–1223. doi:10.2147/OPHTH.S28112.
6. Goldenberg-Cohen N, Miller N R, Repka M X. Traumatic optic neuropathy in children and adolescents. *JAPOS.* 2004;8(1):20–27.
7. Kumaran AM, SundarG, Chye LT. Traumatic Optic Neuropathy: A Review. *Craniomaxillofac Trauma Reconstr.* 2015 Mar;8(1):31–41. doi:10.1055/s-0034-1393734.
8. Alsuhaibani AH, Orbital Fracture: Significance of lateral wall. *Saudi J ophthalmol.* 2010;24(2):49–55. doi:10.1016/j.sjopt.2009.12.003.
9. Lee KF, Nor NIM, Yaakub A, Hitam WHW. *Int J Ophthalmol.* Traumatic optic neuropathy: a review of 24 patients 2010;3(2):175–178. Doi: 10.3980/j.issn.2222-3959.2010.02.20.
10. Bodanapally UK, Van der Byl G, Shanmuganathan K, Katzman L, Geraymovych E, Saksobhavit N et al. Traumatic Optic Neuropathy Prediction after Blunt Facial Trauma: Derivation of a Risk Score Based on Facial CT Findings at Admission. 2014;272:3. <<https://doi.org/10.1148/radiol.14131873>>.
11. Sundeep, Niveditha H, Nikhil N, Vinutha BV. Visual Outcome of Traumatic Optic Neuropathy in Patients Treated with Intravenous Methypredisolone. *Int J Sci Stud.* 2014;2(3):67-70.

How to cite this article: Deepti R, Liji MM, Mathew BT, Joy TK, Mathew A. The prevalence, profile and outcomes of traumatic optic nerve injury in the neurosurgical patients admitted to a tertiary care centre in south India in one year. *Ind J Clin Exp Ophthalmol.* 2018;4(3):417-420.