

## Duplication of optic canal (a figure of eight anomaly) – case report with review of literature

Lakshmi Prabha .S<sup>1</sup>, Khizer Hussain Afroze<sup>2,\*</sup>, Komala .B<sup>3</sup>, Archana .BJ<sup>4</sup>

<sup>1</sup>Professor and HOD, <sup>2</sup>Research Scholar, <sup>4</sup>Associate Professor, Dept. of Anatomy, Sri Siddhartha Medical College, Tumakuru, Karnataka, <sup>3</sup>Professor and HOD, Dept. of Anatomy, BGS Global Institute of Medical Sciences, Bengaluru, Karnataka, India

**\*Corresponding Author:**

Email: drafroze.homoeo@gmail.com

### Abstract

A duplication of optic canal was discovered on the right side of the skull during routine osteology class of Head and Neck in the Department of Anatomy at Sri Siddhartha Medical College (SSMC). The main canal was larger and situated as usual in the normal position, gives passage to the optic nerve whereas the accessory canal was smaller than the main canal and was positioned inferolateral to it, transmits the ophthalmic artery. The bony septum separating the two canals was approximately 3mm in length and 1mm in thickness. The duplicated optic canal is a rare anomaly of the optic canal which every radiologist, ophthalmologist, and neurosurgeon needs to be aware of. Imaging studies may aid in elucidating its true etiology corresponding with the age and time of onset of the duplicate optic canal.

**Keywords:** Accessory optic canal, Duplicate optic canal, Figure of eight, Optic canal, Optic canal anomaly.

### Introduction

Minor variations in the foramina and ridges of the cranium have aroused the curiosity of anatomists for many decades. The two major openings which communicate orbit with the middle cranial fossa are superior orbital fissure and optic canal. The optic canal is situated in the sphenoid bone and bounded by the two roots of the lesser wing of the sphenoid and body of sphenoid bone. The inferior root of the lesser wing of the sphenoid is referred to as 'metoptic root', sphenoidal strut, or optic strut.<sup>1</sup>

Any alteration or anomalies in optic strut may lead to variation in the shape of the optic canal, the so-called "Keyhole" and Figure of 8" anomalies. The optic canal may give an appearance of 'Key hole' when the posterosuperior segment of optic strut fails to develop. The optic canal can be double which acquire a shape similar to number 8 (so-called figure of eight anomaly), in which canal is separated by a bony plate or septum. In case of Duplicate Optic Canal (DOC), the upper larger canal gives passage to the optic nerve and the smaller lower one transmits the ophthalmic artery.<sup>2</sup>

This study is an attempt to document a case of DOC in the dry human adult skull and to add some contribution to literature because of the rarity of this condition and also to explain its etiology in detail.

### Case Report

During routine osteology practical class of Head and Neck in the Department of Anatomy at Sri Siddhartha Medical College (SSMC), a duplicate optic canal (DOC) on the right side of the skull was discovered. The main canal was larger and situated as usual in a normal position whereas the accessory canal was smaller than the main canal and was positioned inferolateral to it. The two canals were situated nearly parallel to each other with intervening wall or septa. The bony septum separating the two canals was approximately 3mm in length along the axis of the canals and 1mm in thickness. The measurements of optic canal and their accessory openings were taken from cranial and orbital ends by using vernier calipers.

**Table 1: Shows the measurement of duplicate optic canal both from cranial and orbital ends**

S. No	Measurements	View	Main Canal (mm)	Accessory canal (mm)
1.	Length × Breadth	Orbital	3 × 2	2 × 2
		Cranial	3 × 2	2 × 2.5
2.	Length of the canal along the medial wall		3	1.5
3.	Distance between the medial ends of the right and left openings	Orbital	7	4
		Cranial	6	4

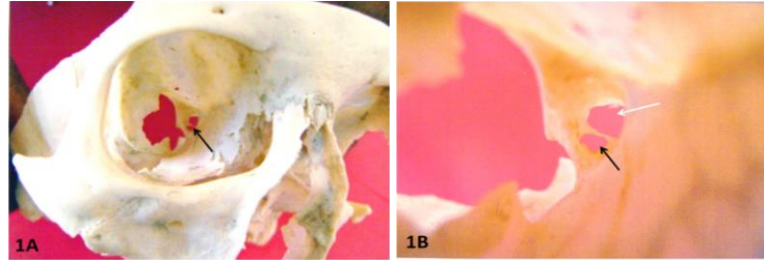
**Site and Direction of the Canals:** The duplicate optic canal (DOC) was situated on the right side in the lesser wing of the sphenoid bone. The main canal was continuous with sulcus chiasmaticus as the canal

directed posteromedially and upwards. The location of the accessory canal was in continuity with the anterior end of the groove for the internal carotid artery. The shape of each canal at the cranial side was horizontally

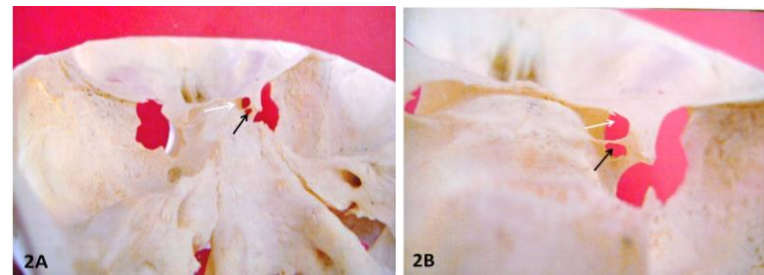
oval. On the Orbital side, the opening was in an oblique direction and was passing downwards and medially.

**Septa:** The septa were moderately thick and measured 3mm in length. The bony septum separating the two canals was attached medially to the lateral end of the

tuberculum sellae. There is no excessive bone formation like the presence of sutural bones or prominent middle clinoid process. The patency of both the canals were confirmed by observation.



**Fig. 1: A) orbital view of both main and accessory canal B) closer view White arrow – Main optic canal and black arrow – accessory optic canal**



**Fig. 2: A) Cranial view of both main and accessory canal B) closer view. White arrow – Main optic canal and black arrow – accessory optic canal**

## Discussion

Various authors conducted an extensive review of the duplicate optical canal (DOC) offers a sum number of previously reported cases. In the literature, we

evidence that duplicate optic canal had been documented as an osteological study in dried human skulls and few conducted as a radiological study<sup>3-22</sup> (Table 2).

**Table 2: Incidence of the duplicate optic canal in different population**

Authors	Total of Skulls	No. of skulls showing the duplicate optic canal	Total of duplicate optic canal (including Bilateral)	Percentage (%)
Zoja et al <sup>(3)</sup> (1885)		5	6	
Le Double et al <sup>(4)</sup> (1903)	Case report	1	2	
White et al <sup>(5)</sup> (1924)	161	3	3	1.86%
Whitnell et al <sup>(6)</sup> (1932)	Case report	1	1	
Keyes et al <sup>(7)</sup> (1935)	2187	5	5	0.22%
Warwick et al <sup>(8)</sup> (1951)	Case report	1	2	
Kier et al <sup>(1)</sup> (1996)	450	5	5	1.2%
Lang et al <sup>(9)</sup> (1977)		3	4	
Choudhry et al <sup>(2)</sup> (1988)	Case report	3	5	
Berlis et al <sup>(10)</sup> (1992)	80	2	2	2.5%
Orhan M A et al <sup>(11)</sup> (1996)	369	2	3	0.54%
Singh et al <sup>(12)</sup> (2005)	435	13	20	2.98
Math AC et al <sup>(13)</sup> (2010)	316	2	4	0.63%
Patil GV et al <sup>(14)</sup> (2011)	400	11	14	2.75%
Mahajan A et al <sup>(15)</sup> (2012)	96	1	1	1.04%
Ghai R et al <sup>(16)</sup> (2012)	194	5	7	2.57%
Shinde et al <sup>(17)</sup> (2013)	100	1	1	1%
Swetha et al <sup>(18)</sup> (2014)	67	3	4	4.47%
Vanitha et al <sup>(19)</sup> (2014)	Case report	1	1	
Nayak G et al <sup>(20)</sup> (2016)	100	3	5	3%
Purohit BJ et al <sup>(21)</sup> (2016)	150	1	1	0.67%
Himabindu A et al <sup>(22)</sup> (2016)	50	5	5	10%

Many theories have been proposed by various authors but still, the etiology and pathogenesis of this condition remain unclear. In the literature, we found the five possible or potential theories which may lead to this condition as follows

**Ossification of Duramater:** The most widely accepted theory involves an "Ossification of duramater". Le Double<sup>4</sup> (1903) reported the single bilateral case of DOC in which he considered the presence of septum between the optic nerve and ophthalmic artery may be due to the ossification of the duramater covering the optic nerve. Warwick<sup>8</sup> (1951) reported bilateral DOC in 21 month old child at postmortem examination. This suggests that ossification of duramater may not be the sole cause for the formation of DOC because ossification process is regarded as characteristic of the later decades of life. Unfortunately, this theory has received unreliable acceptance from several authors.

**Presence of an Aberrant Ophthalmic Vein:** Augier<sup>8</sup> (1931) has recommended that duplicity of optic canal represents the persistence of foramen which he had frequently encountered in the fetal skulls. He speculated this foramen is due to the presence of an aberrant ophthalmic vein. Above statement is contradicting to Le Double<sup>4</sup> theory.

**Ossification of Fibrous Tissue:** Warwick<sup>8</sup> (1951) and Wolff<sup>23</sup> (1976) postulated this condition is due to the ossification of fibrous tissue which lies between the ophthalmic artery and the dura mater. Except above studies, there are no other anecdotal cases or studies to support this theory. This theory likely falls within the same mechanism of ossification of duramater and no longer deserves to be considered as a sole etiology for the formation of DOC.

**Bony Projection in the Inferolateral Wall of the Optic Canal:** Keyes J EL<sup>7</sup> (1935) attributed this pathogenesis is due to the bony projection in the inferolateral wall of the optic canal, when it is large, divides the optic canal into two parts, upper and larger for optic nerve and lower for the ophthalmic artery. Kier EL<sup>1</sup> (1966) supporting Keyes<sup>7</sup> concluded that "it's not the optic canal but the cranial opening which duplicates".

**Developmental Anomaly:** Kier EL<sup>1</sup> (1966) stated that the cranial opening of the optic canal is oval and this shape results from the formation of the posterosuperior segment of the optic strut and the posterior growth of the lesser wing of the sphenoid bone. Two separate cranial opening was formed when the ophthalmic artery is below the posterosuperior segment of the optic strut which is generally as a rule, present above this segment. He acknowledged that the DOC is developmental in origin and these results are not due to duramater ossification but from the anomalous growth of the optic strut.

However, there is a lack of clinical finding in the patients, as a result, DOC has been documented as an occasional finding either osteological or radiological studies. Although several hypotheses have been put forward to explain the etiology of DOC, none have been well substantiated by reliable logical evidence. Based on an available review of the literature, it seems there may be more than one potential etiology corresponding with the age of onset of DOC.

A detailed and precise knowledge regarding the presence of DOC is important in executing any surgical approach to the optic canal during tumor removal and optic nerve decompression or while approaching the cavernous sinus.<sup>24</sup> With the advancement of modern diagnostic technologies and techniques, the data of the bony septum between the canal which is responsible for the figure of eight anomaly, corresponding with the origin and time of onset of DOC should give us more clarity about its etiology.

## Conclusion

The duplicated optic canal is a rare anomaly of the optic canal which every radiologist, ophthalmologist, and neurosurgeon needs to be aware of. The etiology of the duplicate optic canal remains unclear. A detailed analysis and knowledge of the optic canal and associated surrounding area can improve our understanding of the vascular complication and complex clinical neuralgias affecting this region. Imaging studies may aid in elucidating its true etiology corresponding with the age and time of onset of the duplicate optic canal.

## References

1. Kier EL. Embryology of the Normal Optic Canal and Its Anomalies an Anatomic and Roentgenographic Study. *Investigative radiology*. 1966;1(5):346-62.
2. Chaudhary R, Anand M, Chaudhary S. Morphology and imaging studies of duplicate optic canals in dry adult human skulls. *Surg Radiol Anat*. 1999;21(3):201-205.
3. Zoja G. Spora il foro ottico doppio. *Bollentino Scientifico Pavia*. 1895;65-69.
4. Le-Double AF, Traite' des Variations des Os du Crane de l'Homme Paris: Vigot Freres. 1903; pp. 372.
5. White L E. An anatomic and X-ray study of the optic canal. *Boston Med Surg*. 1923;189:741-748.
6. Whitnall SE. The Anatomy of human orbit 2nd ed. London: Oxford University Press, London; 1932; pp 53-313.
7. Keyes JE. Observations on four thousand optic foramina in human skulls of known origin. *Archives of Ophthalmology*. 1935;13(4):538-568.
8. Warwick R. A juvenile skull exhibiting duplication of optic canals and division of superior orbital fissure. *J Anat*. 1951;85(3):289-291.
9. Lang J. Structure and postnatal organization of heretofore uninvestigated and infrequent ossifications of the sella turcica region. *Cells Tissues Organs*. 1977;99(2):121-39.

10. Berlis A, Putz R, Schumacher M. Direct and CT measurements of canals and foramina of the skull base. *Br J Radiol.* 1992;65(776):653-661.
11. Mağden AO, Kaynak S. Bilateral duplication of the optic canals. *Annals of Anatomy-Anatomischer Anzeiger.* 1996;178(1):61-64.
12. Singh M. Duplication of optic canal in adult Japanese human skulls. *J Anat Soc India.* 2005;54(2):1-9.
13. Math SC, Kulkarni SR, Jatti VK. A study of duplication of the optic canals in human adult skulls of North Karnataka. *Indian Journal of Forensic Medicine & Toxicology.* 2010;4(2):104-105.
14. Patil GV, Kolagi S, Padmavathi G, Rairam GB. The duplication of the optic canals in human skulls. *J Clin Diagn Res.* 2011;5(3):536-537.
15. Mahajan A, Seema. Duplication of optic canal in an adult human skull- Embryological and clinical aspects. *J Pharm Biomed Sci.* 2012;14(14):1-2.
16. Ghai R, Sinha P, Rajguru J, Jain S, Khare S, Singla M. Duplication of optic canal in human skulls. *J Anat Soc India.* 2012;61(1):33-36.
17. Shinde VS, Patil R, Channabasaganagouda MM. Study of duplication of optic canal in hundred dry human skull bones. *International Journal of Biochemical Research.* 2013; 4(11):633-635.
18. Sweta VR, Saravana SK. Accessory optic canal in South Indian dry skull. *J Pharm Sci and Res.* 2014;6(5):224-225.
19. Vanitha FT, Kadlimatti HS. Unilateral duplication of optic canal: a case report. *J Dent Med Sci.* 2014;13:82-83.
20. Nayak G, Mohanty BB, Das SR. Study Of Duplicated Optic Canals In Eastern Indian Human Skulls. *Asian J Pharm Clin Res.* 2016;9(3):85-86.
21. Purohit BJ, Singh PR. An Osteologic Study of Cranial Opening of Optic Canal in Gujarat Region. *Journal of clinical and diagnostic research: JCDR.* 2016;10(11):AC08-11.
22. Himabindu A, Sunitha V. Variations of optic canal in human skulls. 2016;5(8):227-228.
23. Wolff E. *Anatomy of the Eye and orbit.* 7th ed, vol 15, London: H.K. Lewis, 1976.
24. Slavin K V, Dujovny M, Soeira G, Ausman J. Optic canal-Microanatomic study. *Skull Base surgery.* 1994;4(3):136-144.

**How to cite this article:** Lakshmiprabha S, Afroze KH, Komala B, Archana BJ. Duplication of optic canal (a figure of eight anomaly) – case report with review of literature. *Ind J Clin Exp Ophthalmol.* 2018;4(3):426-429.