

Intravitreal versus posterior subtenon injection of triamcinolone acetonide in diabetic macular edema

Navneet Kaur^{1,*}, Gursatinder Singh², Ardaman Singh³, Rajinder Singh⁴, Shray Dogra⁵

^{1,5}Junior Resident, ²Associate Professor, ³Professor, ⁴Assistant Professor
Dept. of Ophthalmology, Govt. Medical College, Patiala

***Corresponding Author**

E-mail: navneetkaur0509@gmail.com

Abstract


Objectives: In this study, intravitreal injection of triamcinolone acetonide (TA) was compared with posterior subtenon injection of TA for treatment of diabetic macular edema (DME).

Materials and Methods: In this prospective, open, randomized, parallel group, comparative study, 60 patients of diabetic macular oedema visiting the Department of Ophthalmology, Govt. Medical College, Patiala were included. The patients fulfilling the inclusion criteria and having none of the exclusion criteria were enrolled in the study after obtaining written informed consent. Patients were then randomized into two groups (group I, II) and received intravitreal and posterior subtenon injection of triamcinolone acetonide, respectively. The comparison was based on change in best corrected visual acuity and macular thickness using optical coherence tomography (OCT). The results were subjected to statistical analysis and observations thus made in both groups were compared.

Results: With intravitreal TA, the mean pre-treatment CMT, mean post-treatment CMT and mean reduction in CMT were $395.53 \pm 15.31 \mu\text{m}$, $221.2 \pm 10.71 \mu\text{m}$ and $174.33 \mu\text{m}$ (44.08 %) while the mean pre-treatment VA, mean post-treatment VA and mean improvement in VA were 0.79 ± 0.16 , 0.51 ± 0.15 and 0.28 (36.11 %) logMAR units. With posterior subtenon TA, the mean pre-treatment CMT, mean post-treatment CMT and mean reduction in CMT were $394.43 \pm 15.03 \mu\text{m}$, $247.3 \pm 11.82 \mu\text{m}$ and $147.13 \mu\text{m}$ (37.3 %) while the mean pre-treatment VA, mean post-treatment VA and mean improvement in VA were 0.81 ± 0.15 , 0.58 ± 0.14 and 0.23 (28.24 %) logMAR units. The mean pre-treatment IOP, mean post-treatment IOP and mean rise in IOP with intravitreal TA were $16.67 \pm 1.92 \text{ mm Hg}$, $18.87 \pm 1.81 \text{ mm Hg}$ and 2.2 mm Hg (13.19 %), whereas with posterior subtenon TA were $16.87 \pm 1.85 \text{ mm Hg}$, $17.4 \pm 1.59 \text{ mm Hg}$ and 0.53 (3.14 %).

Conclusions: When used in diabetic macular edema, intravitreal triamcinolone acetonide is more effective than posterior subtenon triamcinolone acetonide in reducing the central macular thickness, although it produces a greater rise in IOP than PST.

Key-words: Central macular thickness, Diabetic macular edema, IOP, triamcinolone.

Access this article online	
Quick Response Code:	Website: www.innovativepublication.com
	DOI: 10.5958/2395-1451.2016.00015.9

Introduction

Diabetic retinopathy (DR) is a vascular disease involving the microvasculature of the retina, and is the foremost cause of visual impairment in the western population.^[1,2] According to estimates, diabetes mellitus affects 4 per cent of the world's population, with almost half of those having some degree of DR at any given time^[3]. In India, manifold increase in type 2 diabetes mellitus has been reported by the World Health Organization (WHO)^[4] and diabetic retinopathy is fast becoming an important cause of visual morbidity.

Development of diabetic macular edema (DME) is the main etiology behind visual decline in diabetic retinopathy cases, which can be seen both during non-proliferative or proliferative stages^[5,6]. Clinically significant macular edema (CSME) as defined by The Early Treatment Diabetic Retinopathy Study (ETDRS),

is any thickening of retina at or within 500 microns from the centre of macula; hard exudates at or within 500 microns from the centre of macula, if associated with thickening of the adjacent retina; or a zone/zones of retinal thickening one disc area or larger, any part of which is within one disc diameter of the centre of macula^[7]. DME is generally divided into focal edema, consisting of localized areas of thickening originating from leaking micro aneurysms, generally associated with hard exudates; and diffuse macular edema, which demonstrates generalized leakage from dilated capillaries and retinal pigment epithelial barrier disruption^[8,9]. Optical coherence tomography (OCT) generates cross-sectional images of the retina and provides us with quantitative readings of retinal thickness in the posterior pole area with sufficient accuracy^[10-12] thus aiding in establishing the diagnosis of DME, as well as assessing the response to any treatment^[13-15].

As per the findings of the ETDRS, focal laser photocoagulation has been used as an effective treatment for the subgroup with hard exudates in the centre of macula^[16]. However, the scarcity of clinically significant improvement in visual acuity after laser therapy as well as the relapse or persistence of DME

after proper laser treatment^[16,17], has led investigators to seek alternative treatments for the management of DME. Steroids reduce neutrophil transmigration, limit access to sites of inflammation, and decrease cytokine production and hence are the traditional treatment of inflammatory eye disease. Several studies clearly report the effect of steroids in reducing VEGF expression, leukostasis and inflammatory cytokine production^[18, 19]. Steroids injected intravitreally stabilize vision and reduce severity of DME, but they are also associated with frequent side effects; the most common being an increase in intraocular pressure (IOP) and cataract progression.

Among those under investigation for DME^[20-23], the administration of triamcinolone acetonide (TA), either by an intravitreal (IVTA) injection or by a posterior subtenon (PSTA) injection has demonstrated encouraging results for the management of refractory or primary DME. Triamcinolone acetonide binds to specific cytosolic glucocorticoid receptors, interacts with glucocorticoid receptor response element on DNA leading to alteration in gene expression. It is a more potent derivative of triamcinolone, and is about eight times as potent as prednisone^[24]. It is the corticosteroid presently in use by ophthalmologists in the clinical setting because it is readily available as a pharmacologic agent (Kenacort, Kenalog) with the typical intravitreal dose used to treat eyes with diabetic macular edema being 4 mg in a volume of 0.1 ml^[25].

Materials and Methods

The study was conducted in the Department of Ophthalmology, Government Medical College, Patiala after obtaining due permission from the ethical committee of the institute. A total of 60 diagnosed cases of type 2 diabetes mellitus of either sex, having symptomatic, clinically significant diabetic macular oedema with a central macular thickness >300 µm on an optical coherent tomography (OCT), aged above 30 years were enrolled after obtaining a written informed consent. Exclusion criteria were type 1 diabetes mellitus cases, pregnancy induced, stress induced and juvenile diabetes, macular oedema other than diabetes, any co-existing retinal disease, history of glaucoma or ocular hypertension, systemic corticoid therapy, known hypersensitivity to any component of procedural medication and history of previous triamcinolone acetonide injection in the eye.

Patients selected were randomised into two groups of 30 each with group I receiving a single pars plana intravitreal injection of 4mg triamcinolone whereas group II received a single 40mg posterior subtenon injection of triamcinolone. Bilateral diabetic macular oedema was treated in both eyes but the right eye was taken for study. The drug was made available as Kenacort 40 mg (Abbott Healthcare Pvt Ltd).

Best corrected visual acuity (BCVA) was tested with a Snellen chart and converted into Logarithm of

Minimum Angle of Resolution (logMAR) values, while optical coherence tomography (Stratus OCT, Carl Zeiss Meditec) was used to measure the central macular thickness (CMT). Goldmann applanation tonometry, biomicroscopy of anterior segment, direct ophthalmoscopy and slit lamp indirect biomicroscopy with +78D or +90D lens were done at each visit. Patients with elevation in IOP over 21 mm Hg in injected eyes at follow up visits were put on antiglaucoma medications. The period of follow up was 12 weeks with a total of four visits on day 0, week 4, 8 and 12. The temporal changes in visual acuity, central macular thickness and IOP were compared using the Wilcoxon signed rank test while the differences between groups for each variable were compared using the Mann-Whitney U test.

Results

Overall in the study, 58.33% of the patients were male and 41.67% were female with mean patient age being 62.77 years. Mean age in group I and group II was 66.3 years and 59.2 years, respectively. Thus no statistically significant differences regarding the parameters of patient profile were present.

The central macular thickness (mean±SD) with intravitreal TA was 395.53±15.31µm at baseline and at the end of 4, 8 and 12 weeks was 264.83 ± 11.19, 217.07±10.78 and 221.2±10.71µm, respectively. There was a reduction of 174.33 µm (44.08 %) from the baseline. With posterior sub-tenon TA, the central macular thickness (mean±SD) was 394.43±15.03µm at baseline and at the end of 4, 8 and 12 weeks was 274.47±11.86, 236.57±11.54 and 247.3±11.82µm, respectively. There was a reduction of 147.13µm (37.3%) when compared with the baseline. Thus, both the routes produced statistically significant reduction in the severity of macular edema at each follow up visit after injection, but intravitreal TA produced greater reduction in central macular thickness at all visits when compared to posterior subtenon TA. The difference between the two groups was statistically significant at 4th (0.003), 8th (0.000) and 12th (0.000) weeks.

Best corrected logMAR visual acuity (mean±SD) with intravitreal TA at the end of 4, 8 and 12 weeks was 0.51±0.13, 0.47±0.15 and 0.51±0.15, respectively with an improvement of 0.28 (36.11%) at the end of the study when compared with the baseline. The best corrected logMAR visual acuity (mean±SD) with posterior sub-tenon TA at the end of 4, 8 and 12 weeks was 0.59±0.14, 0.56±0.14 and 0.58±0.14, respectively, with an improvement of 0.23 (28.24 %) when compared to the baseline at the end of the study. Injection by both the routes produced a statistically significant improvement in visual acuity also at each follow up visit, although intravitreal TA produced better improvement in final logMAR visual acuity at each follow up visit as compared with posterior subtenon TA, the difference in the logMAR visual acuity also

being statistically significant at 4th (0.039), 8th (0.028) and 12th (0.034) weeks.

IOP with intravitreal TA at the end of 12 weeks was 18.87±1.81mm Hg with a significant increase of 2.2 (13.19 %) when compared with the baseline IOP of 16.67±1.92mm Hg. IOP with posterior subtenon TA at the end of 12 weeks was 17.4±1.59mm Hg showing an increase of 0.53 (3.14%) when compared with the

baseline IOP of 16.87±1.85. Increase in the intraocular pressure of eyes with intravitreal TA at 4, 8 and 12 weeks (3.06, 3.43 and 2.2mm Hg, respectively) was more as compared with posterior subtenon TA (1.43, 0.6 and 0.53mm Hg, respectively). The difference in increase in IOP between the two groups was statistically significant at the 8th (<0.0001) and 12th (0.003) weeks.

Table 1: Mean central macular thickness and best corrected visual acuity in group i and group ii at different points of time

1. Visit	Central Macular Thickness (CMT)			Best Corrected Visual Acuity (BCVA)		
	Group I (microns)	Group II (microns)	p value	Group I (logMAR)	Group II (logMAR)	p value
Visit 1	395.53 ± 15.31	394.43 ± 15.03	0.873	0.79 ± 0.16	0.81 ± 0.15	0.645
Visit 2	264.83 ± 11.19	274.47 ± 11.86	0.003	0.51 ± 0.13	0.59 ± 0.14	0.039
Visit 3	217.07 ± 10.78	236.57 ± 11.54	<0.0001	0.47 ± 0.15	0.56 ± 0.14	0.028
Visit 4	221.2 ± 10.71	247.3 ± 11.82	<0.0001	0.51 ± 0.15	0.58 ± 0.14	0.034

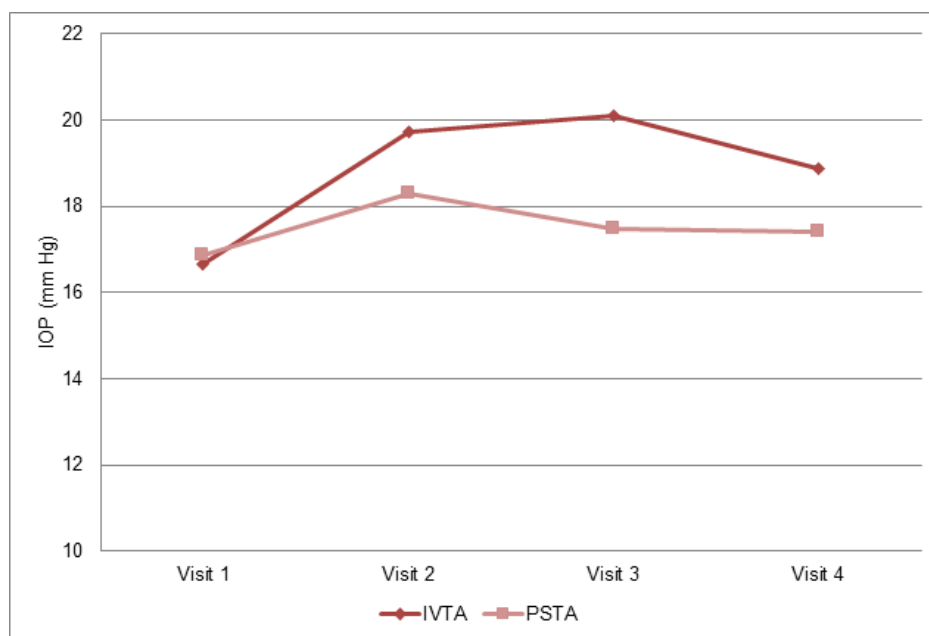


Fig. 1: Mean iop in group i and group ii at different points of time

Discussion

Diabetic macular edema is a common cause of visual loss in patients with diabetic retinopathy. It is estimated that DR develops in more than 75% of diabetic patients within 15 to 20 years of diagnosis of diabetes.^[26,27] According to the latest World Health Organization (WHO) report, India has 31.7 million diabetes subjects, and the number is expected to increase to a staggering 79.4million by 2030.^[4] In recent years, the intravitreal administration of triamcinolone acetonide has provided promising results for the treatment of diffuse macular edema. Posterior subtenon injection of a steroid is an alternative method with proven effectiveness in various ocular diseases like cystoid macular edema and intermediate uveitis. The aim of our study was to compare the effectiveness and safety between intravitreal and posterior subtenon

injection of triamcinolone acetonide for the treatment of diabetic macular edema.

Previous studies by Kriechbaum K et al^[28], Ramezani A et al^[29], Audren F et al^[30], Desatnik H et al^[31] and Ciardella AP et al^[32] have underlined the efficacy of intravitreal triamcinolone in reducing the central macular thickness in cases of diabetic macular edema. Toda J et al^[33], Gurram MM^[34], Unoki N et al^[35] and Chew E et al^[36], in their studies have established the efficacy of posterior subtenon triamcinolone in reducing central macular thickness in various ocular disorders. Norlaili M et al^[37], Brasil OF et al^[38], Ladjimi A et al^[39], Jonas JB et al^[40], Desatnik H et al^[31] and Ciardella AP et al^[32] have demonstrated the role of intravitreal triamcinolone in improving the visual acuity in diabetic macular edema cases. Trials conducted by Kawashima H et al^[41], Gurram MM^[34],

Unoki N et al^[35] and Chew E et al^[36] proved the efficacy of posterior sub tenon triamcinolone in improving visual acuity in vascular disorders.

Ansari EA et al^[42], Jonas JB et al^[43] documented significant rise in IOP values post intravitreal injection of triamcinolone with many cases developing values > 21mmHg. Hirano Y et al^[44] observed a significant difference in the frequency of IOP > 30mmHg between the PSTA group and the IVTA group with more patients in the IVTA group needing antiglaucoma medication.

Luo D et al^[45] observed that after administration of IVTA and SBTA, visual acuity was reduced from 0.805±0.069Log/MAR to 0.577±0.091Log/MAR, (p<.001) and from 0.814±0.082Log/MAR to 0.49±0.080Log/MAR, (p<.001), respectively. After IVTA and SBTA injection, central macular thickness was significantly reduced to 246.8±25µm, (p<.001) from 390.5±17µm and to 241.5±27µm, (p<.001) from 394.4±21µm, respectively.

Qamar RM et al^[46] observed greater improvement in Snellen's acuity with PSTA as compared with IVTA with the difference between the groups at six months post-treatment being statistically significant (p<.05). The difference in CMT between the eyes treated with an IVT injection (385.2±11.3µm) and a PST injection (235.4±8.7µm) was also significantly different six months after treatment (p<.001).

In their comparison, Cellini M et al^[47] found that the difference in VA and CMT between an IVT injection (0.809 +/- 0.083 and 385.2 +/- 11.3 micron) and SBT injection (0.460 +/- 0.072 and 235.4 +/- 8.7 microm) becomes significant six months after the treatment (p < 0.001). IOP of the eyes treated with IVTA significantly increased after one, three and six month, but not with PSTA.

In the study by Bonini-Filho MA et al^[48] CMT was significantly reduced in the IVTA group when compared with the PSTA group at all follow up visits after treatment. Mean VA at all follow up examinations were significantly higher in the IVTA group when compared with the PSTA group. A significant change from baseline in mean IOP was seen at weeks 4 (+/- 3.21) and 8 (+/-3.35) in PST group, and at week 8 (+/- 2.78) in the IVT group.

Largely reflecting the findings in earlier studies, the present study observed that both intravitreal (IVTA) and posterior subtenon (PSTA) injection of triamcinolone acetonide produced statistically significant reduction in best corrected visual acuity (BCVA) and central macular thickness (CMT) in injected eyes at 4 weeks, 8 weeks and 12 weeks of follow up as compared to the baseline. IVTA produced greater reduction in central macular thickness as compared with PSTA (174.33µm and 147.13µm respectively), which was statistically significant at all follow up visits. Improvement in final BCVA was also greater with IVTA than with PSTA (0.28 and 0.23

respectively); with the difference being statistically significant at all follow up visits. Both IVTA and PSTA produced an increase in intraocular pressure of injected eyes with IOP elevation being more with IVTA than with PSTA (2.2mm Hg and 0.53mm Hg respectively), the difference becoming statistically significant at 8 weeks and 12 weeks.

Repeated injections of triamcinolone, required to elicit maximum response in many cases of DME, were not used; and owing to the short duration of study, data about cataractogenesis in injected eyes was not gathered. Further trials for a longer duration and in a larger population are required for data on the long term effects on macular thickness and visual acuity gains along with side effects of the drug, especially in a larger cohort.

To conclude, intravitreal triamcinolone acetonide is more efficacious than posterior subtenon triamcinolone acetonide in reducing central macular thickness and improving visual acuity when used in diabetic macular edema, although it produces a greater rise in intraocular pressure.

Conflict of Interest: None

Source of Support: Nil

Bibliography

1. KleinR, KleinBE, MossSE. Visual impairment in diabetes. *Ophthalmology*. 1984;91:1-9.
2. Vision Problems in the United States. Data Analysis: Definitions, Data Sources, Detailed Data Tables, Analysis, Interpretation. 1989;1-46. National Society to Prevent Blindness New York.
3. Aiello LP, Gardner TW, King GL, Blankenship G, Cavallerano JD, Ferris FL 3rd, et al. Diabetic retinopathy. *Diabetes Care* 1998;21:143-56.
4. WildS, RoglicG, GreenA, SicreeR, KingH. Global prevalence of diabetes, estimates for the year 2000 and projections for 2030. *Diabetes Care*. 2004;27:1047-1053.
5. Nicholson BP, Schachat AP. A review of clinical trials of anti-VEGF agents for diabetic retinopathy. *Graefes Arch Clin Exp Ophthalmol* 2010;248:915-930.
6. Soheilian M, Garfami KH, Ramezani A, Yaseri M, Peyman GA. Two-year results of a randomized trial of intravitreal bevacizumab alone or combined with triamcinolone versus laser in diabetic macular edema. *Retina* 2012;32:314-321.
7. Deckers V, Priem H, Verbraeken H. One year of intravitreal injections of steroids. *Bull Soc Belge Ophthalmol* 2005;297:69-77.
8. Lang GE. Diabetic macular edema. *Ophthalmologica* 2012; 227 Suppl 1:21-29.
9. Stefanini FR, Arevalo JF, Maia M. Bevacizumab for the management of diabetic macular edema. *World J Diabetes* 2013;4:19-26.
10. Sadda SR, Wu Z, Walsh AC, Richine L, Dougall J, Cortez R, et al. Errors in retinal thickness measurements obtained by optical coherence tomography. *Ophthalmology* 2006; 113:285-93.
11. Polito A, Del Borrello M, Polini G, Furlan F, Isola M, Bandello F. Diurnal variation in clinically significant

- diabetic macular edema measured by the Stratus OCT. *Retina* 2006;26:14–20.
12. Goebel W, Franke R. Retinal thickness in diabetic retinopathy: Comparison of optical coherence tomography, the retinal thickness analyzer and fundus photography. *Retina* 2006;26:49–57.
 13. Ciulla TA, Amador AG, Zinman B. Diabetic Retinopathy and Diabetic Macular Edema, Pathophysiology, screening, and novel therapies. *Diabetes Care* 2003;26(9):2653-64.
 14. Panozzo G, Gusson E, Parolini B, Mercanti A. Role of OCT in the diagnosis and follow up of diabetic macular edema. *Semin Ophthalmol* 2003;18:74–81.
 15. Luttrull JK, Spink CJ. Serial optical coherence tomography of sub threshold diode laser micro pulse photocoagulation for diabetic macular edema. *Ophthalmic Surg Lasers Imaging*. 2006;37:370–7.
 16. Early Treatment Diabetic Retinopathy Study Research Group Photocoagulation for diabetic macular edema. Early Treatment Diabetic Retinopathy Study report number 1. *Arch Ophthalmol*. 1985;103:1796–806.
 17. Aiello LM. Perspectives on diabetic retinopathy. *Am J Ophthalmol*. 2003;136:122–135.
 18. Nauck M, Roth M, Tamm M, et al: Induction of vascular endothelial growth factor by platelet-activating factor and platelet-derived growth factor is down-regulated by corticosteroids. *Am J Respir Cell Mol Biol* 1998;16:398-406.
 19. Tamura H, Miyamoto K, Kiryu J, et al: Intravitreal injection of corticosteroid attenuates leukostasis and vascular leakage in experimental diabetic retina. *Invest Ophthalmol Vis Sci* 2005;46:1440-1444.
 20. Jonas JB, Kreissig I, Sofker A, Degenring RF. Intravitreal injection of triamcinolone for diffuse DME. *Archives of Ophthalmology*. 2003;121:57–61.
 21. Karacorlu M, Ozdemir H, Karacorlu S, Alacali N, Mudun B, Burumcek E. Intravitreal triamcinolone as a primary therapy in diabetic macular oedema. *Eye*. 2005;19(4):382–386.
 22. Kuppermann BD, Blumenkranz MS, Haller JA, Williams GA. Posurdex Study Group. An Intravitreal Dexamethasone Bioerodible Drug Delivery System for the Treatment of Persistent Diabetic Macular Edema; Association for Research in Vision and Ophthalmology Annual Meeting; 2003. Kuppermann BD, Blumenkranz MS, Haller JA, Williams GA, Weinberg DV, Chou C, et al. Randomized Controlled Study of an Intravitreal Dexamethasone Drug Delivery System in Patients With Persistent Macular Edema. *Archives of Ophthalmology*. 2007;125(3):309–317.
 23. Massin P, Audren F, Haouchine B, Erginay A, Bergmann JF, Benosman R, et al. Intravitreal triamcinolone acetonide for diabetic diffuse macular edema: preliminary results of a prospective controlled trial. *Ophthalmology*. 2004;111(2): 218–224.
 24. Nasacort medication leaflet
 25. Martidis A, Duker JS, Greenberg PB, Rogers AH, Puliafito CA, Reichel E et al: Intravitreal triamcinolone for refractory diabetic macular edema. *Ophthalmology* 2002;109:920–927
 26. DwyerMS, MeltonJ, BallardDJ, et al. Incidence of diabetic retinopathy and blindness: a population based study in Rochester. Minnesota. *Diabetes Care*. 1985;8:316–322.
 27. KleinR, KleinBE, MossSE, DavisMD, DeMetsML. The Wisconsin epidemiologic study of diabetic retinopathy. III Prevalence and risk of diabetic retinopathy when age at diagnosis is 30 or more years. *Arch Ophthalmol*. 1984;102:527–532.
 28. Kriechbaum K, Prager S, Mylonas G, Scholda C, Rainer G, Funk M et al; Diabetic Retinopathy Research Group. Intravitreal bevacizumab (Avastin) versus triamcinolone (Volon A) for treatment of diabetic macular edema: one-year results. *Eye (Lond)*. 2014 Jan;28(1):9-15; quiz 16.
 29. Ramezani A, Tabatabaie H, Ahmadi H. Diabetic macular edema before and after intravitreal triamcinolone injection. *Korean J Ophthalmol*. 2007 Jun;21(2):95-9.
 30. Audren F, Erginay A, Haouchine B, Benosman R, Conrath J, Bergmann JF et al. Intravitreal triamcinolone acetonide for diffuse diabetic macular oedema: 6-month results of a prospective controlled trial. *Acta Ophthalmol Scand*. 2006 Oct;84(5):624-30.
 31. Desatnik H, Habet-Wilner Z, Alhalel A, Moroz I, Glovinsky J, Moisseiev J. The transient efficacy of a single intravitreal triamcinolone acetonide injection for diabetic macular edema. *Isr Med Assoc J*. 2006 Jun;8(6):383-7. Erratum in: *Isr Med Assoc J*. 2006 Aug;8(8):588.
 32. Ciardella AP, Klancnik J, Schiff W, Barile G, Langton K, Chang S. Intravitreal triamcinolone for the treatment of refractory diabetic macular oedema with hard exudates: an optical coherence tomography study. *Br J Ophthalmol*. 2004 Sep;88(9):1131-6.
 33. Toda J, Fukushima H, Kato S. Injection of triamcinolone acetonide into the posterior sub-tenon capsule for treatment of diabetic macular edema. *Retina*. 2007 Jul-Aug;27(6):7649.
 34. Gurrum MM. Effect of posterior sub-tenon triamcinolone in macular edema due to non-ischemic vein occlusions. *J Clin Diagn Res* 2013 Dec;7(12):2821-4.
 35. Unoki N, Nishijima K, Kita M, Suzuma K, Watanabe D, Oh H et al. Randomised controlled trial of posterior sub-Tenon triamcinolone as adjunct to panretinal photocoagulation for treatment of diabetic retinopathy. *Br J Ophthalmol*. 2009 Jun;93(6):765-70.
 36. Chew E, Strauber S, Beck R, Aiello LP, Antoszyk A, Bressler N et al, Diabetic Retinopathy Clinical Research Network. Randomized trial of peribulbar triamcinolone acetonide with and without focal photocoagulation for mild diabetic macular edema: a pilot study. *Ophthalmology*. 2007 Jun;114(6):1190-6.
 37. Norlaili M, Bakiah S, Zunaina E. Intravitreal triamcinolone versus laser photocoagulation as a primary treatment for diabetic macular oedema—a comparative pilot study. *BMC Ophthalmol*. 2011 Nov 23;11:36.
 38. Brasil OF, Smith SD, Galor A, Lowder CY, Sears JE, Kaiser PK. Predictive factors for short-term visual outcome after intravitreal triamcinolone acetonide injection for diabetic macular oedema: an optical coherence tomography study. *Br J Ophthalmol*. 2007 Jun;91(6):761-5.
 39. Ladjimi A, Zeghidi H, Ben Yahia S, Zaouali S, Jenzri S, Messaoud R et al. Intravitreal injection of triamcinolone acetonide for the treatment of macular edema. *J Fr Ophthalmol*. 2005 Sep;28(7):749-57.
 40. Jonas JB, Akkoyun I, Kreissig I, Degenring RF. Diffuse diabetic macular oedema treated by intravitreal triamcinolone acetonide: a comparative, non-randomised study. *Br J Ophthalmol*. 2005 Mar;89(3):321-6.
 41. Kawashima H, Mizukawa K, Kiryu J. Factors associated with visual recovery after sub-Tenon injection of triamcinolone acetonide in diabetic macular edema. *Clin Ophthalmol*. 2012;6:1307-14.

42. Ansari EA, Ali N. Intraocular pressure following intravitreal injection of triamcinolone acetonide. *Open Ophthalmol J.* 2008 Jun 30;2:119-22.
43. Jonas JB, Kreissig I, Degenring R. Intraocular pressure after intravitreal injection of triamcinolone acetonide. *Br J Ophthalmol.* 2003 Jan;87(1):24-7.
44. Hirano Y, Ito T, Nozaki M, Yasukawa T, Sakurai E, Yoshida M et al. Intraocular pressure elevation following triamcinolone acetonide administration as related to administration routes. *Jpn J Ophthalmol.* 2009 Sep;53(5):519-22.
45. Luo D, Zhu B, Zheng Z, Zhou H, Sun X, Xu X. Subtenon Vs Intravitreal Triamcinolone injection in Diabetic Macular Edema, A prospective study in Chinese population. *Pak J Med Sci.* 2014 Jul;30(4):749-54.
46. Qamar RM, Saleem MI, Saleem MF. Comparison of the efficacy between an intravitreal and a posterior subtenon injection of triamcinolone acetonide for the treatment of diffuse diabetic macular edema. *Eurasian J Med.* 2013 Oct;45(3):185-90.
47. Cellini M, Pazzaglia A, Zamparini E, Leonetti P, Campos EC. Intravitreal vs. subtenon triamcinolone acetonide for the treatment of diabetic cystoid macular edema. *BMC Ophthalmol.* 2008 Mar 17;8:5.
48. Bonini-Filho MA, Jorge R, Barbosa JC, Calucci D, Cardillo JA, Costa RA. Intravitreal injection versus sub-Tenon's infusion of triamcinolone acetonide for refractory diabetic macular edema: a randomized clinical trial. *Invest Ophthalmol Vis Sci.* 2005 Oct;46(10):3845-9.