

Chondroblastic variant of gnathic osteosarcoma– A rare case report

Ashwini Baliga^{1,*}, Raghavendra Kini², Prasanna K. Rao³, Roopashri Rajesh Kashyap⁴, Meghana HC⁵

^{1,5}Assistant Professor, ²Professor & HOD, ³Professor, ⁴Reader, Dept. of Oral Medicine & Radiology, AJ Institute of Dental Sciences, Mangalore, Karnataka, India

***Corresponding Author:**

Email: kalaliga@gmail.com

Abstract

Osteosarcomas are the most common primary malignant neoplasm of the bone. Osteosarcomas predominantly occur in the long bones and are rare in the maxillofacial region. Gnathic osteosarcoma differs from osteosarcoma of the long bones in its biological behavior even though they have the similar histologic appearance. The maxillary osteosarcomas show predilection for posterior portion of the alveolar process and the antrum, whereas in the mandible, body is most commonly involved site followed by angle, symphysis and ascending ramus. We report a rare case of osteosarcoma of the maxilla in a 62 year old male patient which was diagnosed histopathologically as chondroblastic variant of osteosarcoma. The treatment comprised of surgery followed by radiation therapy.

Keywords: Chondroblastic, Jaw, Osteosarcoma, Maxilla.

Introduction

Osteosarcoma is the most common primary malignant bone tumor characterised by direct formation of disorganized immature woven bone from mesenchymal tumor cells.¹ Incidence of intraoral sarcoma is very rare and may constitute approximately 1% of all head and neck cancers and only 0.14% of intraoral malignancies.² Maxillofacial osteosarcomas are rare and represent 4 to 8 percent of all osteosarcomas.³ They have a bimodal distribution with the first peak in adolescents and second peak in adults above 60 years of age.⁴ Incidence of osteosarcomas is more in males with a ratio of 1.4:1, with the mandible being the most common site.^{3,5,6} Among gnathic osteosarcomas body of the mandible is the most commonly affected site.^{7,8} The World Health Organization lists several variants that differ in location, clinical behaviour and level of cellular atypia. The conventional or classical osteosarcoma is the most common variant, which develops in the medullary region of the bone and can be subdivided into osteoblastic and chondroblastic histological types, depending on the type of extracellular matrix produced by tumor cells.⁹ In this case report we present a rare case of osteosarcoma of the maxilla in an elderly male patient and emphasize on the need for a detailed clinical, radiological and histological examination for an early diagnosis and better prognosis.

Case Report

A 62 year old male patient reported to our department with a chief complaint of swelling in the upper left back tooth region of the jaw of two months duration. Swelling was initially peanut sized and gradually increased to the present size. It was associated with pain which was mild in intensity, localized, dull aching type and

continuous in nature. Past dental, medical and family history were non contributory. Extraoral examination revealed facial asymmetry in the left middle third of the face due to a diffuse solitary swelling measuring about 5 x 4 cms in size. Skin over the swelling was normal in colour and stretched. There was obliteration of the nasolabial fold. Watery discharge was seen from the left eye. On palpation the swelling was tender, firm in consistency and not fixed to the overlying skin. Intraoral examination revealed a well defined swelling in the left maxillary buccal vestibule which was dome shaped extending from left maxillary first premolar to left maxillary third molar region (Fig. 1). It was around 4x2 cms in size causing obliteration of the buccal vestibule. The overlying mucosa was erythematous and ulcerated. On palpation it was firm and tender. There was grade three mobility in relation to left maxillary second premolar and left maxillary first molar. Gingival recession was seen in the palatal aspect of left maxillary second premolar and left maxillary first molar.

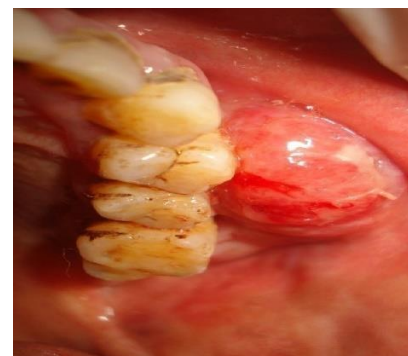

Fig. 1: Intraoral swelling in the left maxillary posterior region

Based on these findings a provisional diagnosis of malignancy of the left maxillary alveolus was given.

Malignancy of the maxillary sinus was considered in the differential diagnosis. Investigations were carried out. Haematological values including serum alkaline phosphatase were within normal limits. Intraoral periapical radiograph showed radiolucency extending from distal aspect of left maxillary second premolar up to left maxillary first molar with loss of lamina dura and external root resorption in relation to left maxillary first molar. Alteration in the density of bone and trabecular pattern was observed. Maxillary lateral occlusal view revealed soft tissue radiolucency extending from left maxillary first premolar to left maxillary first molar with specks of calcification and also a well defined radiolucency with mixed radio opacity involving apex of left maxillary second premolar and left maxillary first molar (Fig. 2). Paranasal sinus view revealed an ill defined radiopaque mass with surrounding hazy radiolucency in the left maxillary sinus. Further a computed tomography scan was done which revealed a mixed radiolucent radiopaque, lobulated expansile lesion involving the left maxillary sinus, floor of the orbit, lateral wall of the nose with presence of multiple foci of calcification (Fig. 3). Chest radiograph, Ultrasonography of abdomen and bone scan was done to rule out metastasis. An incisional biopsy was done which revealed connective tissue tumor spread in sheets, vesicles and vaguely storiform pattern. Individual tumor cells showed abundant eosinophilic cytoplasm with indistinct borders and plump nuclei. There was presence of areas of chondroid differentiation with ossification and calcification (Fig. 4).

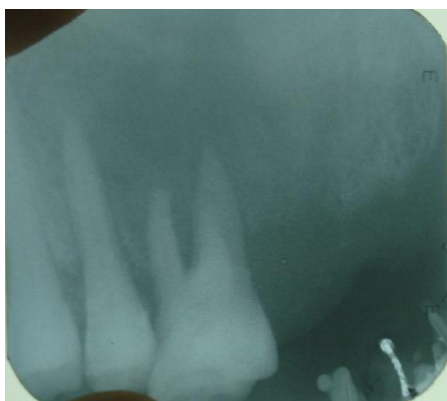


Fig. 2: Maxillary lateral occlusal radiograph showing soft tissue radiolucency with specks of calcification and radiolucency with mixed radiopacity involving apex of left maxillary second premolar and left maxillary first molar

Thus a final diagnosis of Chondroblastic variant of osteosarcoma of the left maxillary alveolus was given. The patient was surgically treated with total maxillectomy and reconstruction with mesh under general anesthesia followed by post operative radiotherapy. The patient was periodically recalled

every six months for follow up and no recurrence has been observed till date.

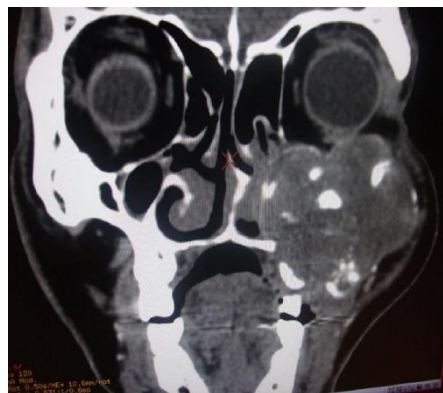

Fig. 3: Computed tomography scan (coronal view) revealed lobulated expansile lesion involving the left maxillary sinus, floor of the orbit, lateral wall of the nose with presence of multiple foci of calcification

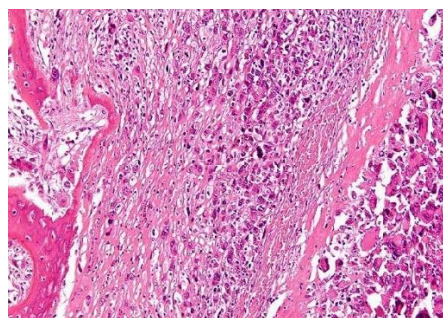


Fig. 4: Photomicrograph (H&E 40x) showing connective tissue tumor spread in sheets, vesicles and vaguely storiform pattern and presence of areas of chondroid differentiation with ossification and calcification

Discussion

Primary osteosarcomas comprises of a heterogeneous group of malignant bone tumors which are characterized by diverse clinical, histological and biological behavior.⁹

Osteosarcomas are spindle cell neoplasms and accounts for almost 40- 60% of all bone sarcomas.¹⁰ As the incidence of osteosarcoma in maxillofacial region is extremely uncommon, this case is worth being reported.

There are numerous variants of osteosarcoma of jaw bones but these are generally classified into two types primary and secondary. Pathogenesis of osteosarcomas is unknown with majority of the primary osteosarcomas arising de novo. It can also develop from pre existing conditions such as Paget's disease, fibrous dysplasia, bone infarcts, chronic osteomyelitis, trauma, and exposure to radiation. Genetic mutations in tumor suppressor gene P₅₃, Li-Fraumeni syndrome, hereditary retinoblastoma, Rothmund-Thomson syndrome have been claimed to be amongst other etiologic factors. Our case appears to have developed de novo. Recent studies

in molecular research have shown that osteosarcoma is caused by genetic and epigenetic changes that disrupt osteoblast differentiation from mesenchymal stem cells.^{7,10-12}

Osteosarcoma of the jaws present with distinct clinical features such as occurrence in older age, longer median survival, rare metastases, local recurrences which are difficult to control leading to death of the patient. Affected patient typically present with swelling along with occasional ulceration, pain and general discomfort.^{3,8} Loosening of the teeth may be the first or even dominant manifestation of the disease. Paresthesias and numbness in the lips, failure of extraction sites to heal, enlargement or deformity of the bone are the other symptoms. Some patients relate the occurrence of the tumor to previous dental treatment, most commonly dental extraction. This could be due to rapid growth of tumor immediately after tooth extraction, a feature often shown by bone tumors.¹²

On plain radiographs osteosarcoma shows varied radiographic appearance ranging from osteolytic to mixed osteolytic-osteoblastic (moth-eaten or cumulus cloud) to predominantly osteoblastic.^{13,14} When the tumor invades the periosteum, periosteal reaction of the bone presents as typical “sunray” or “sunburst appearance”.³ This is due to osteophytic bone appearing as thin irregular spicules developing outward and perpendicular to the surface of the lesion.¹² These are seen in fifty percent of gnathic osteosarcomas and are best appreciated on occlusal radiographs and computed tomography. Another classical sign of early osteosarcoma is the Garrington’s sign. It is a widening of periodontal ligament space around the affected teeth due to tumor infiltration.³ Computed tomography scan and magnetic resonance imaging are valuable adjuncts to plain film radiographs for determining the extent of the disease.¹²

Varied radiographic appearance of osteosarcoma stresses on the need for a detailed histological analysis. Histopathologically osteosarcomas show sarcomatous stroma with osteoid produced by the atypical neoplastic osteoblasts. Based on the type of extracellular matrix present osteosarcomas can be subdivided as osteoblastic, chondroblastic and fibroblastic histological types.^{7,10} Among gnathic osteosarcomas 60% are osteoblastic, 34% are fibroblastic and less than 10% chondroblastic.⁸ Our case was mainly composed of connective tissue tumor spread in sheets with areas of chondroid differentiation showing ossification and calcification suggestive of chondroblastic variant which is a rarity.

Treatment for osteosarcoma comprises a multimodal approach. Wide radical resection is the treatment of choice followed by adjuvant chemotherapy and radiotherapy.¹² Adjuvant therapies are considered in presence of metastasis to other sites or as a palliative therapy in unresectable tumors. In primary osteosarcoma an overall 5 year survival rate varies from

30% to 40%. Survival rate of upto 80% has been observed in patients who undergo early radical resection.^{8,9} Maxillary osteosarcomas are known to have an unfavourable prognosis compared to mandible.⁹ Among the various histological types chondroblastic variant is associated with a better prognosis.⁸

Conclusion

Gnathic osteosarcomas are rare and usually present to the dentist with symptoms of pain and swelling in the jaws. Hence dental professionals should have a thorough knowledge regarding the diverse clinical presentation, radiographic and histologic features. Further it aids in early diagnosis and treatment, enormously improving the prognosis of the disease. Considering the rarity of the disease, case reports provide a platform to discuss issues of clinical and diagnostic significance.

References

1. Raymond AK, Ayala AG, Knuutila S. Conventional osteosarcoma. In, Fletcher CD,
2. Unni KK, Mertens F (ed). Pathology and Genetics of Tumors of Soft Tissue and Bone, 1st edition. IARC Press, 2002:264-70.
3. Gorsky M, Epstein JB Head and neck and intra-oral soft tissue sarcomas. *Oral Oncol* 1998;34:292-6.
4. George A, Mani V, Sunil S, Sreenivasan BS, Gopakumar D. Osteosarcoma of maxilla: - a case of missed initial diagnosis. *Oral Maxillofac Pathol J* 2010;1(1)
5. Mirabello L, Troisi RJ, and Savage SA. Osteosarcoma Incidence and Survival Rates from 1973 to 2004. *Cancer* 2009;1531-43
6. Khorate MM, Goel S, Singh MP, Ahmed J. Osteosarcoma of Mandible: A Case Report and Review of Literature. *J Cancer Sci Ther* 2010;2(4):122-5.
7. Rodrigues G. Metastatic Osteosarcoma to the Maxilla. *Kuwait Med J* 2003;35(3):219-21.
8. Contar CM, Dirschnabel A, Thiele M, Maffei C, Martins WD, Ribas M. Osteogenic Sarcoma of the Maxilla: Case Report. *Applied Cancer Res* 2008;28(1):33-6.
9. George A, Mani V. Gnathic osteosarcomas: Review of literature and report of two cases in the maxilla. *J Oral Maxillofac Pathol* 2011;15(2):138-43.
10. Soares RC, Soares AF, Souza LB, dos Santos LV, Pinto LP. Osteosarcoma of mandible initially resembling lesion of dental periapex: a case report. *Rev Bras Otorrinolaringol* 2005;71(2):242-5.
11. Sheikh S, Pallagatti S, Aggarwal A, Gupta D, Puri N, Mittal A. Osteosarcoma of maxilla: A case report. *J Clin Exp Dent* 2010;2(3):117-20.
12. Cutilli T, Scarsella S, Fabio DD, Oliva A, Cargini P. High-grade chondroblastic and fibroblastic osteosarcoma of the upper jaw. *Ann Maxillofac Surg* 2011;1:176-80.
13. Chaudhary M, Chaudhary SD. Osteosarcoma of jaws. *J Oral Maxillofac Pathol* 2012;16(2):233-8.
14. Amaral MB et al. *Med Oral Patol Oral Cir Bucal* 2008 Aug 1;13(8):492-5.
15. Cavalcanti MGP, Ruprecht A, Yang J. Radiological findings in an unusual osteosarcoma in the maxilla. *Dentomaxillofac Rad* 2000;29:180-4.