



## Original Research Article

## Fetal echocardiography and its role in high risk antenatal mothers

Swastika Gojnur<sup>1</sup>, Annie Rajaratnam<sup>1,\*</sup><sup>1</sup>Dept. of Obstetrics and Gynaecology, Yenepoya Medical College, Mangalore, Karnataka, India

## ARTICLE INFO

## Article history:

Received 04-02-2020

Accepted 29-02-2020

Available online 15-06-2020

## Keywords:

Fetal echocardiography

Congenital heart disease

High risk pregnancy

## ABSTRACT

**Introduction:** Fetal echocardiography is a screening tool mostly reserved for high risk pregnant women. Early identification of cardiac anomalies improves perinatal outcomes. However this tool need not be restricted to high risk cases only but can be used for all pregnant women.

**Materials and Methods:** This 6 month observational study included singleton pregnant women aged 18-40yrs attending antenatal clinic with one to two decisive risk factors for fetal congenital heart disease (CHD). A fetal echocardiography was done between 18 to 24 week of pregnancy.

**Results:** Of the 50 cases a total of 4 cases of CHD's were diagnosed by abnormal fetal echocardiography. The remaining 46 cases showed a complete accord between fetal and postnatal echo findings except one case where a membranous VSD with Left to Right shunt, was detected by prenatal echo but was absent in the post natal finding.

**Conclusion:** Our study strongly endorse all mothers to undergo fetal echocardiogram by trained specialists who are at risk of congenital heart disease such as maternal congenital heart disease and diabetes in pregnancy.

© 2020 Published by Innovative Publication. This is an open access article under the CC BY-NC license (<https://creativecommons.org/licenses/by-nc/4.0/>)

## 1. Introduction

Structural malformation of the heart and great vessels are the most usual severe congenital abnormality, with a prevalence of 3 to 8 per 1000 live births.<sup>1,2</sup> There is no familial CHD risk factor in the most infants born. If a high prenatal detection rate of CHD is acceptable, a screening of entire populations is expected. During the screening process, the possibility of CHD in the fetus should be increased, and a more thorough diagnosis can be made later following a fetal echocardiography referral.<sup>2</sup>

The antenatal diagnosis of CHD is influenced by non-invasive imaging techniques such as Ultrasonogram (USG) and fetal echocardiography. The fetal echocardiography is the primary tool for the evaluation of cardiovascular fetal pathology from late first trimester. Echocardiography has the disadvantage of the thrifty number of diagnostic experts at semi-urban centres. To diagnose CHD in suspected and

high risk patients, echocardiography is the main clinical approach. The ultrasound examination of the cardiac human fetal system is fetal echocardiography.<sup>3</sup>

Echocardiography assesses the heart's structures and function. Fetal echocardiography can help to identify heart defects before birth so that a quicker diagnostic or surgical operation is possible after a baby has been born. Prenatal diagnosis with critical heart abnormalities have been shown to boost survival chance for babies with extreme cardiac defects, for example, complete transposition of big arteries and hypo-plastic left cardiac syndrome after birth. Evidence has shown that CHD's are four times higher than neural tube defects and six times higher than chromosomal anomalies.<sup>4</sup>

As there are a high rate of fetal cardiac anomalies which can occur with a number of maternal and fetal disorders hence evaluation with regular antepartum ultrasonography is necessary.<sup>3</sup> The factors like diabetes, autoimmune disorders like systemic lupus erythematosus or Sjogren's syndrome, diabetes, use of drugs, e.g., antiepileptics or

\* Corresponding author.

E-mail address: [annierajaratnam@yahoo.com](mailto:annierajaratnam@yahoo.com) (A. Rajaratnam).

antipsychotics like lithium, etc., CHD in the mother are the maternal risk factors.<sup>5</sup>

Intrauterine therapy can improve perinatal outcomes early detection of potential cardiac problems, such as aortic stenosis. The full cardiac examination could be considered part of the 11-13, 6-week daily foetal anatomy.<sup>3</sup> Precise prenatal diagnosis provides potential clinical benefit for children. To assess fetal diagnosis and compare the diagnosis with the final postnatal diagnosis of doubtful congenital heart disease is the aim of our study was.

## 2. Materials and Methods

This is a observational study and was conducted in a tertiary care centre. The ethical clearance from the Institutional Ethical Clearance Committee was taken. The study was conducted for a period of 6 months (March 2019-August 2019). At the department of Obstetrics & Gynaecology all Pregnant women attending the antenatal clinic (ANC) for evaluation were included in the study. The study included pregnant women attending antenatal clinic with one or two definitive risk factors for fetal CHD.

Relevant data was collected from all the records of high risk antenatal patients in the obstetric population, data was retrieved from the hospital database {Z36.83} and was analysed. There were a random sample of 50 pregnant mothers identified with one or two congenital cardiac disease risk factors for the fetus. Range From 20 to 40 years was the Age group of pregnant women with CHD risk factor. Based on their obstetric status at the time of the study, the patients had a fetal echocardiography done, whether ambulatory or inpatient.

After information on the advantages of fetal echocardiography and its noninvasive existence was clarified, confidence was developed about the diagnosis of fetal cardiac malformations in the pregnancy. Between 18 -24 week of pregnancy Fetal echocardiography was performed trans-abdominally. 4 chamber views, Right Ventricular Outflow Tract, Left Ventricular Outflow Tract, 3 vessel view, 3 vessel trachea view, aortic arch view, bicaval view and ductal arch view were the views obtained from the fetal echo.

The International Society of Ultrasound guidelines on Obstetrics and Gynecology conducts regular fetal echocardiogram. The full 4-chamber inspection of the fetal heart is performed during the operation. Detailed reports of the echocardiogram had been sent to the patients and they were advised in detail about the results of their pregnancy in the presence of heart defects.

The fetal heart condition with minimal false negativity when normal echocardiography was produced which has to be confirmed after delivery by repeating the echocardiography of the neonates the mothers were reassured. The cases with abnormal findings on fetal echocardiography Postnatal follow up was done. With

a 3-8 Mhz broadband phased array transducer Postnatal echocardiography was performed. In cases with Intra-Uterine Death Autopsy confirmation was obtained.

## 3. Results

Our study included pregnant females undergoing fetal echocardiography with one or two CHD risk factors. The sample size of the study was 50 pregnant females. The age distribution of the pregnant females were analyzed. In the age group of 31-35yrs highest number of patients were, but the number of patients were decreasing after the age of 35 yrs. This is an indicator that the elderly age group are more of a contributor to the occurrence of congenital heart disorders in the fetus as depicted in Table 1.

**Table 1:** Fetal echocardiography at the time of Maternal age

Maternal age	Number of patients
18-20 years	4
21-25 years	9
26- 30 years	10
31-35 years	16
35- 40 years	11

The optimal time period for the assessment of most the Fetal Cardiac Anatomy's detailed data, had been carried out between 18 and 22 weeks of gestational age.<sup>6</sup> Between the ages of 20-24 weeks of pregnancy in the present study most fetal echocardiographs were done following suspicious findings on ultrasound. The parity has no influence directly or indirectly over the congenital heart disease or its occurrence. In our study 18 patients were primigravida while 32 patients were multi-gravida.

**Table 2:** Relation between parity score with fetal echocardiogram

Parity score	Number of patients
Primigravida	14
Gravida 2	10
Gravida 3	16
Gravida 4	7
Gravida 5	3

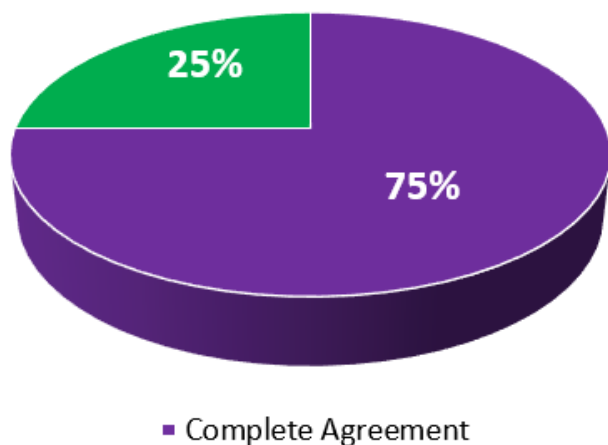
A study by Rychik J have shown that better physiological condition after birth and improved surgical result of infants having fetal echocardiography for prenatal diagnosis.<sup>7</sup> In the present study, out of fifty patients, forty six patients were found to have normal fetal echoes that had an important impact on the mother's anxiety and stress relief from fetal heart abnormalities. There were 4 patients diagnosed with varying degrees of abnormal echocardiography.

The fetal echo results and postnatal echo findings were fully agreeable in 3 patients (75.0%). In one case, a membranous Ventricular septal defect with Left to Right shunt, was detected by prenatally echo. It was absent in the post natal finding (Figure 1). The post natal echo detected

**Table 3:** Number of patients with abnormal echocardiogram findings

Echo findings	Number of patients	Percentage
Normal	46	92%
Abnormal	4	8%

muscular VSD (Table 4).

**Fig. 1:** Showing prenatal and postnatal or autopsy findings in cases with congenital heart disease**Table 4:** Findings of abnormal echocardiography

Membranous VSD with Left to Right shunt	1
Small echogenic focus in LV	2
Dilated RA	1

There was a significant difference in POG at birth and mean birth weight of the infant at birth. The mean period of gestation (POG) at birth in patients with Extra-Cardiac Anomalies (ECA) was  $35.29 \pm 2.87$  weeks while mean POG at birth in patients without ECA was  $37.14 \pm 3.14$  weeks and 't' test shows significant difference between the two. The mean birth weight of the infants in group with ECA was  $2.30 \pm 0.16$  kgs and without ECA was  $2.65 \pm 0.19$  kgs with significant difference ( $P=0.01$ ) between these groups.

#### 4. Discussion

The most common structural fetal anomalies are Congenital heart disease, they can either occur as isolated or in combination with other anatomical defects. There is a strong association between congenital heart disease and genetic or chromosomal abnormalities, which can alter the medical results of the fetuses significantly. The incidence of major cardiac defect is 3-12% per 1000 pregnancies in a given population and some minor geographic variations was mentioned in a study conducted by Hernandez Andrade E et

**Table 5:** Echo findings and mean POG

Echo findings	Mean POG at diagnosis(weeks) Mean $\pm$ S.D	POG at Birth(weeks) Mean $\pm$ S.D	Mean birth weight (kg)
With ECA (n= 28)	22.80 $\pm$ 3.11	35.29 $\pm$ 2.87	2.30 $\pm$ 0.16
Without ECA (n=22)	22.71 $\pm$ 3.46	37.14 $\pm$ 3.14	2.65 $\pm$ 0.19
P Value	0.95	0.03*	0.01*

\*Mann Whitney Test, Significant

al.<sup>8</sup> In this study, pregnant women in the age group of 31-35 years were the most common age group with well defined risk factor for fetal echocardiography.

According to the study by Garg S et al., the antenatal mother with an average gestational age that underwent fetal echocardiography was between 20 and 24 weeks.<sup>9</sup> In this study too it was concluded that the mean gestational age of the antenatal mothers was 20-24 weeks for a fetal echocardiography. Study conducted by Ganiga P et al showed the same mean gestational age for fetal echo.<sup>3</sup> In a study conducted by M Wittfoff et al, the fetal echocardiography was done at the mean gestational age of 21 weeks.<sup>10</sup>

In the year 2000 Garne E et al review, evaluated the pre-birth diagnosis of ultrasound congenital heart disease, and recorded that the age of pregnancy when isolated heart defects were identified was around 24 weeks,<sup>2</sup> which was the same as the findings in our research.

During the study conducted by S Ozkutlu et al in 2001, isolated echogenic concentrate was found in 17 cases of the total 1370 cases. It was considered a natural finding and none of them had congenital heart disease or Down's syndrome.<sup>11</sup>

In 2016, a research carried out by K. Nayak et al. reported a low-risk female CHD ratio of approximately 20.3 per 1,000 live-births. 2 antenatal mothers had been diagnosed with congenital heart disease, out of the 180 high-risk cases, by fetal echocardiography, which was significantly lower than that recorded incidence in our study.<sup>12</sup>

In our study, the most common structural defect which was found in 2 fetal echo was a small echogenic focus in left ventricle. And dilated RA and moderate peri membranous VSD with left to right shunt was seen in 1 patient each. Nayak et al conducted a study which stated that the most common structural defect is endocardial cushion defect.<sup>12</sup>

#### 5. Conclusion

A multifactorial and complicated disorder like congenital heart disease has unclear etiology and poor prognosis. When the fetal echocardiography is performed by an experienced cardiologist, it is considered feasible, highly sensitive and specific, especially in high risk antenatal

mothers. Hence from our study, we highly recommend fetal echocardiography as an approach for fetal cardiac assessment, which helps improve obstetric management and antenatal counselling in the presence of abnormalities to ensure optimal neonatal outcome.

## 6. Source of Funding

None.

## 7. Conflict of Interest

None.

## References

- Hoffman JIE, Kaplan S. The incidence of congenital heart disease. *J Am Coll Cardiol.* 2002;39(12):1890–1900.
- Garne E, Stoll C, Clementi M. Evaluation of prenatal diagnosis of congenital heart diseases by ultrasound: experience from 20 European registries. *Ultrasound Obstet Gynecol.* 2001;17(5):386–91.
- Ganiga P, Costa L, Subhash VV, Alva P. A study on foetal echocardiography in high risk antenatal mothers in a tertiary care centre. *Int J Clin Obstet Gynaecol.* 2018;2(3):73–6.
- Carvalho S, Mavrides E, Shinebourne EA, Campbell S, Thilaganathan B. Improving the effectiveness of routine prenatal screening for major congenital heart defects. *Heart.* 2002;88(4):387–91.
- D'apostrophe GR. The aortic and pulmonary outflow tract screening examinations in human fetus. *J Ultrasound Med.* 1992;11(7):345–8.
- Caserta L, Ruggeri Z, D'emidio L, Coco C, Cignini P, Girgenti A. Two-dimensional fetal echocardiography: where we are. *J Prenat Med.* 2008;2(3):31–5.
- Rychik J, Ayres N, Cuneo B, Gotteiner N, Hornberger L, Spevak PJ, et al. American Society of Echocardiography guidelines and standards for performance of the fetal echocardiogram. *J Am Soc Echocardiogr.* 2004;17:803–10.
- Hernandez-Andrade E, Patwardhan M, Cruz-Lemini M, Luewan S. Early Evaluation of the Fetal Heart. *Fetal Diagn Ther.* 2017;42(3):161–73.
- Garg S, Sharma P, Sharma D, Behera V, Durairaj M, Dhall A. Use of Fetal Echocardiography for Characterization of Fetal Cardiac Structure in Women With Normal Pregnancies and Gestational Diabetes Mellitus. *J Ultrasound Med.* 2014;33(8):1365–9.
- Meyer-Wittkopf M, Cooper S, Sholler G. Correlation between fetal cardiac diagnosis by obstetric and pediatric cardiologist sonographers and comparison with postnatal findings. *Ultrasound Obstet Gynecol.* 2001;17(5):392–7.
- Ozkutlu S, Akca T, Kafali G, Beksac S. The results of fetal echocardiography in a tertiary center and comparison of low- and high-risk pregnancies for fetal congenital heart defects. *Anatol J Cardiol.* 2010;10(3):263–9.
- Nayak K, Chandra G, Shetty R, Narayan PK. Evaluation of fetal echocardiography as a routine antenatal screening tool for detection of congenital heart disease. *Cardiovasc Diagn and Ther.* 2016;6(1):44–53.

## Author biography

Swastika Gojnur Final Year Postgraduate

Annie Rajaratnam Associate Professor

**Cite this article:** Gojnur S, Rajaratnam A. Fetal echocardiography and its role in high risk antenatal mothers. *Indian J Obstet Gynecol Res* 2020;7(2):222-225.