

Frequency and histological spectrum of gallbladder carcinoma- a tertiary teaching hospital based study on 2858 cholecystectomy specimens in western Uttar Pradesh, India

Alok Mohan¹, R.K Thakral^{2*}, Amir Faiz³, Rajnish Kumar⁴

^{1,4}Associate Professor, ²Professor, ³Tutor, Dept. of Pathology, Muzaffarnagar Medical College, Muzaffarnagar, Uttar Pradesh, India

***Corresponding Author:**

Email: drrajender182001@gmail.com

Abstract

Introduction: Gallbladder carcinoma (GBC) is the most common malignancy of biliary tract. It is associated with shortest median survival due to late diagnosis. Its clinical features are often mimicked by features of benign or inflammatory disease.

Aim: The aim of the present study was to find out incidence of GBC in submitted cholecystectomy specimen and study its histological types at a tertiary teaching hospital in western Uttar Pradesh.

Materials and Methods: It was a hospital based retro-prospective study on cholecystectomy specimens from June 2008–May 2018.

Observations: Out of 2858 cases, 45 cases were malignant. M: F ratio was 1:3.5. Mean age was 51.38 years. Most cases were of adenocarcinoma- conventional type (75.57%).

Conclusion: The present study came to the conclusion that GBC is more common in females. The age group is variable but it is in the middle age. Adenocarcinoma is the most common histologic subtype. Chronic cholelithiasis is a major risk factor. Timely surgery is the only available treatment.

Keywords: Adenocarcinoma, Carcinoma, Cholecystectomy, Gallbladder, Malignancy.

Introduction

Gall bladder carcinoma (GBC) is the most common malignant neoplasm of the biliary tract throughout the world.¹ It is the carcinoma of the biliary tract with most aggressive behavior. Moreover it has the shortest median survival duration from the time of diagnosis.²

Long standing chronic inflammatory reaction by gallstones is considered to be an important etiological role in carcinogenesis.³ Other predisposing factors are tobacco consumption, inhabitants of Gangetic belt, increased secondary bile acids, fried foods with reused oil etc. increases the GBC risk.⁴

The poor prognosis is due to an aggressive biologic behavior along with a lack of early detection techniques resulting in delayed diagnosis and surgical treatment.⁵

Even after surgical resection, the complex anatomy of the portobiliary hepatic system, resection of liver segments and the spread due to tumour manipulation render a high mortality rate.⁶

Unfortunately, even after surgical resection, the recurrence rates are high.²

Incidental carcinomas are also encountered during routine histopathology of gallbladder after elective cholecystectomy for gallstones. Thus, histopathological analysis is mandatory for diagnosis of early carcinomas.³

Most common histopathologic type is adenocarcinoma, which accounts for 98% of all gallbladder cancers. The remaining common histological types are papillary, mucinous, squamous, and adenosquamous. Uncommon types of gallbladder cancer include carcinosarcoma, small cell carcinoma,

lymphoma, signet ring cell type, neuroendocrine tumours. Tumours may contain multiple histological variants.^{7,8}

Aims

The aim of the present study was to study the histopathological spectrum of cases of carcinoma gallbladder in our archived cases.

Materials and Methods

The material for the present study was collected from the department of Pathology, in a tertiary teaching hospital in Western Uttar Pradesh. Approval of the institutional ethical committee was taken. The study design was retro prospective in nature.

The study included gallbladder cases for ten years i.e. from June 2008–May 2018.

Retrospective cases included were from June 2008 to May 2017. Prospective cases were from June 2017 to May 2018. In the retrospective study all the relevant material like blocks and slides of carcinoma gallbladder, available in Pathology department, were studied.

In the prospective cases, we studied all the relevant new excised gallbladder tissues from the Department of Surgery, which were submitted for histopathological examination. After proper processing, blocks were made, cut into sections and stained with Haematoxylin and Eosin. Special stains were also applied wherever required.

Observations

In this study, we studied a total of 2858 cases of cholecystectomy specimens received by the Department of Pathology during last ten years.

In retrospective study, we studied 2223 cases and in prospective study 635 cases were studied. There we observed a clear female preponderance (n=2329; 81.49%), while male cases were 529 (18.51%).

Out of 2858 cases, only 45 cases were malignant in nature (1.57%), rest 2813 cases were non malignant (98.42%).

In malignant cases, 35 cases were female (77.78%), while 10 cases were male (22.22%). Male to female ratio was 1:3.5. Mean age in malignant lesions was 51.38 years. Cases were distributed from 19 years of age to 85 years of age.

Thirty seven out of 45 cases had stones (82.22%). Twenty eight cases had multiple stones (73.53%) while 09 cases (21.43%) had single stone.

Histopathological typing of the gallbladder carcinoma was done. (Image 1; Table 1)

Adenocarcinoma emerged out to be the group with maximum number of cases, which were further classified into well differentiated type, moderately differentiated type and poorly differentiated type. (Table 2)

Lymphovascular invasion was seen in 21 cases, while neural invasion was seen in 08 cases of adenocarcinoma.

Thirty eight cases, i.e.1.33% of total cholecystectomy specimens and 84.44% of total diagnosed GBC were incidentally detected and diagnosed as malignancy during histopathological examination. Cholecystectomy was done in these cases for some pathology presumed to be benign.

Table 1: Distribution of gallbladder carcinoma cases according to histological types

Histological typing of carcinoma gallbladder	Number of cases	Percentage
Adenocarcinoma –conventional type	34	75.57%
Papillary adenocarcinoma	03	6.67%
Mucinous adenocarcinoma	02	4.44%
Adenosquamous carcinoma	02	4.44%
Neuroendocrine carcinoma	02	4.44%
Small cell carcinoma	01	2.22%
Undifferentiated type	01	2.22%
Total Cases	45	100%

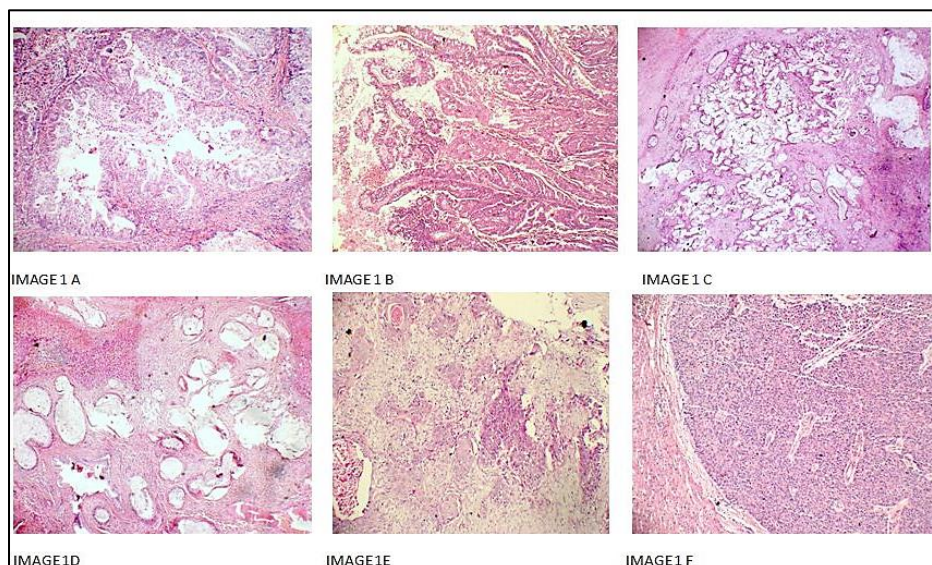


Image 1

Table 2: Distribution of adenocarcinoma cases according to degree of differentiation

Adenocarcinoma cases (N=34)	Number of cases	Percentage
Well differentiated cases	12	35.29%
Moderately differentiated cases	16	47.06%
Poorly differentiated cases	06	17.65%
Total Cases	34	100%

Discussion

Carcinoma gallbladder has variable prevalence in different parts of the world. Percentage of malignant lesions, out of cholecystectomies performed, varies from region to region.⁹

In the present study only 45 cases were found to be malignant out of 2858 cases. This means that 1.57% cases of all the cholecystectomy specimens received for histopathology in the department of Pathology in our institute, during the last ten years of duration, were malignant in nature.

Sharma et al¹⁰ diagnosed GBC in 1.9% cases which were comparable to our results.

A study by Mondal et al¹¹ showed incidence of 0.6% of GBC.

A study from SGPGI, Lucknow¹² reported 358 cases with carcinoma gall bladder out of 2600 cholecystectomies performed during the 11 year period (13.77%), which was higher than our results.

Worldwide GBC affects females two to six times more commonly than males.^{4,8,13} This association in developing countries has also been thought to be affected by cycling of cholesterol, female hormones, higher gravidity and parity, and infections of *Salmonella* species.^{14,15} In the present study, male to female ratio was 1:35 which is well in concordance to results by Giang et al (M:F 1:4.5) and Derkyi – Kwarteng et al (M:F 1:4.3).^{7,16}

In the present study the mean age of cases with GBC is 51.38 years. Mondal et al in their study found mean age of GBC to be 53 years.¹¹ Yadav et al found mean age of GBC patients in their study to be 45 years.¹⁷ These studies are in concordance to our study. There are many other studies which showed the mean age around 60 years of age.^{16,18} In the present study 37 out of 45 cases (82.22 %) were associated with the gallstones. As per study by Kimura et al, gallstones were found in over 80% of patients with gallbladder carcinoma.¹⁹

In the present study conventional adenocarcinoma is the commonest histopathologic type i.e. 75.57%. As per the medical literature well to moderately differentiated adenocarcinomas are the most common malignant epithelial tumours of the gallbladder. They are composed of short or long tubular glands lined by cells that vary in height from low cuboidal to tall columnar. The tumour cells may be arranged in sheets, cords, glands, or in a cribriform pattern. Derkyi-Kwarteng et al found adenocarcinoma in 75% of cases.¹⁶ Yadav et al founded 72.8% cases of adenocarcinoma NOS.¹⁷

Papillary adenocarcinomas comprised of 6.67% cases of GBC in the present study. Kanthan et al found that nearly 5% of cases are of papillary carcinoma.¹⁸ Papillary adenocarcinoma is a well differentiated neoplasm in which tumour cells proliferate on fibrovascular stalks. The neoplastic cells fill the lumen of gallbladder earlier then invade the wall in later

stages. Thus, papillary carcinomas have a better prognosis.²⁰ Intracholecystic papillary-tubular neoplasms (ICPNs) is the term used for non-invasive papillary neoplasms. Dysplasia, low-grade or high-grade, is often present and these lesions may give rise to invasive GBC.²¹

In our study we found 02 cases of mucinous adenocarcinoma type i.e. 4.44% but frequency varies from 2.5% to 4% as per various studies.^{7,18} Mucinous adenocarcinomas have more than 50% extracellular mucin. Signet ring cells and clusters of malignant cells are also present floating within the pool of mucin. These tumors present at late stages and have poor prognosis.^{22,23}

In the present study we had a single case of adenosquamous carcinoma (4.44%). In our case 50% of the tumor area was squamous type. Adenosquamous carcinomas comprises of both malignant glandular and squamous components. Squamous component must be 25%-99% of the tumour. Literature mentions incidence of squamous/ adenosquamous carcinoma from 1.4-12.7%.^{24,25}

In the present study we studied 4.44 % cases of neuro endocrine tumours. Neuroendocrine tumours of the gallbladder comprise of nearly 2% of gallbladder cancers. Nearly all have been reported to be co-existent with chronic cholecystitis and cholelithiasis. Rarely, the cases (<01%) present with features of carcinoid syndrome.²⁶

Small cell carcinoma of gallbladder is a rare entity (<0.5%). In our study we encountered a single case of small cell carcinoma. Small cell carcinomas are common in elderly females with chronic cholecystitis and cholelithiasis. These findings are in concordance with our findings. In our case the female patient was of 85 years with history of chronic cholecystitis and cholelithiasis.²⁷

A single case (2.22%) of undifferentiated carcinoma was also studied. Derkyi-Kwarteng et al encountered 02 cases of undifferentiated carcinoma in their study.¹⁶ Yadav et al found 5.5% cases of undifferentiated carcinoma.¹⁷

In the present study 38 cases (1.33%) were incidentally detected. These findings were concordant with other studies. Samad et al²⁸ reported incidental carcinoma in 1.1% cases of all cholecystectomies. Siddiqui et al noticed 06 cases (2.7% of all cholecystectomies) of incidental carcinomas.²⁹ Kanthal et al¹⁸ in their review article has mentioned an incidence of incidental carcinoma varying from 0.2-3%.

Conclusion

Gallbladder cancer is associated with high mortality. Its incidence is variable in different parts of India and worldwide. The present study came to the conclusion that this carcinoma is more common in females. The age group is variable but it is in the middle age. Adenocarcinoma is the most common

histologic subtype. Early diagnostic techniques are missing. Chronic cholelithiasis is a major risk factor. Timely surgery is the only available treatment.

References

- Lai C.H.E, Lau W.Y. Gallbladder cancer-a comprehensive review. *Surgeon*. 2008;6:101-10.
- Zhu A.X, Hong T.S, Hezel, A.F, Kooby D.A. Current management of gallbladder carcinoma. *The oncologist*. 2010;15:168-81.
- Inui K, Yoshino J, Miyoshi H. Diagnosis of gallbladder tumors. *Intern Med*. 2011;50:1133-1136.
- Sharma A, Sharma KL, Gupta A, Yadav A, Kumar A. Gallbladder cancer epidemiology, pathogenesis and molecular genetics: Recent update. *World J Gastroenterol*. 2017;23:3978-3998.
- Dutta U. Gallbladder cancer: can newer insights improve the outcome? *Journal of Gastroenterology and Hepatology*. 2012;27:642-53.
- Ramos -Font C, Gomez-Rio M, Rodriguez-Fernandez A, Jimenez-Heffernan, Sanchez R.S, Llamas -Elvira J.M. Ability of FDG-PET/CT in the detection of gallbladder cancer. *Journal of Surgical Oncology*. 2014;109:218-24.
- Giang T.H, Ngoc T.T.B, Hassell L.A. Carcinoma involving the gallbladder: a retrospective review of 23 cases- pitfalls in diagnosis of gall bladder carcinoma. *Diagnostic Pathology*. 2012;7:10.
- Hundal R, Shaffer E.A. Gallbladder cancer: epidemiology and outcome. *Clinical Epidemiology*. 2014;6:99-109.
- Randi G, Franceschi S, La Vecchia C. Gallbladder cancer worldwide: Geographical distribution and risk factors. *Int J Cancer*. 2006;118:1591-602.
- Sharma JD, Kalita I, Das T, Goswami P, Krishnatreya M. A retrospective study of post-operative gall bladder pathology with special reference to incidental carcinoma of the gall bladder. *Int J Med Sci*. 2014;2:1050-3.
- Mondal B, Maulik D, Biswas BK, Sarkar GN, Ghosh D. Histopathological spectrum of gallstone disease from cholecystectomy specimen in rural areas of West Bengal, India-an approach of association between gallstone disease and gallbladder carcinoma. *Int J Community Med Public Health*. 2016;3:3229-35.
- Kapoor VK. Incidental gall bladder carcinoma. *Am J Gastroenterol*. 2001;3:627-9.
- Lazcano-Ponce EC, Miquel JF, Munoz N et al. Epidemiology and molecular pathology of gallbladder cancer. *CA Cancer J Clin*. 2001;51:349-64.
- Pilgrim CH, Groeschl RT, Christians KK, Gamblin TC. Modern perspectives on factors predisposing to the development of gallbladder cancer. *HPB (Oxford)*. 2013;15:839-844.
- Iyer P, Barreto SG, Sahoo B, Chandrani P, Ramadwar MR, Shrikhande SV, Dutt A. Non- typhoidal Salmonella DNA traces in gall bladder cancer. *Infect Agent Cancer*. 2016;11:12.
- Derkyi-Kwarteng L, Brown AA, Akakpo KP, Addae E, Amoah D, Diabor E, Quayson SE. Gallbladder carcinoma in Ghana: Histopathological examination of cholecystectomy specimen. *Journal of Cancer and Tumor International*. 2016;3:1-4.
- Yadav R, Jain D, Mathur SR, Sharma A, Iyer VK. Gallbladder carcinoma: An attempt of WHO histological classification on fine needle aspiration material. *Cytojournal*. 2013;10:12.
- Kanthan R, Senger JL, Ahmed S, Kanthan SC. Gallbladder cancer in the 21st century. *Journal of Oncology*. 2015;2015:1-26.
- Kimura W, Shimada h, Kuroda A et al. Carcinoma of the gallbladder and extrahepatic bile ducts in autopsy cases of the aged, with special reference to its relationship to gallstones. *Am J gastroenterol*. 1989;84:386-390.
- Albores-Saavedra J, Henson DE, Klimstra DS. Tumors of the gallbladder, extrahepatic bile ducts and ampulla of Vater. *Armed force Institute of Pathology, Washington*. DC 2000; p61-104.
- Adasy V, Jang KT, Roa JC, et al. Intracholecystic papillary- tubular neoplasm(ICPN) of the gallbladder (neoplastic polyps, adenomas and papillary neoplasms that are >1.0cm). *Am J Surg Pathol*. 2012;36:1279-1301.
- Bal MM, Ramadwar M, Deodhar K, Shri Khande S. Pathology of gallbladder carcinoma : current understanding and new perceptive. *Pathol Oncol Res*. 2015;21:509-525.
- Dursun N, Escalona OT, Roa JC, et al. Mucinous carcinomas of gallbladder: clinicopathological analysis of 15 cases. *Mod pathol*. 2012;136:1347-1358.
- Roa JC, Tapia O, Cakir A, et al. Squamous cell and adenosquamous carcinomas of the gallbladder: clinicopathological analysis of 34 cases. *Mod Pathol*. 2011;24:109-1078.
- Kim MJ, Kim KW, Kim HC et al. Unusual malignant tumors of the gallbladder. *Am J of Roentgenology*. 2006;187:473-480.
- Iype S, Mirza TA, Proppper DJ, Bhattacharya S, Feakins RM, Kocher HM. Neuroendocrine tumours of the gallbladder: three cases and a review of the literature. *Postgraduate Medical Journal*. 2009;85:213-218.
- Kim D-M, Yang S-O, Han HY, Kim KS, Son HJ. Small cell carcinoma of the gallbladder: 18F-FDG PET/CT imaging features— a case report. *Nuclear Medicine and Molecular Imaging*. 2010;44:213-216.
- Samad A. Gallbladder carcinoma in patients undergoing cholecystectomy for cholelithiasis. *J Pak Med Assoc*. 2005;55:497-499.
- Siddiqui FG, Menon AA, Abro AH, Sasoli NA, Ahmad L. Routine histopathology of gallbladder after elective cholecystectomy for gallstones: waste of resources or a justified act? *NMC Surgery*. 2013;13:26.

How to cite this article: Mohan A, Thakral RK, Faiz A, Kumar R. Frequency and histological spectrum of gallbladder carcinoma- a tertiary teaching hospital based study on 2858 cholecystectomy specimens in western Uttar Pradesh, India. *J Diagn Pathol Oncol*. 2018;4(3):192-195.